
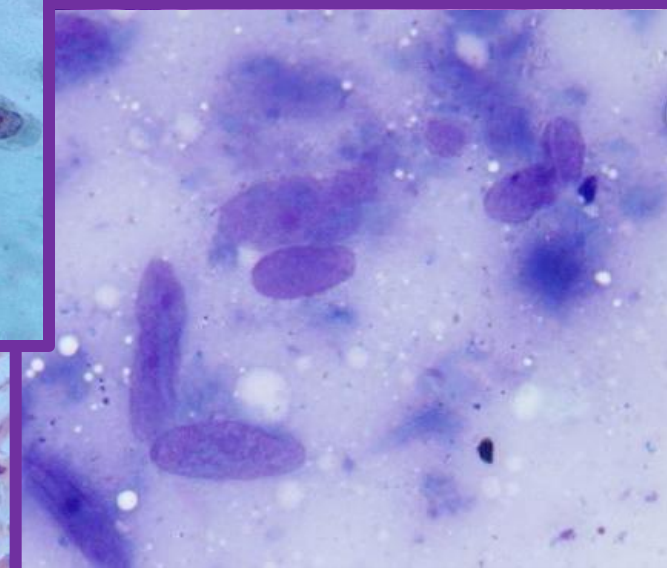
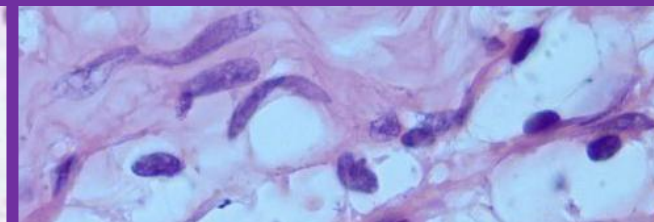
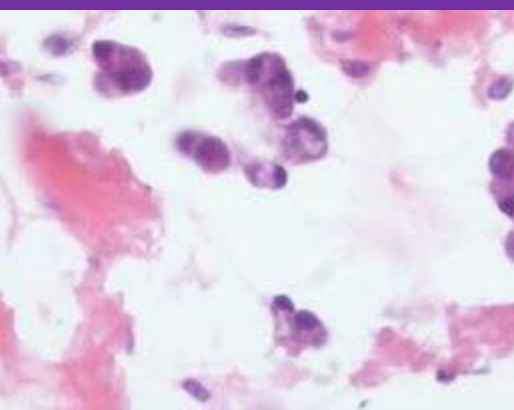
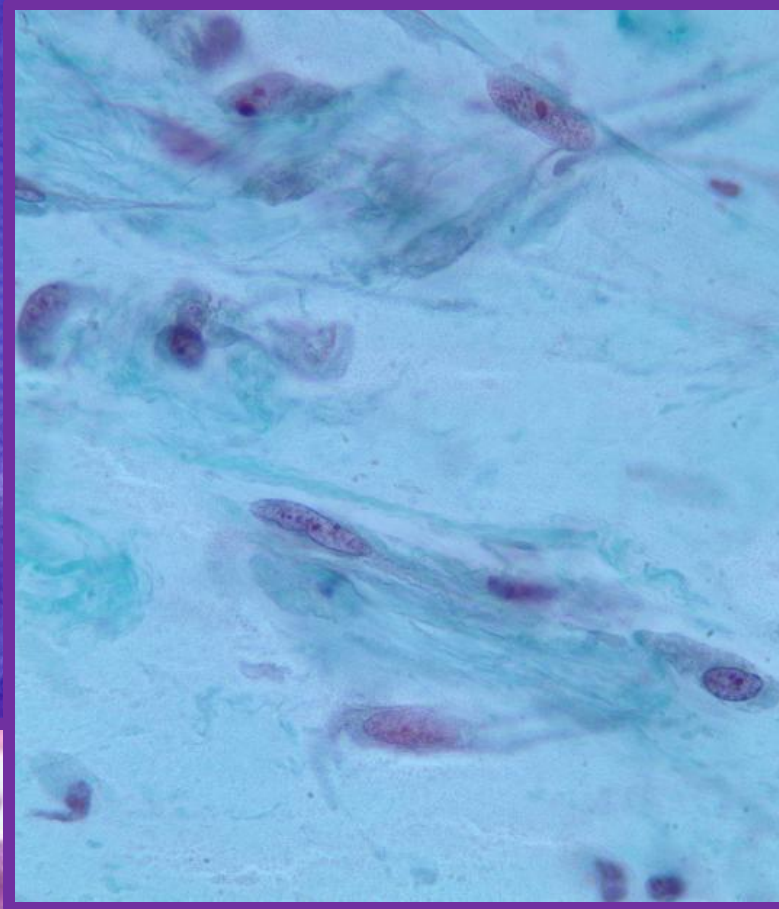
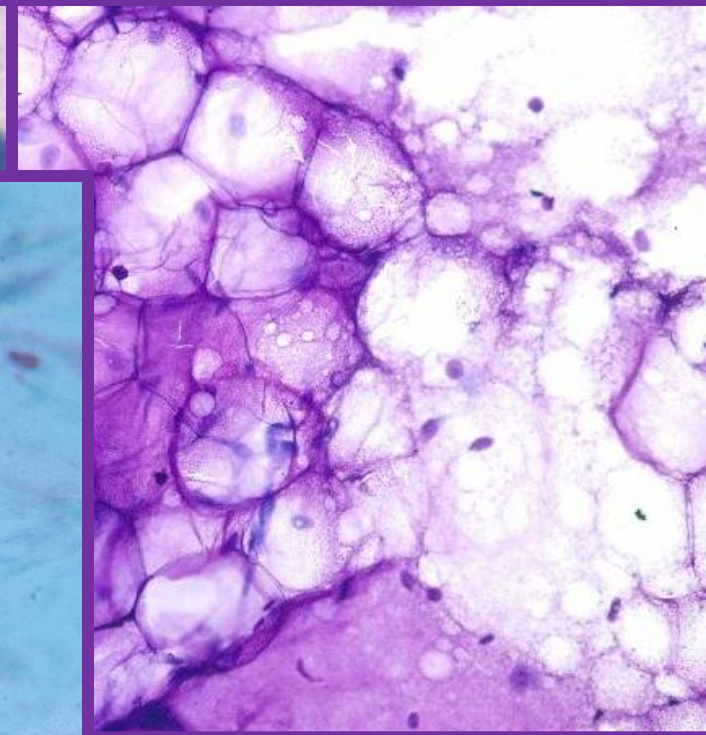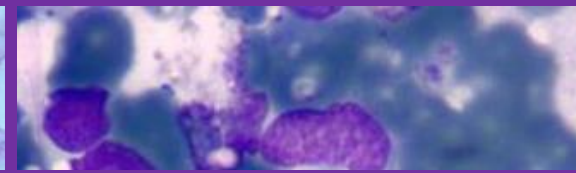
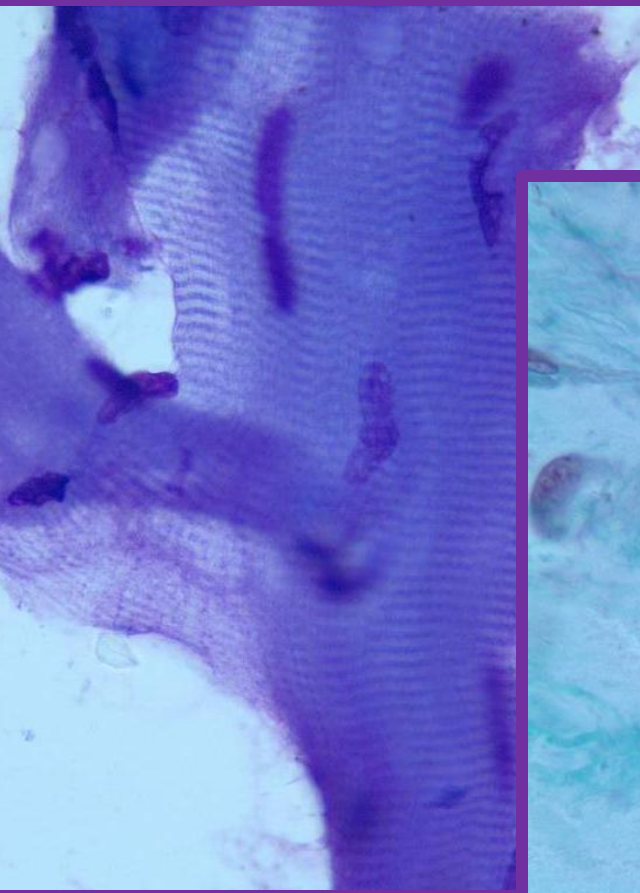


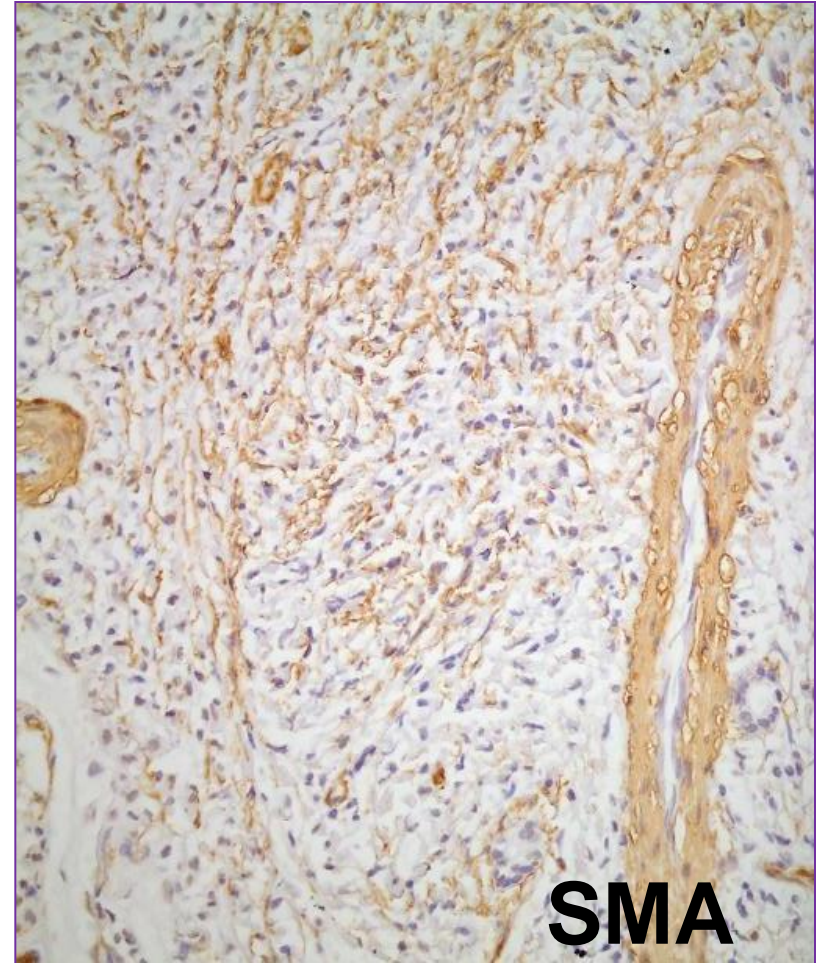
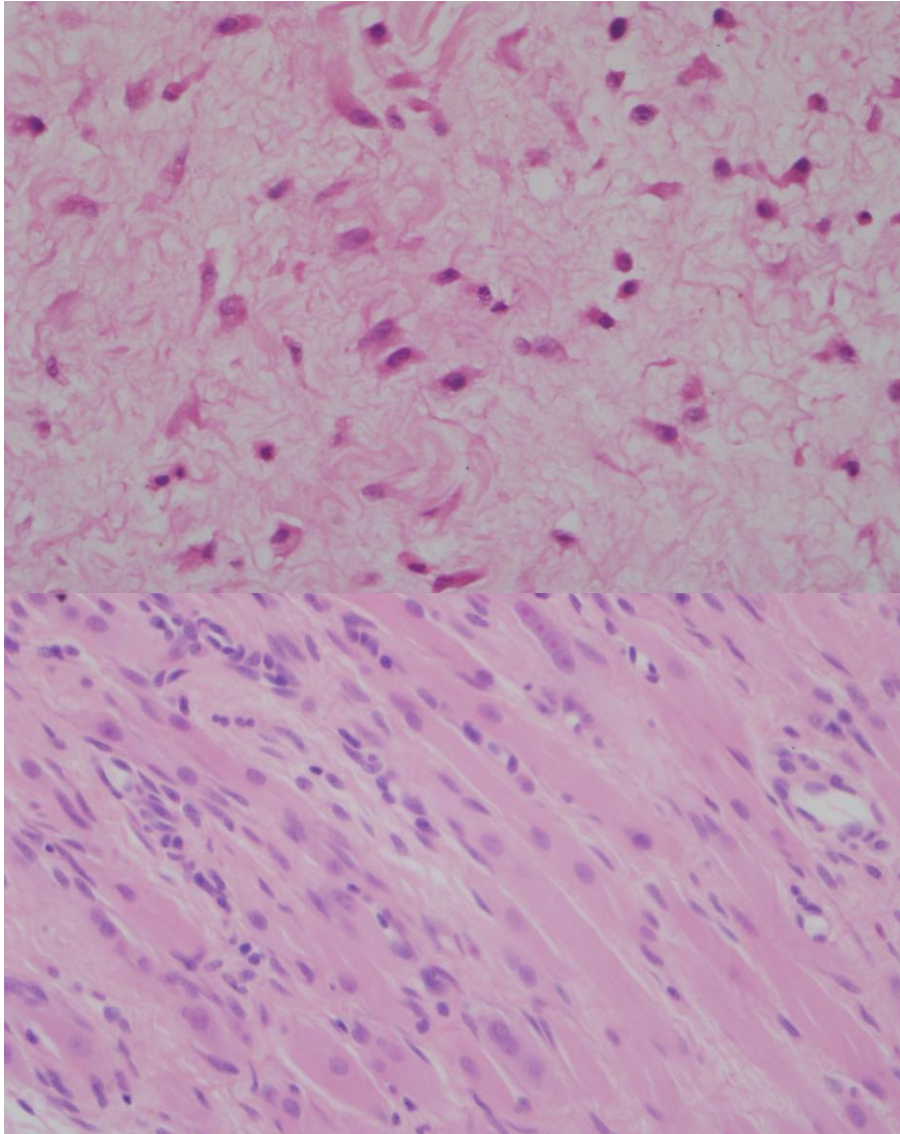
Fibroblastik/Myofibroblastik Tümörler

Dr. Kemal Kösemehmetođlu





Myofibroblast



World Health Organization Classification of Tumours

WHO



OMS

International Agency for Research on Cancer (IARC)

Pathology and Genetics of Tumours of Soft Tissue and Bone

1. Adipositik
2. Fibroblastik/myofibroblastik
3. (Güya) Fibrohistiyositik
4. Düz kas
5. Perisitik (perivasküler)
6. Çizgili kas
7. Vasküler
8. Kondroosseöz
9. Belirsiz kökenli



Malign


**İntermediate
(nadir metastaz)**

**İntermediate
(lokal agresiv)**

Benign

Fibroblastik/myofibroblastik Lezyonlar

- **İğsi hücreli**
- Mikzoid
- Pleomorfik
- Yuvarlak hücreli
- Epitelioid (poligonal)



Fibroblastik/Myofibroblastik Lezyonlar

Weiss&Enzinger'in 4 kategorisi

- 1) **Reaktif lezyonlar (psödosarkomlar)**
- 2) **Fibromatozlar**
- 3) **Düşük/yüksek dereceli fibroblastik/myofibroblastik sarkomlar**
- 4) **Yenidoğan ve çocukluğun fibroblastik/myofibroblastik proliferasyonları**

Fibroblastik/myofibroblastik yumuşak doku tümörleri

Benign

- Nodular fasiit
- Proliferatif fasiit
- Proliferatif myosit
- İskemik fasiit (atipik deküital fibroplazi)
- Myositis ossificans/parmakların fibroosseöz psödotumörü
- Elastofibrom
- Tendon kılıfının fibromu
- Dezmoplastik fibroblastom (kollajenöz fibrom)
- Meme-tipi fibroblastom
- Anjiyofibroblastom
- Sellüler anjiyofibrom
- Nazofaringial anjiyofibrom
- Nuchal-tip fibrom
- Gardner fibromu
- Kalsifiye fibröz psödotümör
- Dev hücreli anjiyofibrom
- Derinin pleomorfik fibromu
- Soliter fibröz tümör

Fibromatozisler

- Yüzeyel fibromatozis
- Dezmoid fibromatozis

Sarkomlar

- Düşük dereceli myofibroblastik sarkom
- Mikzoinflamatuar fibroblastik sarkom (inflammatuar mikzohyalen tümör)
- Erişkin fibrosarkom
- Mikzofibrosarkom
- Düşük dereceli fibromikzoid sarkom (ve hyalinize dev rozetli iğsi hücreli tümör)
- Sklerozan epitelioid fibrosarkom

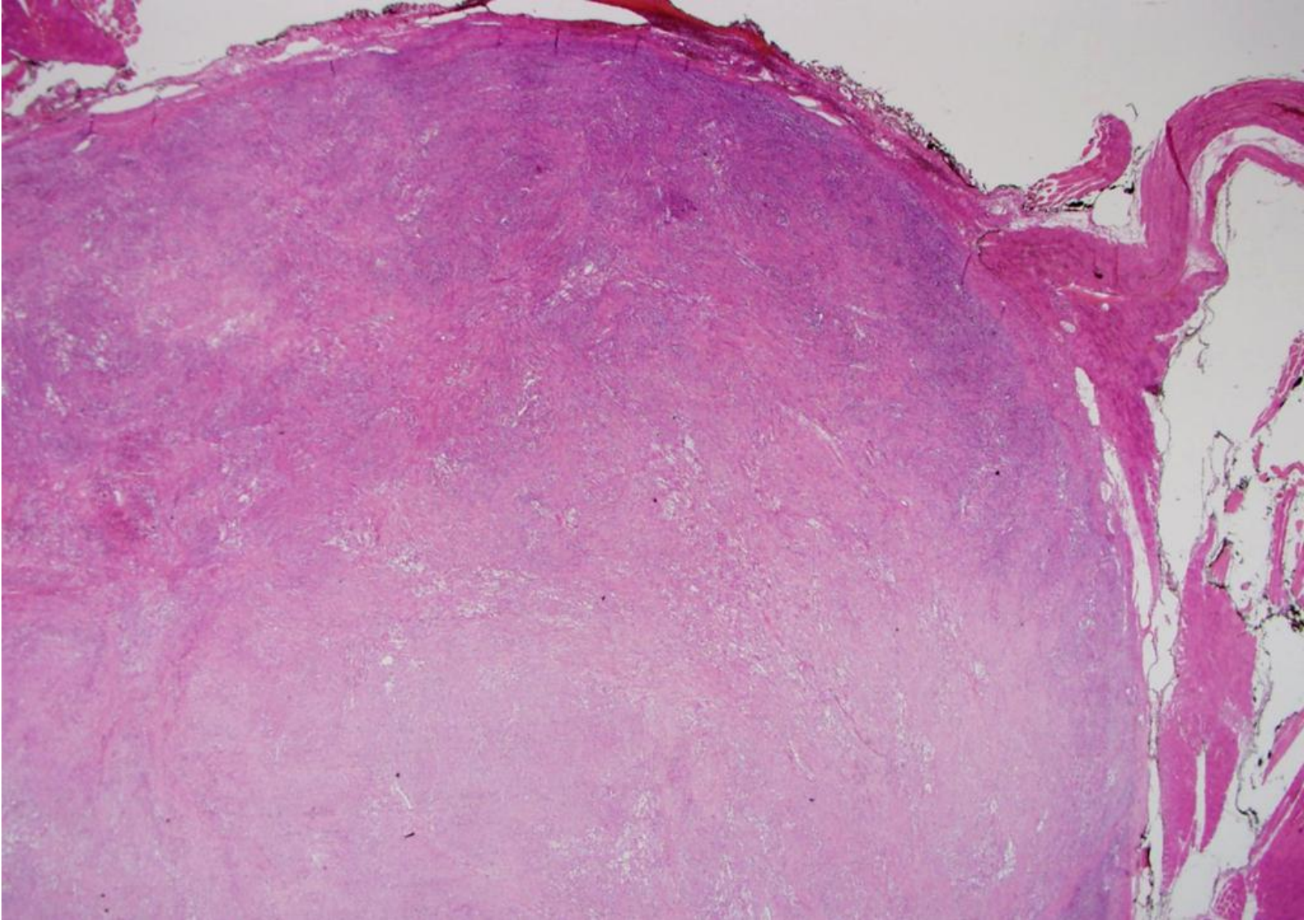
Yenidoğan ve çocukluğun fibroblastik/myofibroblastik proliferasyonları

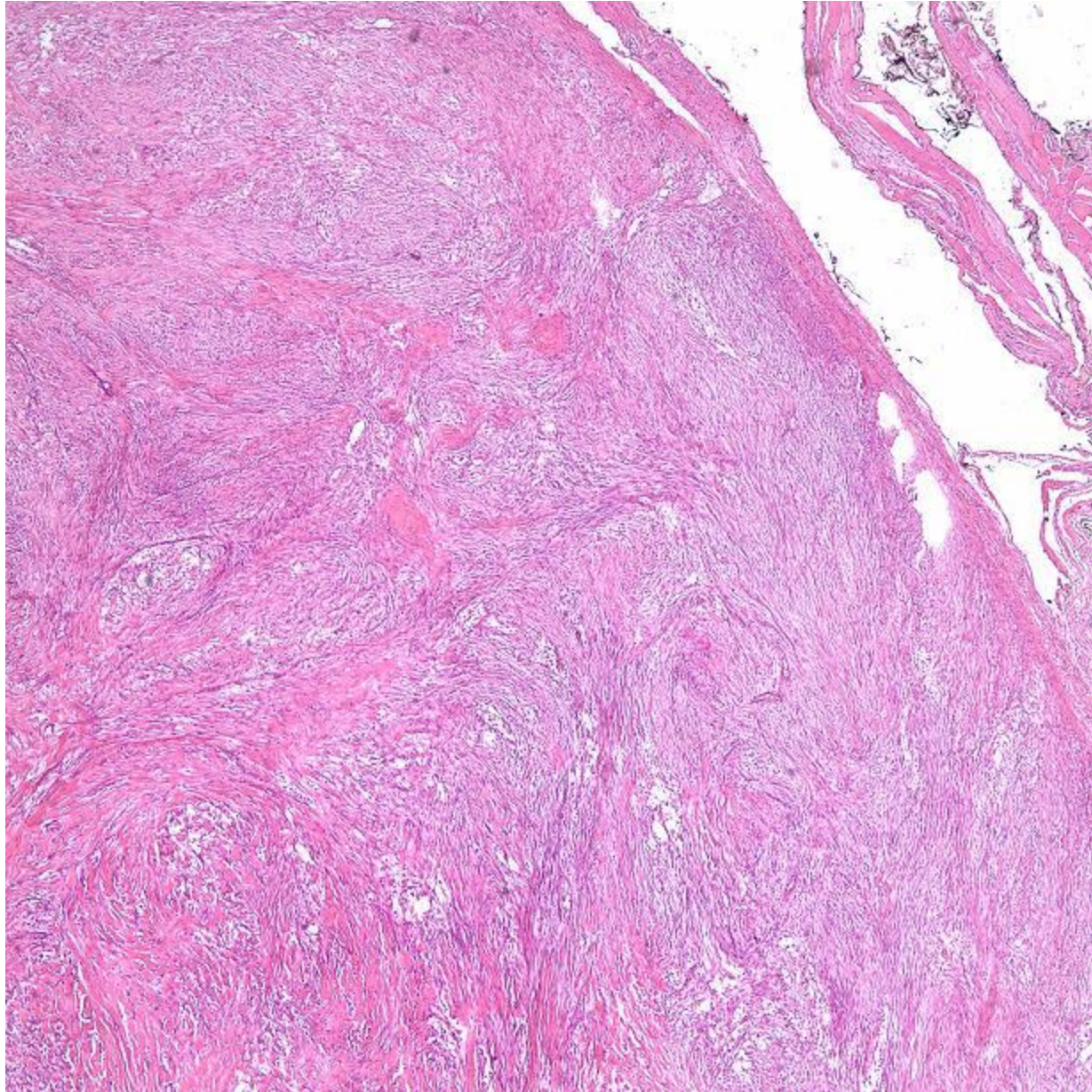
- Yenidoğanın fibröz hamartomu
- Myofibrom/myofibromatozis
- Fibromatozis colli
- Juvenile hyalin fibromatozis
- İnklüzyon cismi (parmak) fibromatozu
- Kalsifiye aponörotik fibrom
- Lipofibromatozis
- İnflamatuar myofibroblastik tümör
- İnfanıl fibrosarkom

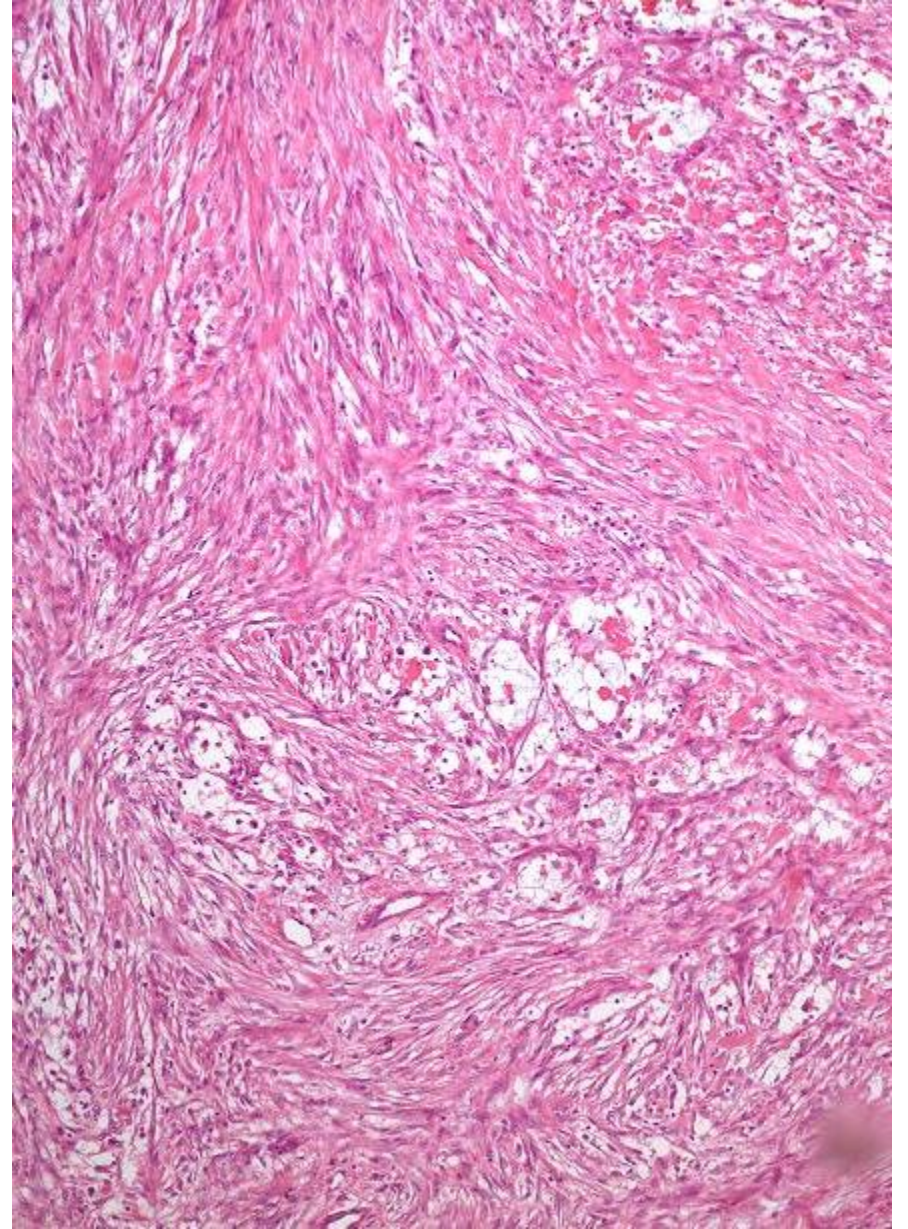
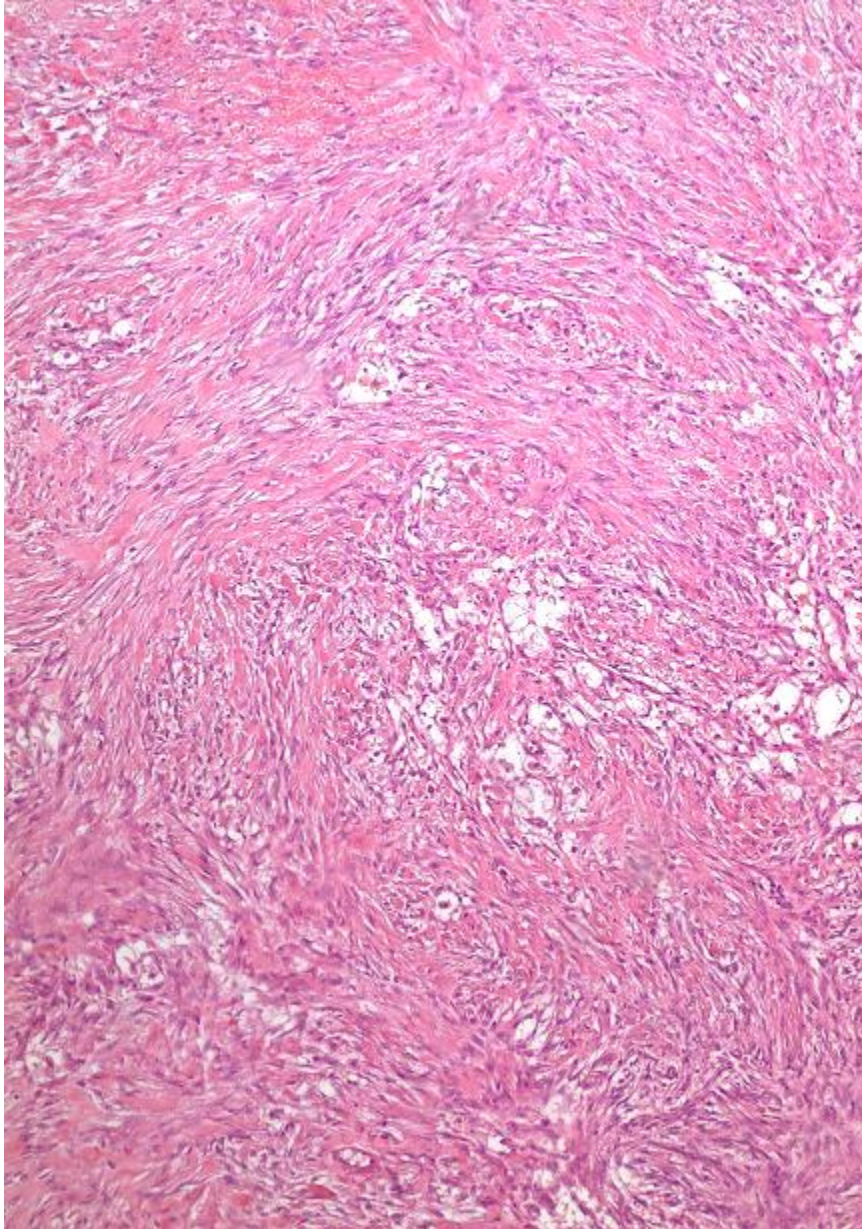
Olgu 1

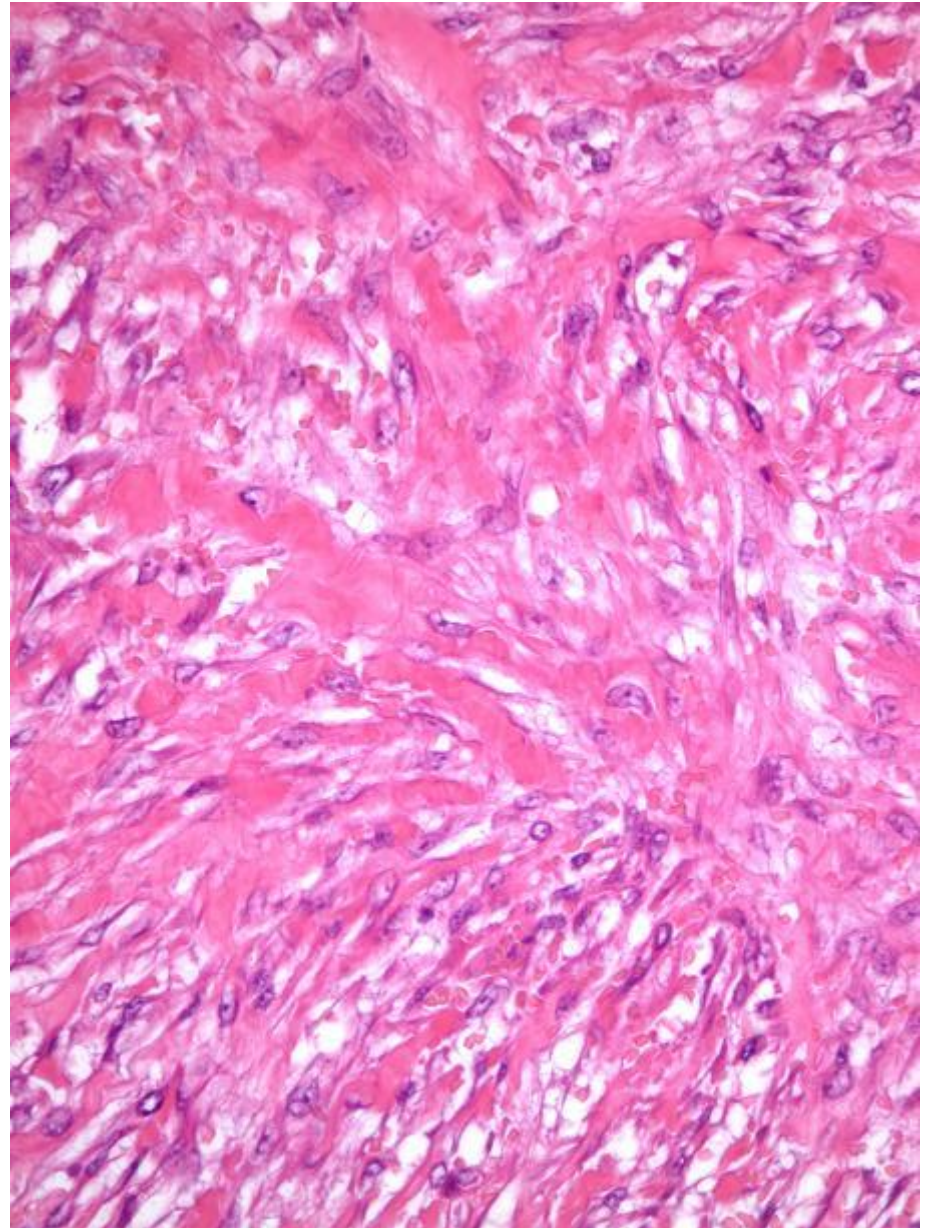
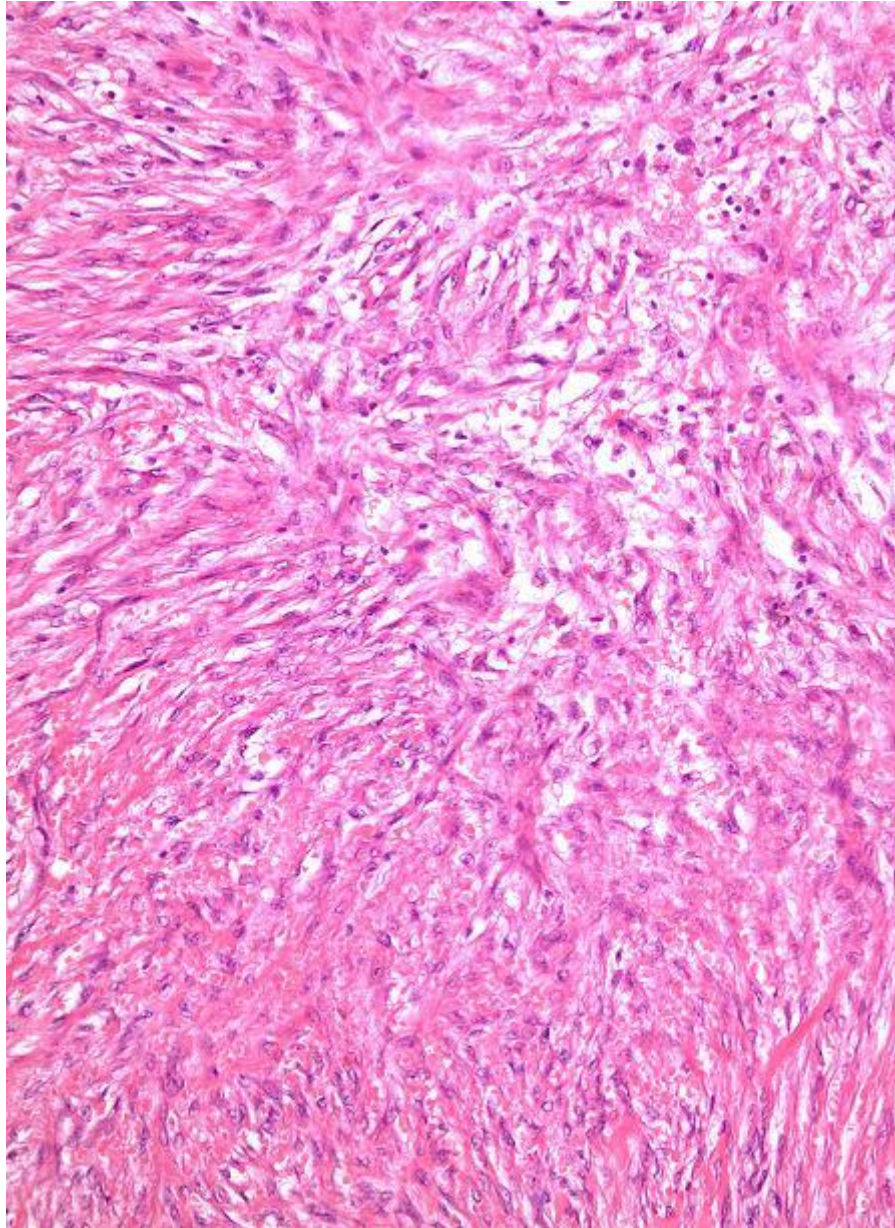
33 y ♂

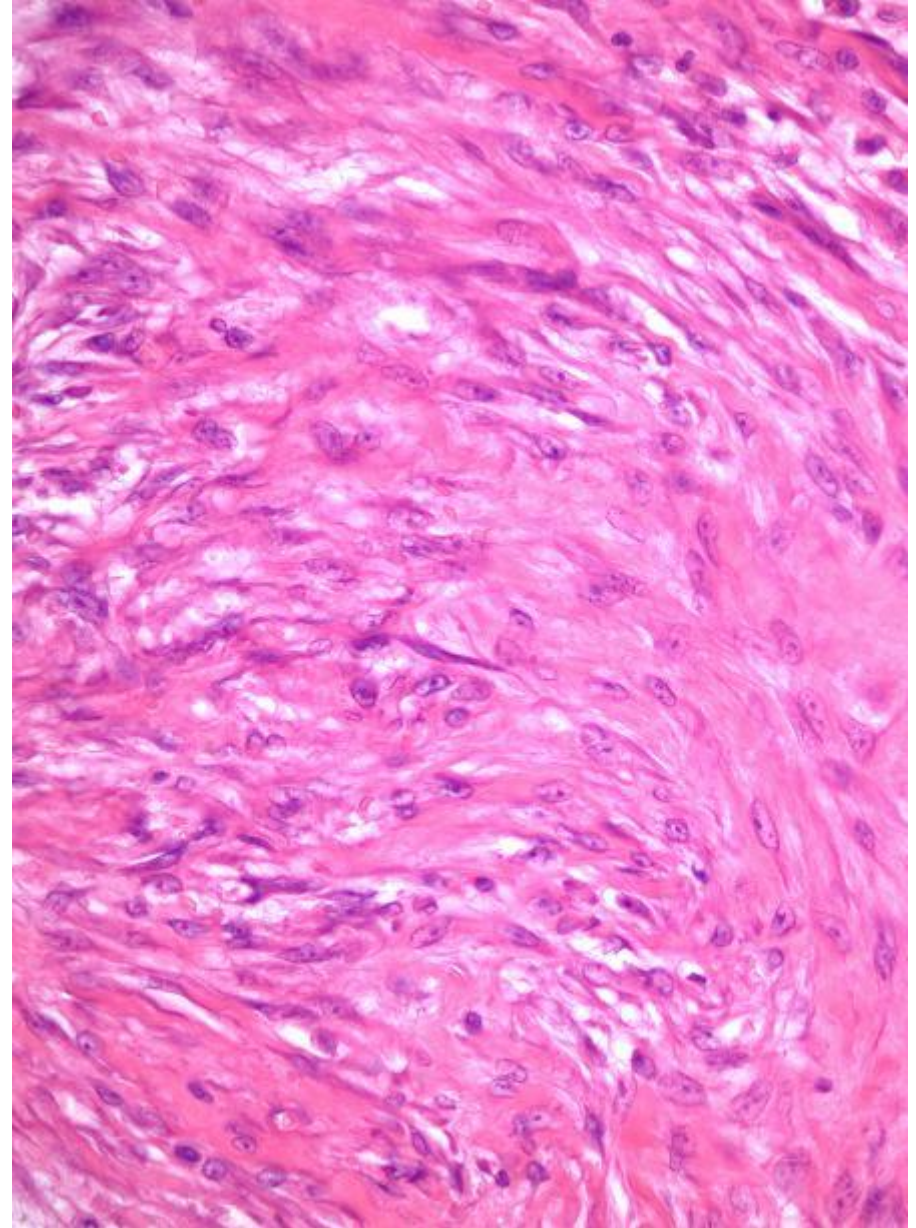
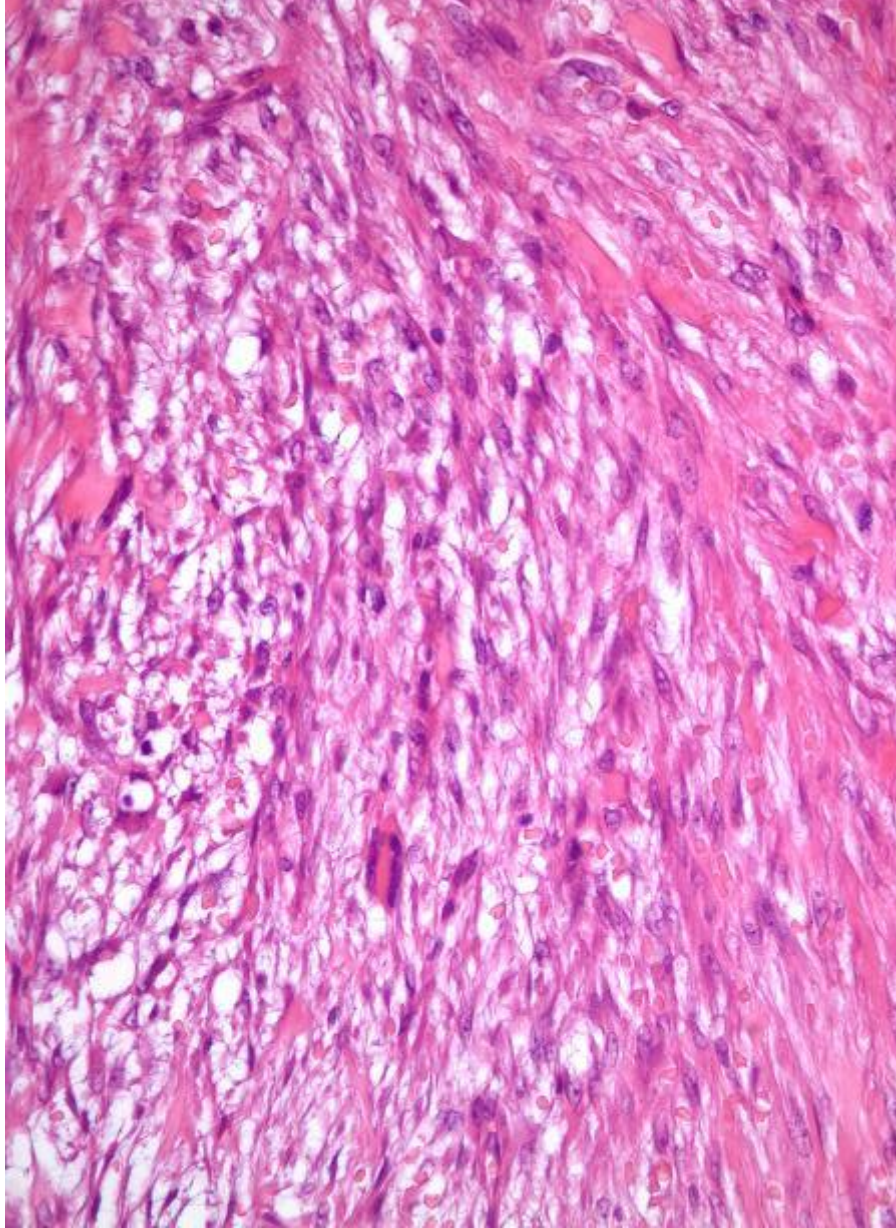
1 aydır sol triseps kası içinde kitle

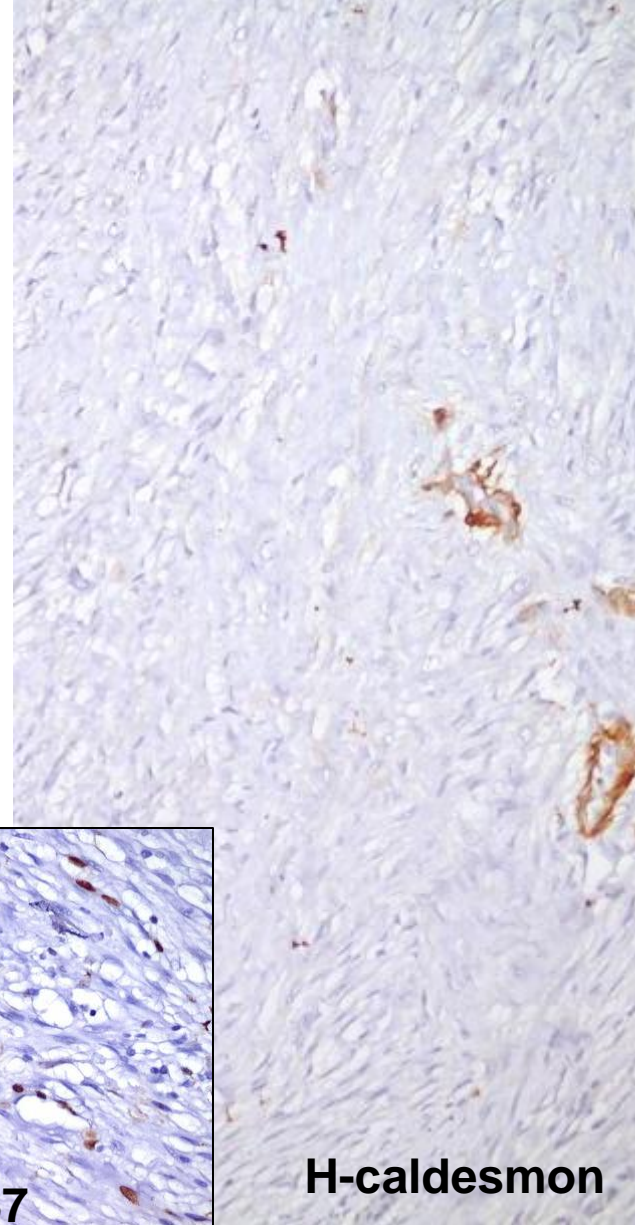
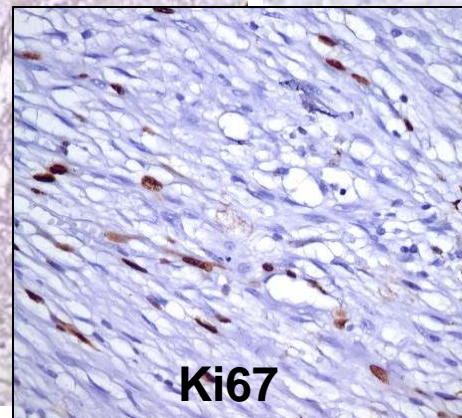
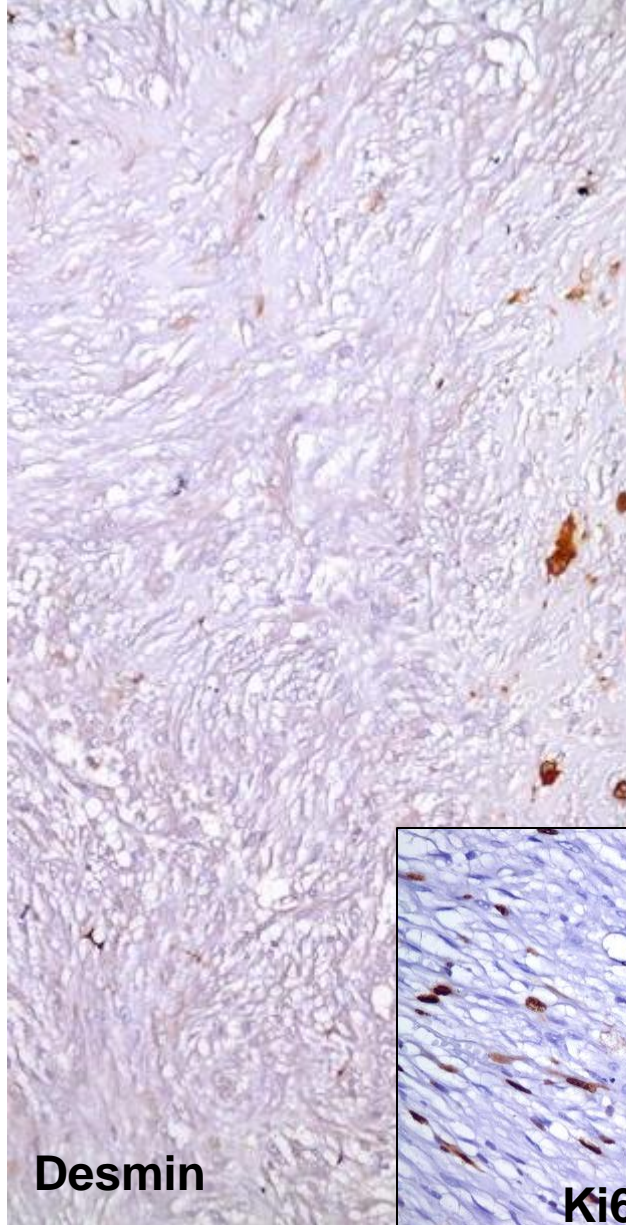
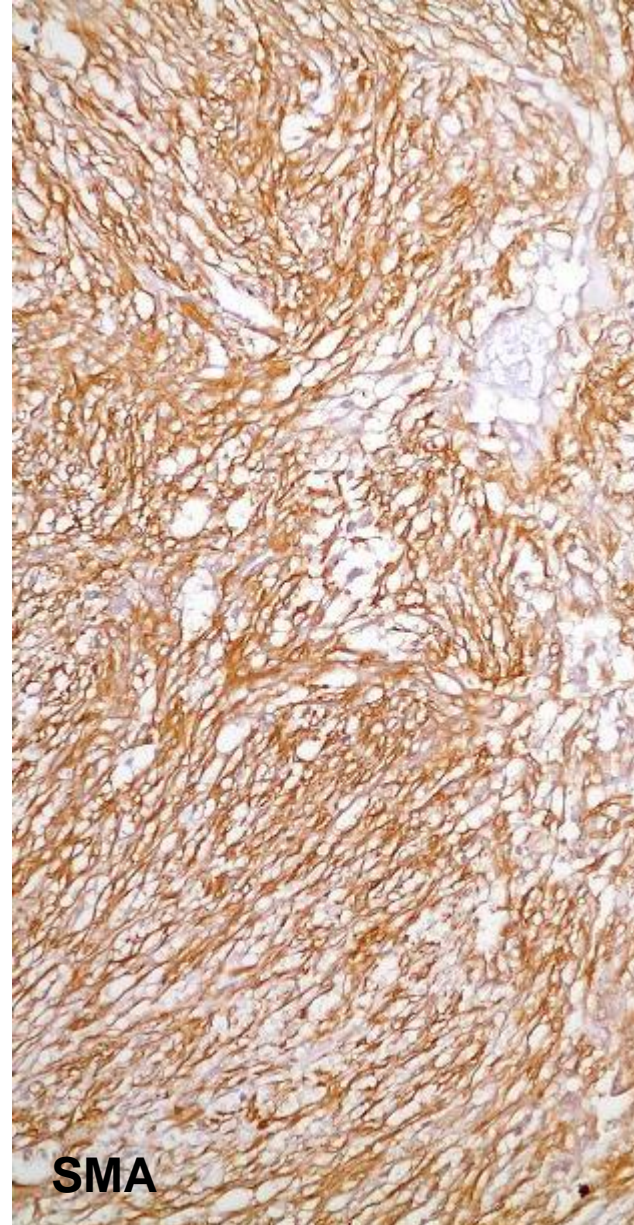












TANI:

Nodüler fasiit

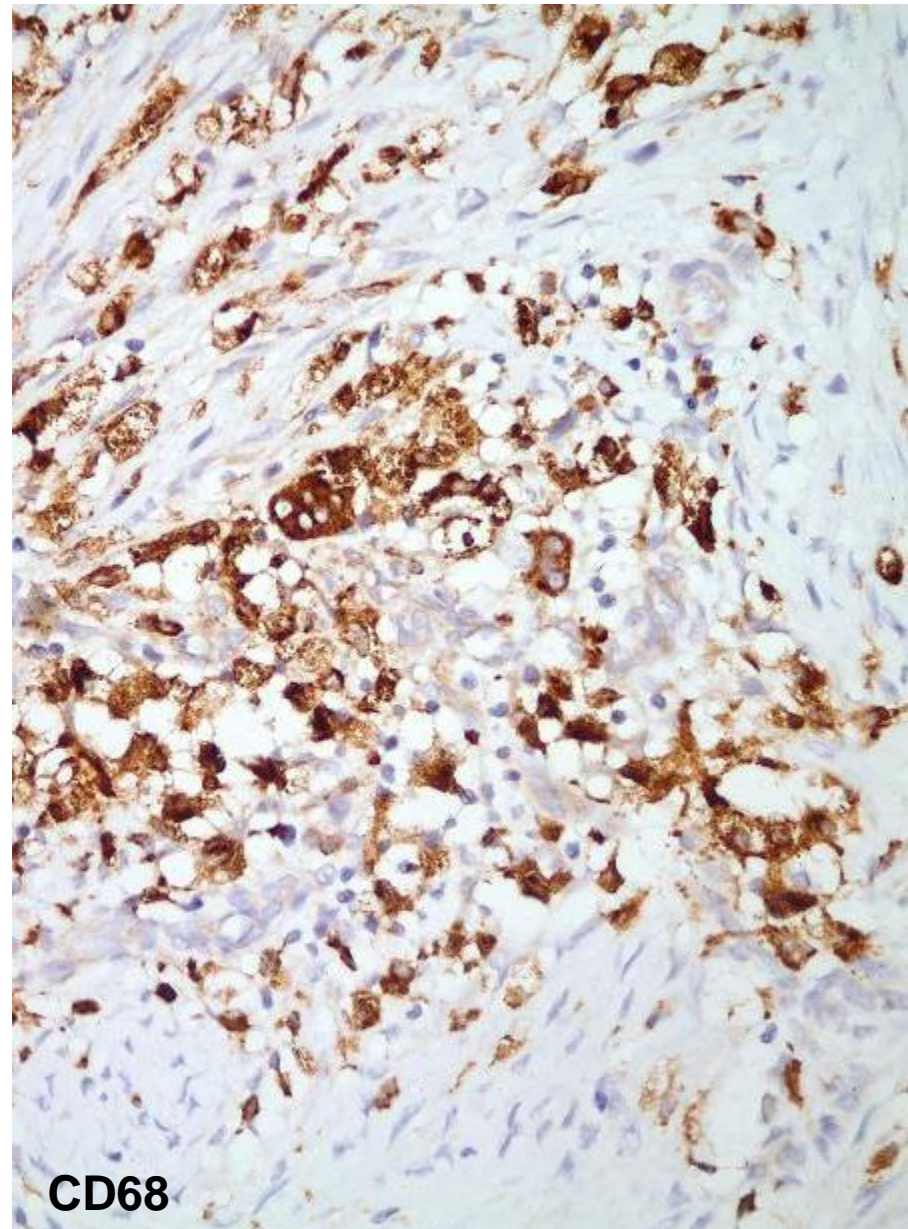
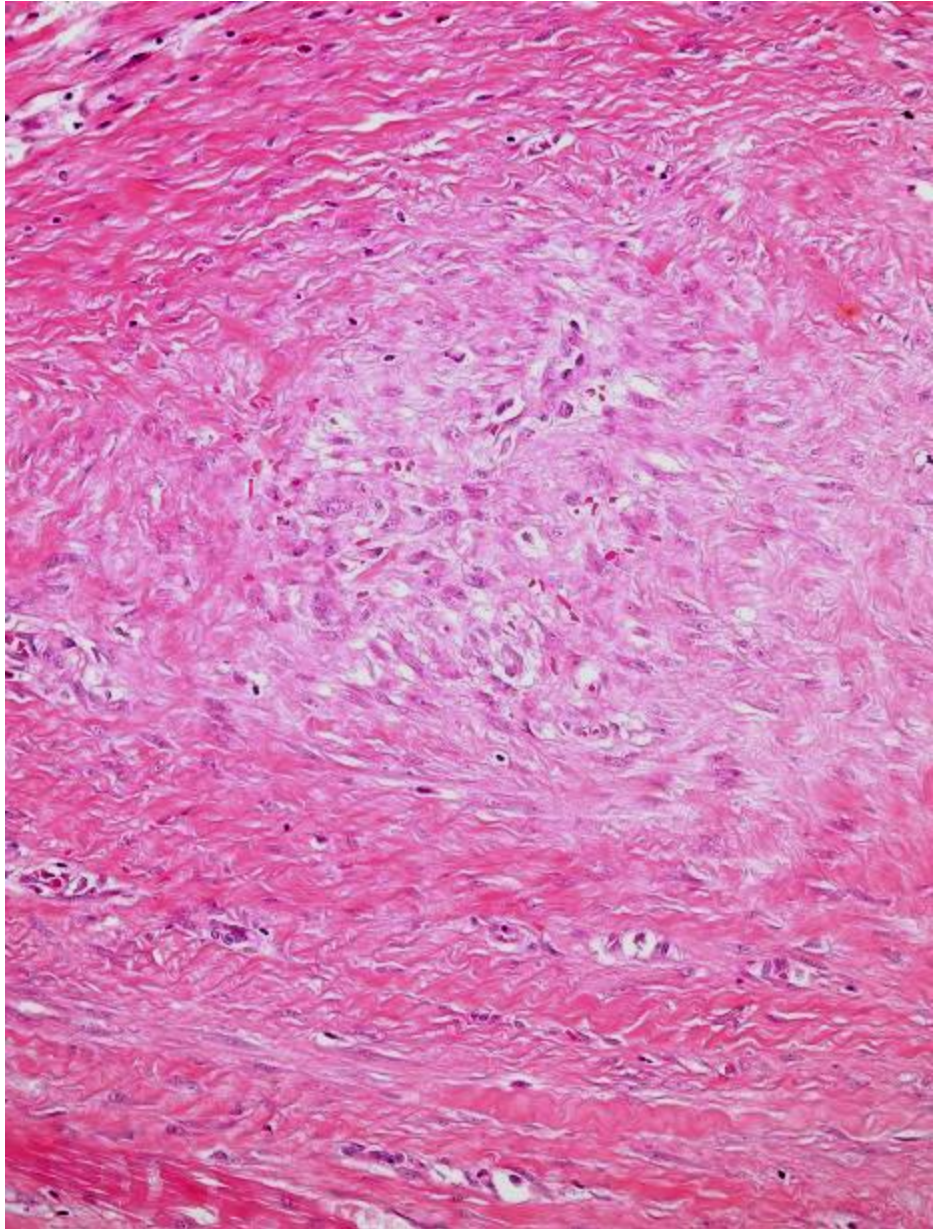
Nodüler fasiit *İnciler*

Klinik

- Genç erişkin
- Üst ekstremitte, baş boyun, gövde
- Subkütan (nadiren yüzeysel ve intramusküler)
- Hızlı büyüyen 5 cm den küçük kitle

Morfoloji

- Granülasyon dokusu benzeri
- Dejenere boşluklar ve eritrosit ekstravazasyonu
- Mitoz ↑
- Dev hücreler ve saçılmış lenfositler
- SMA+, desmin-, h-caldesmon-

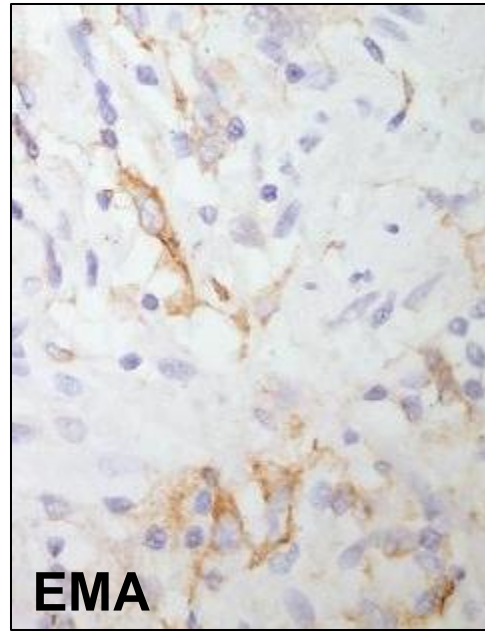
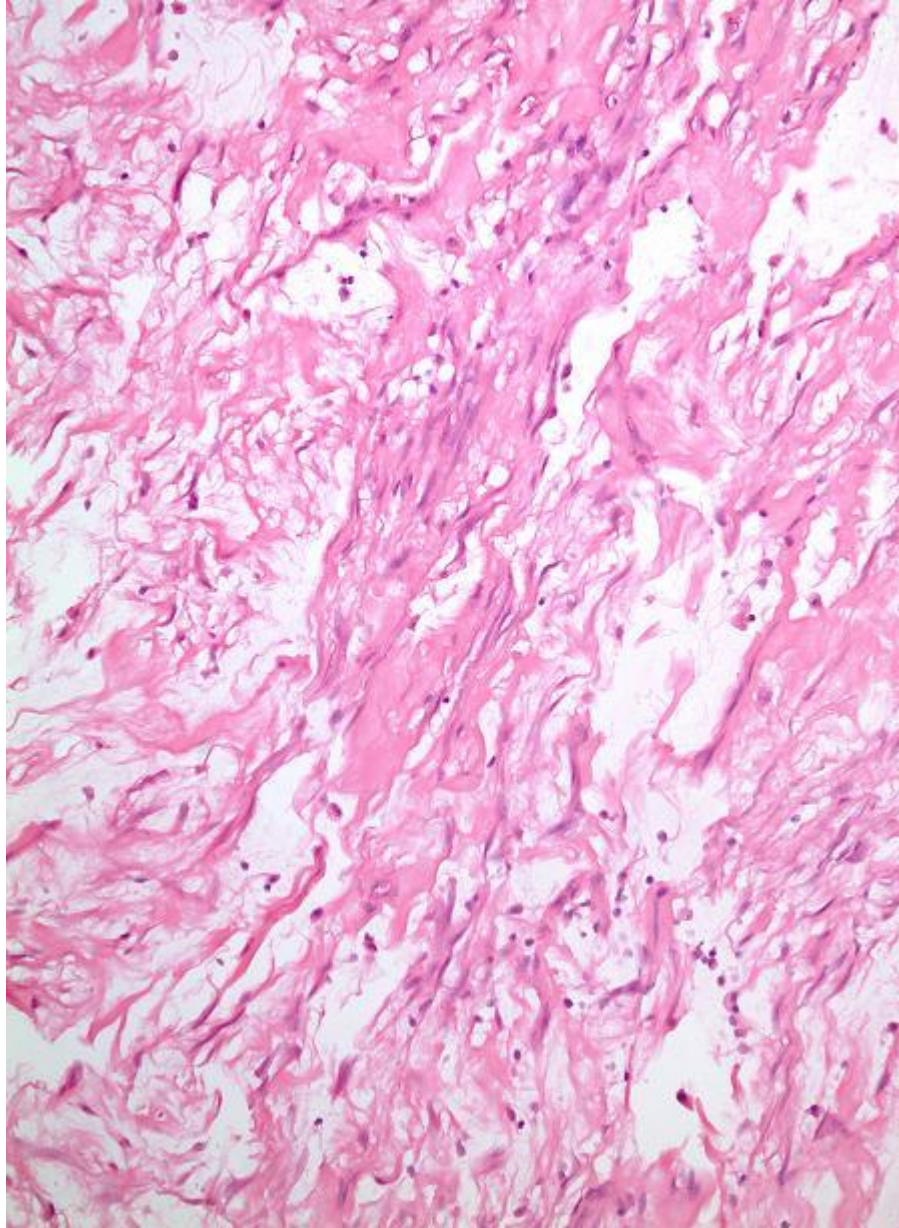


CD68

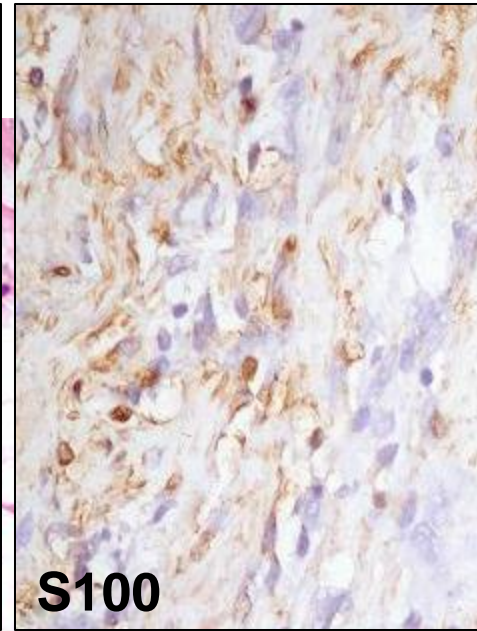
Nodüler fasiit

DDx

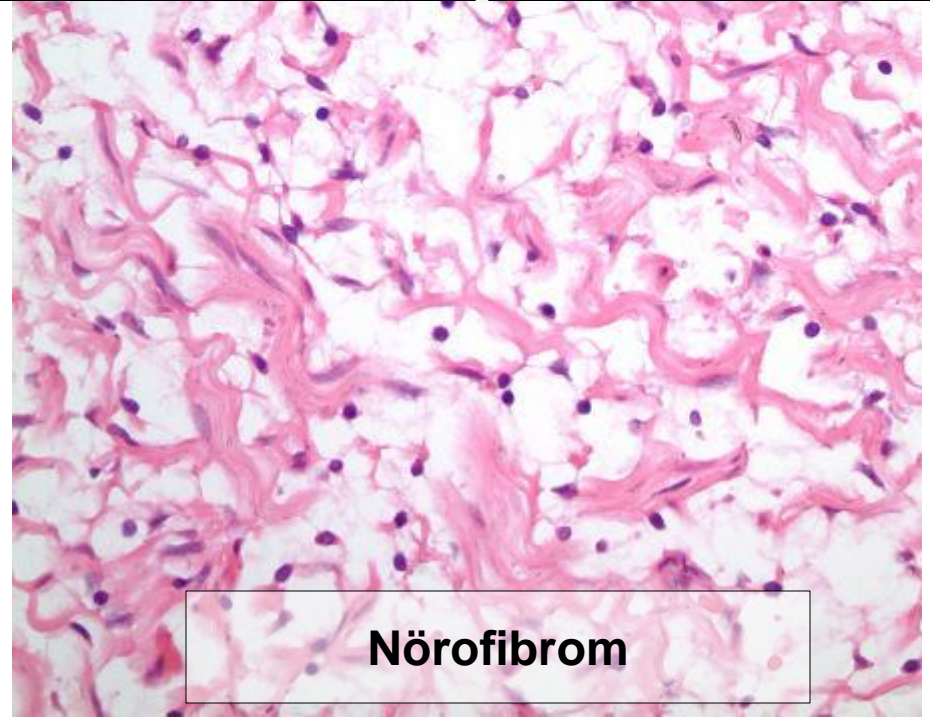
- İğsi hücreli sarkomlar
 - Sinovyal sarkom
 - Leiomyosarkom
 - Fibrosarkom
- Fibromatozis
- Mikzoid lezyonlar



EMA

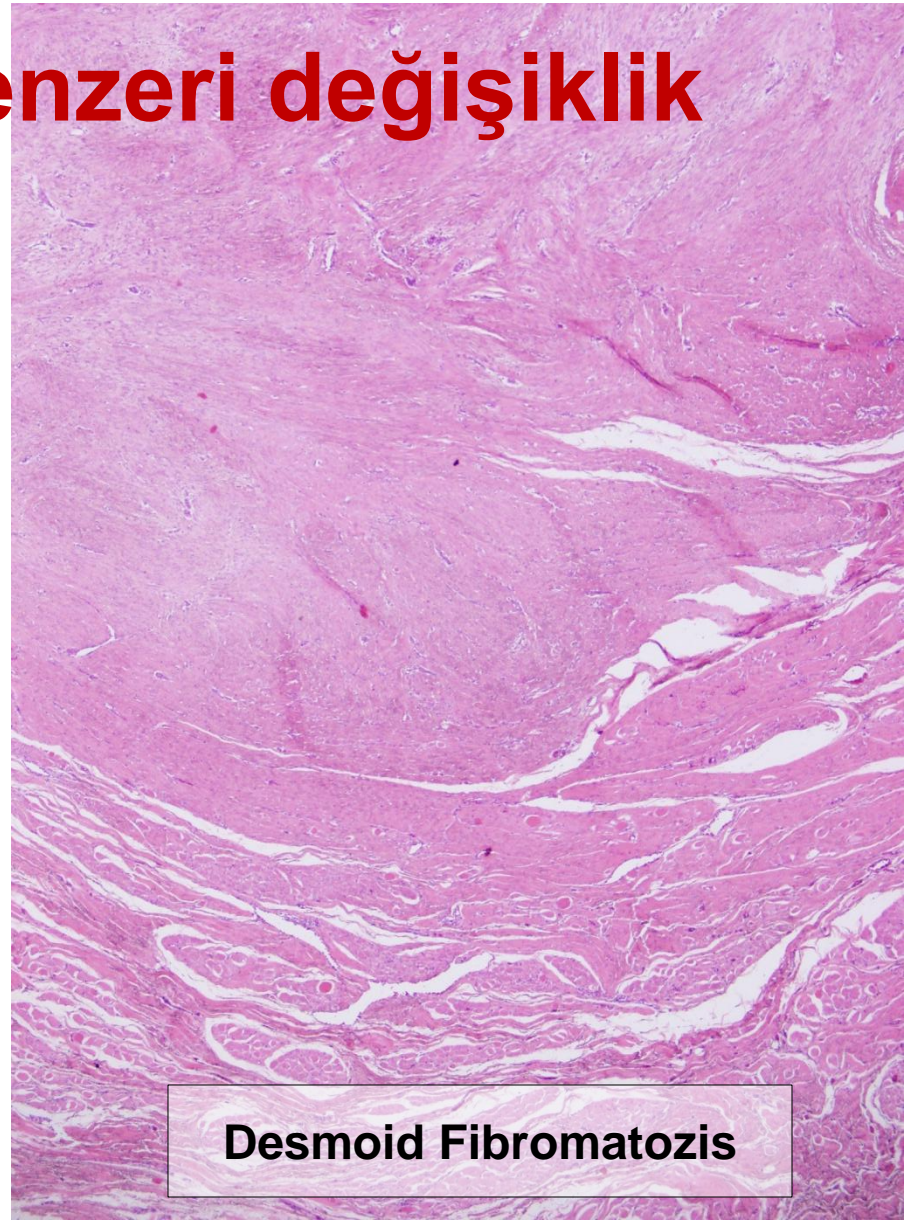
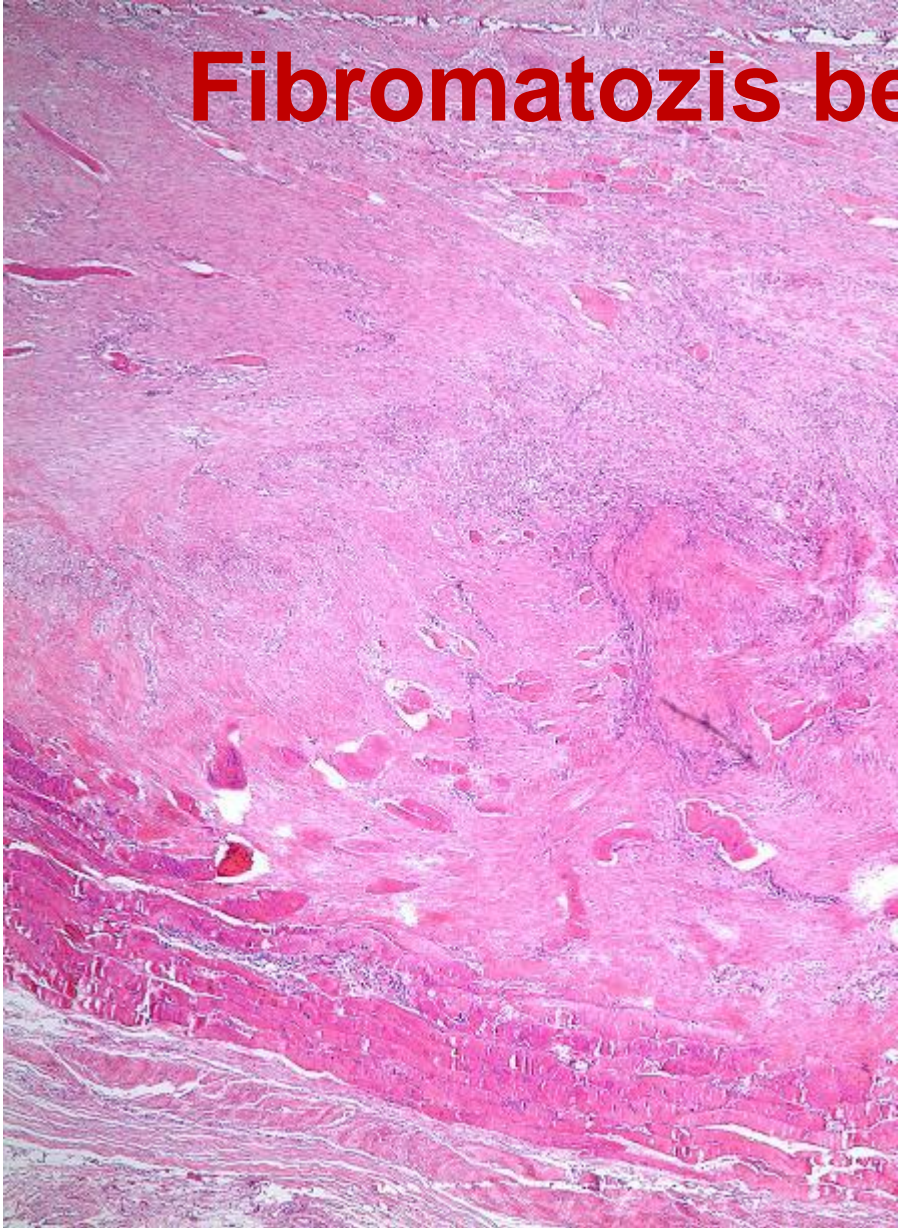


S100

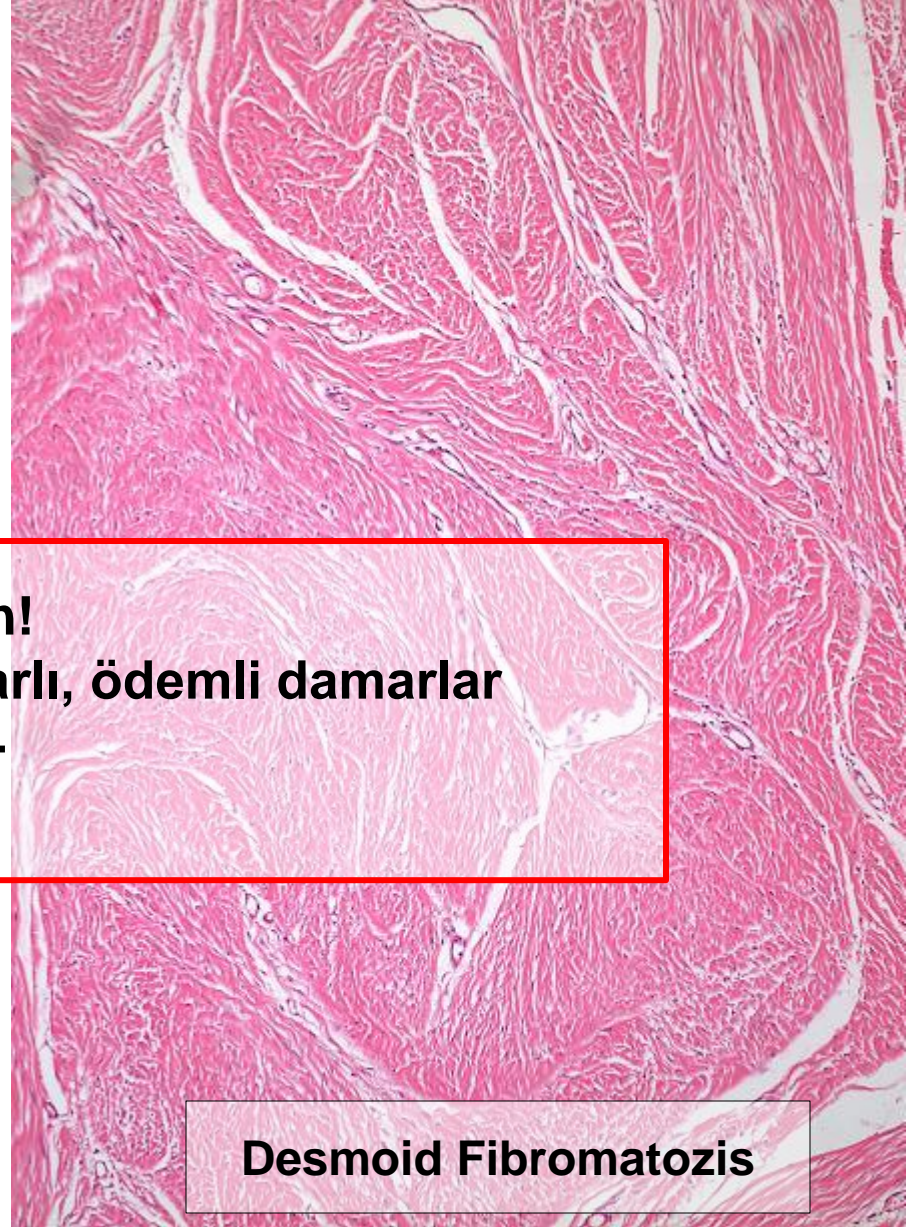
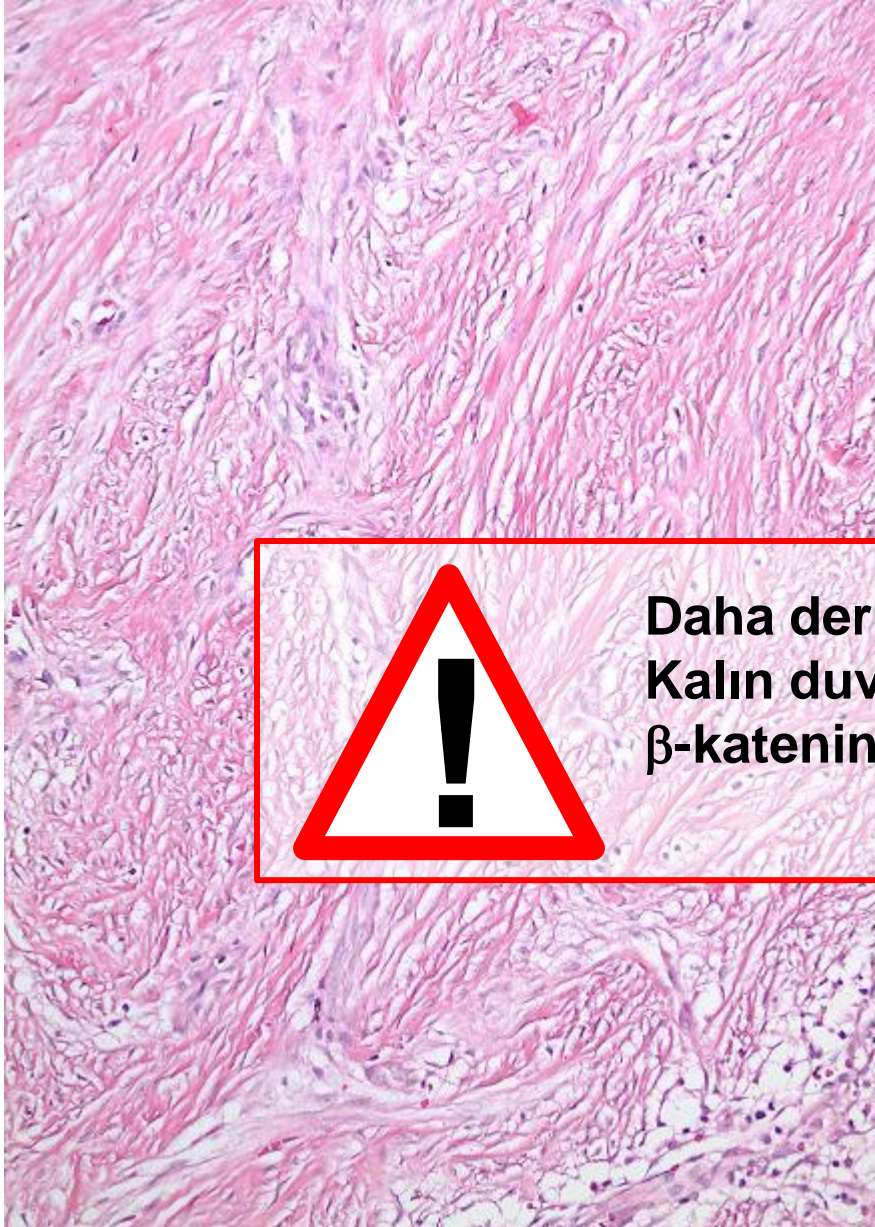

Nörofibrom

Fibromatozis benzeri deęişiklik



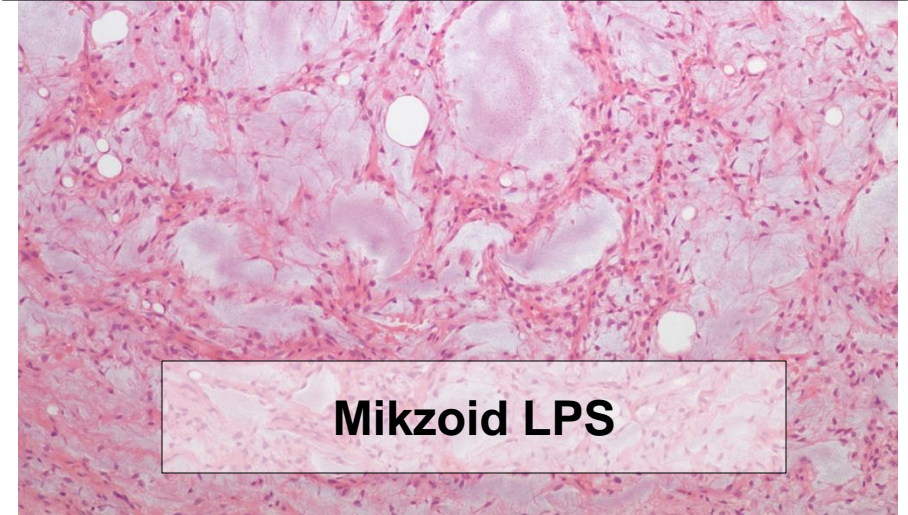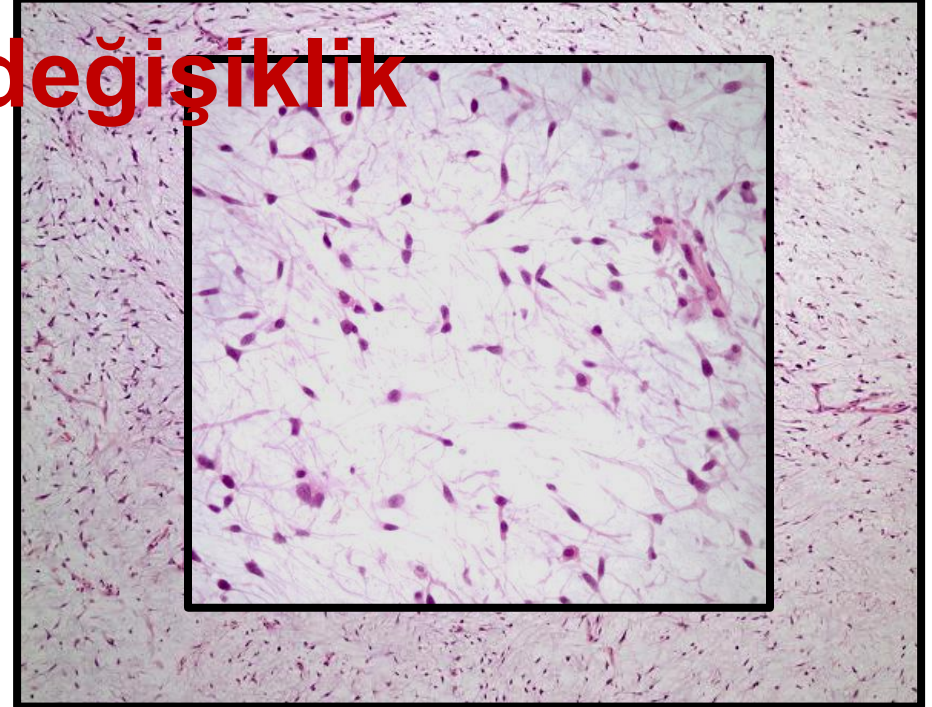
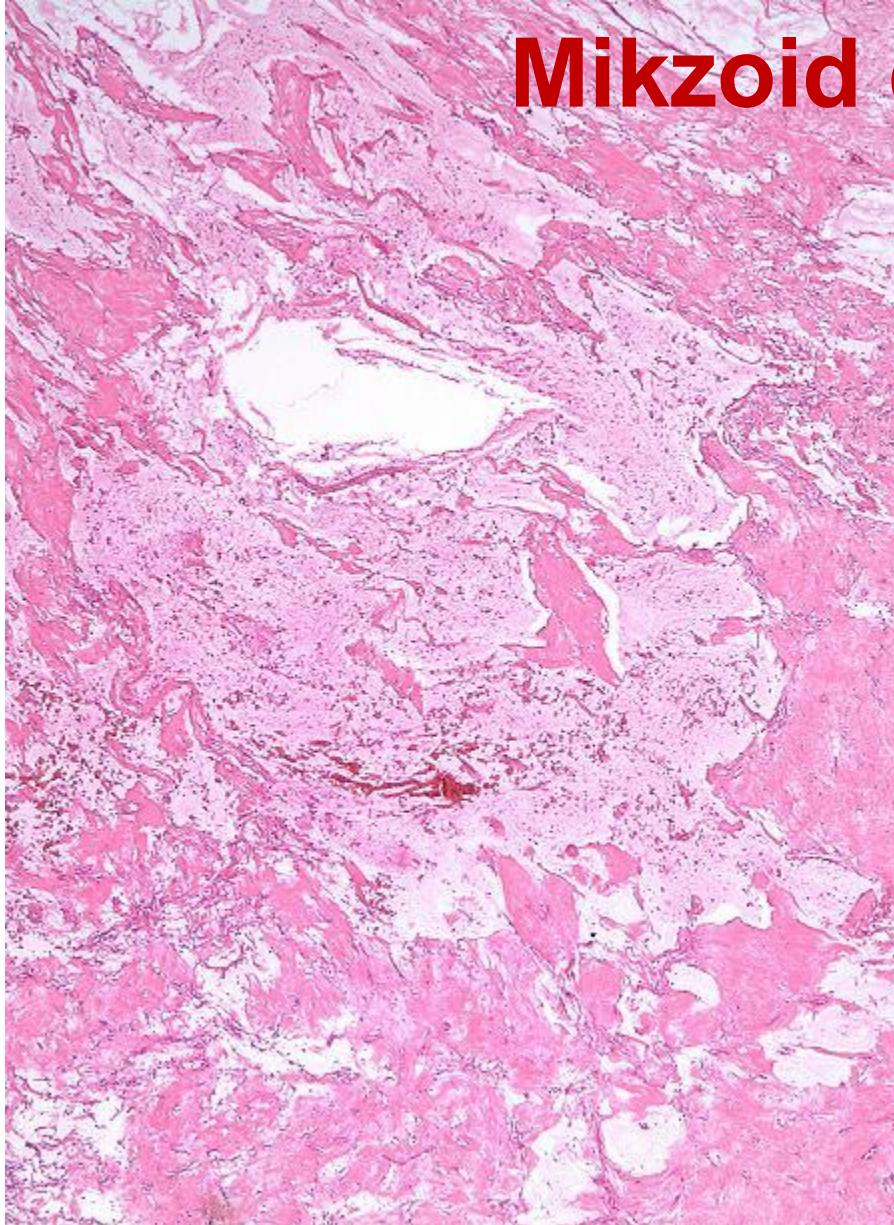
Desmoid Fibromatozis



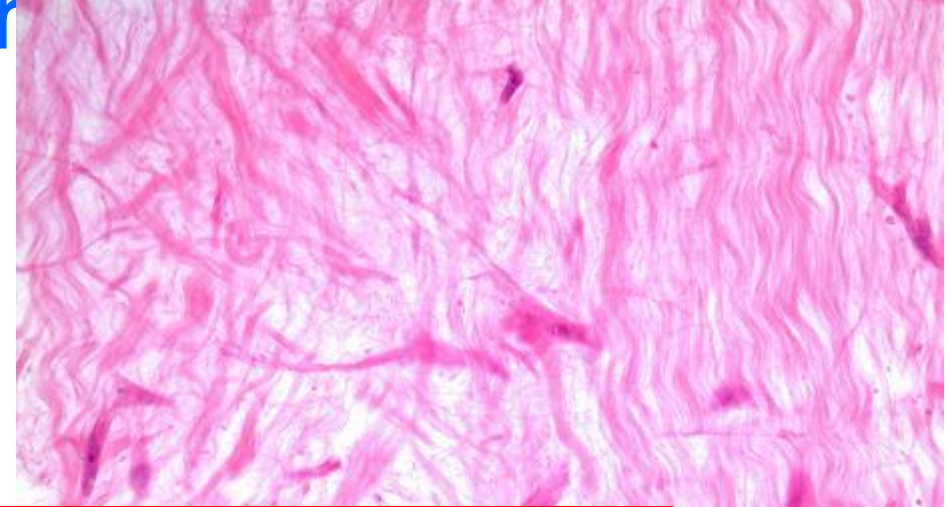
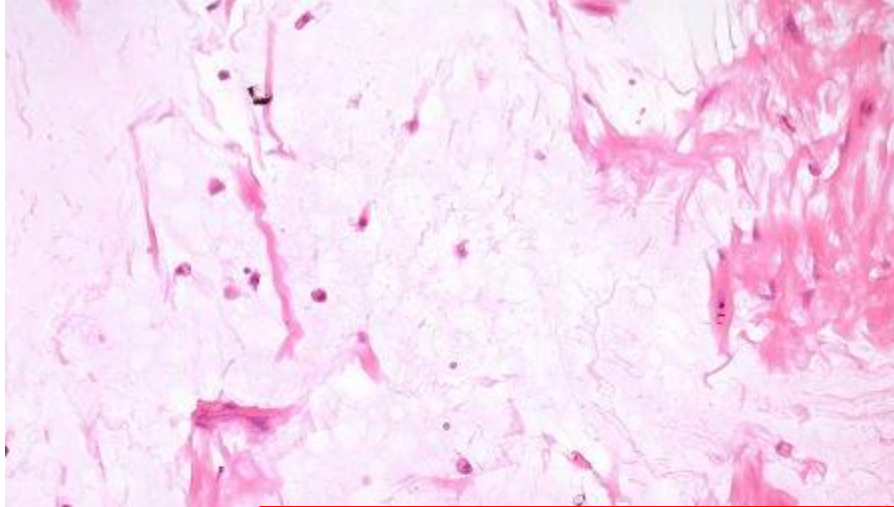
**Daha derin!
Kalın duvarlı, ödemli damarlar
 β -katenin+**

Desmoid Fibromatozis

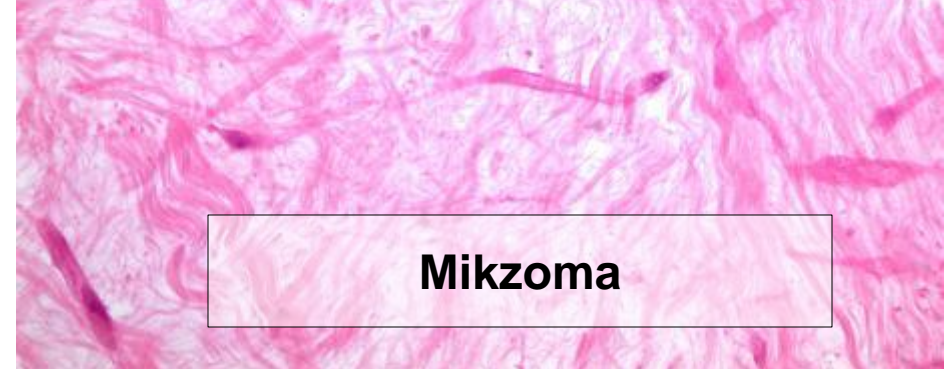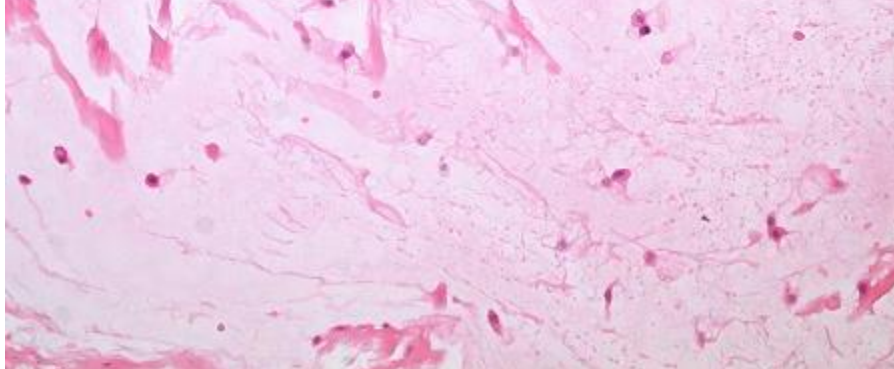Mikzoid deęişiklik



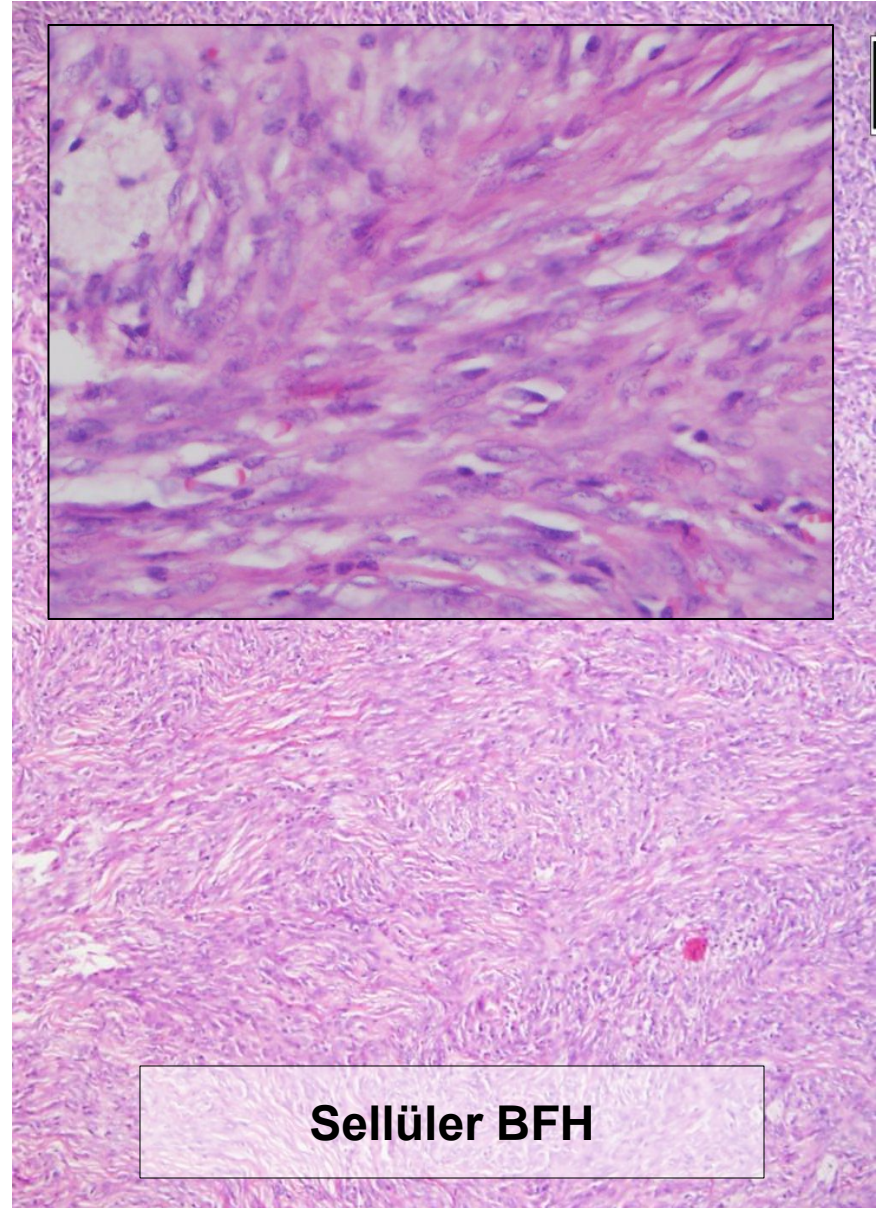
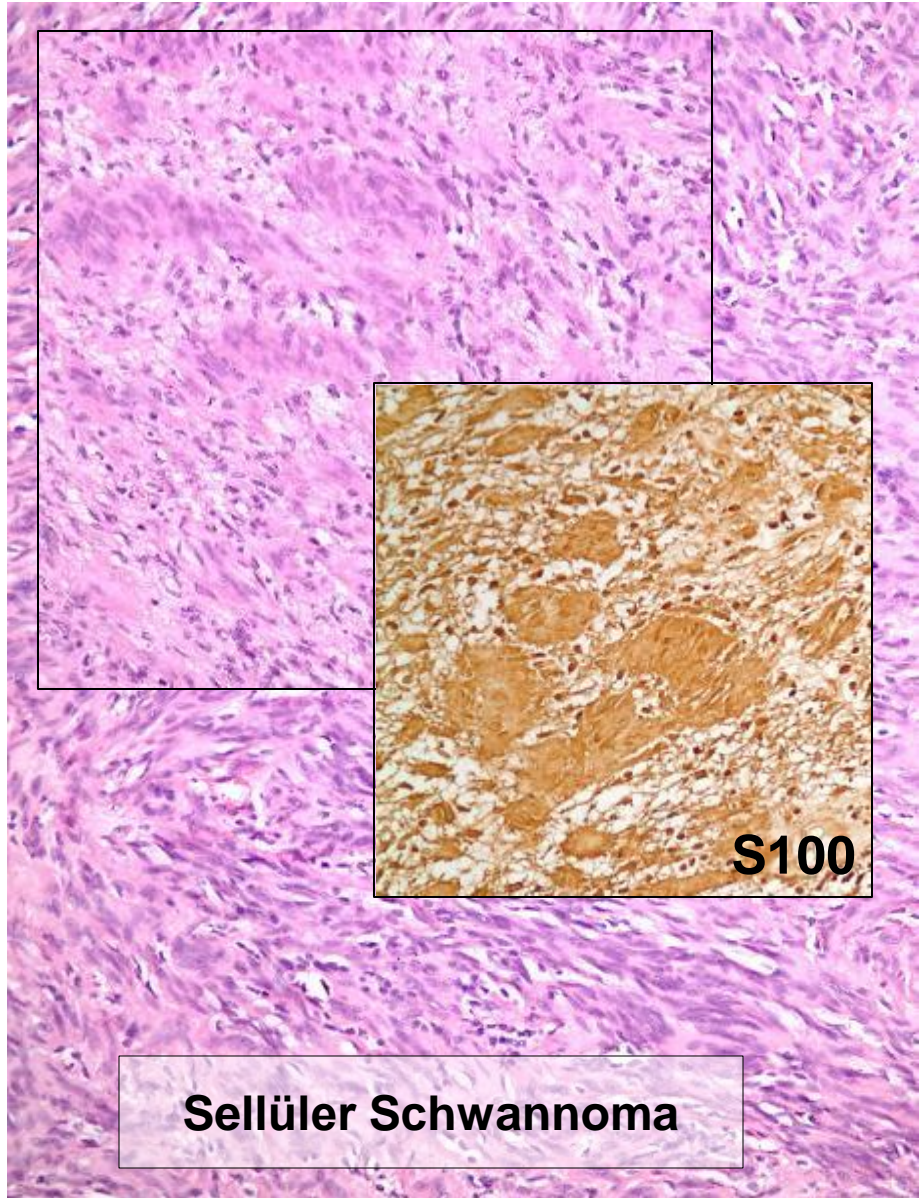
Mikzoid LPS



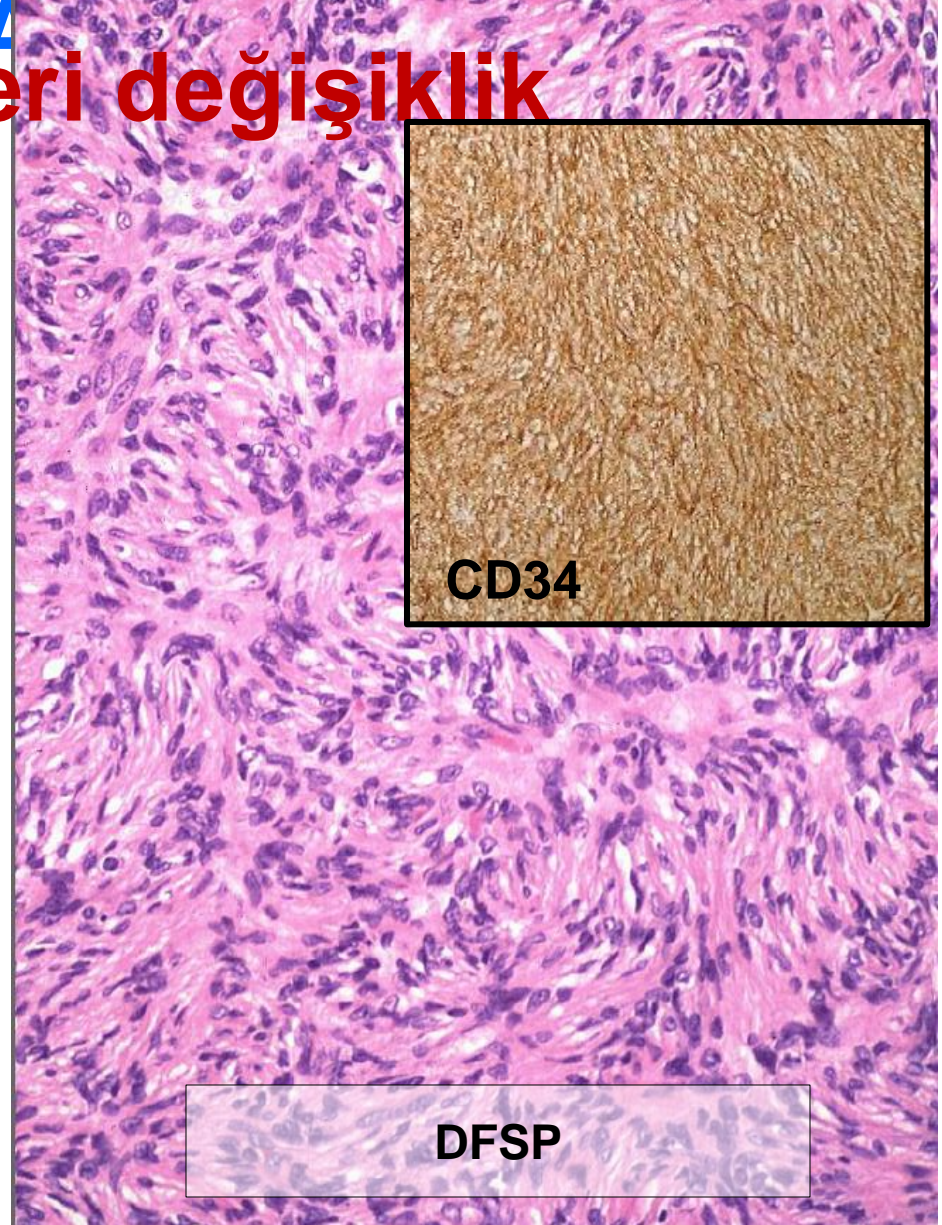
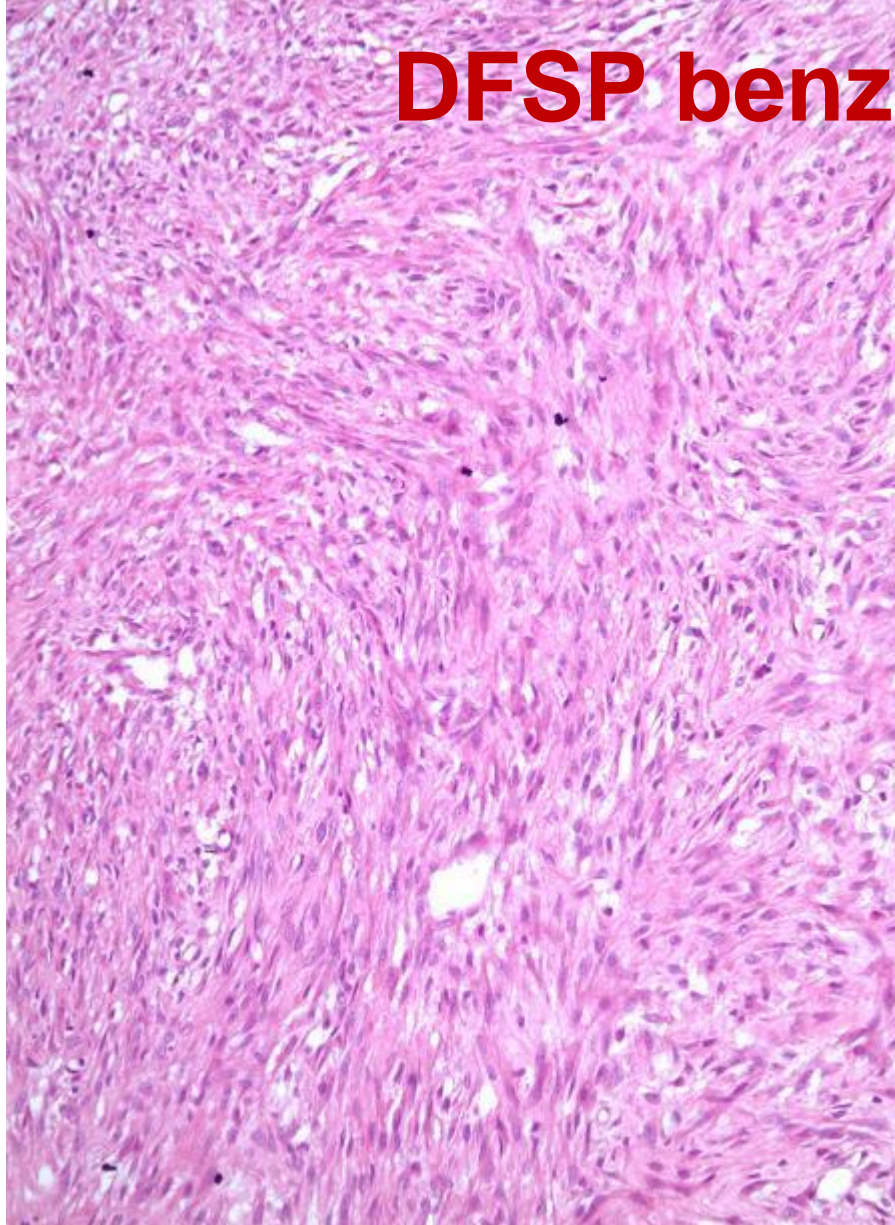
**Lezyon tamamen mikzoid mi?
Mikzoid olmayan alanları
değerlendirir!
Hücrelere bak!**



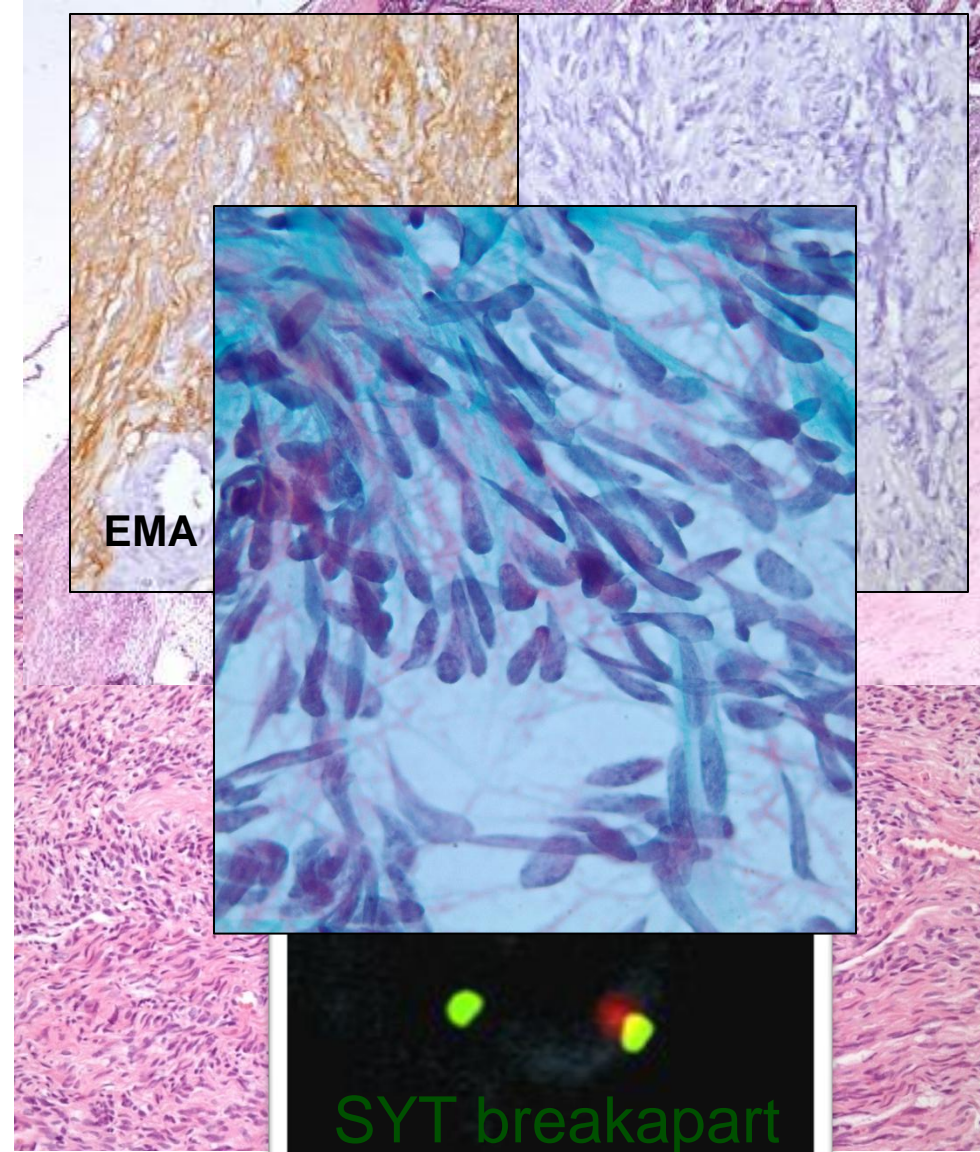
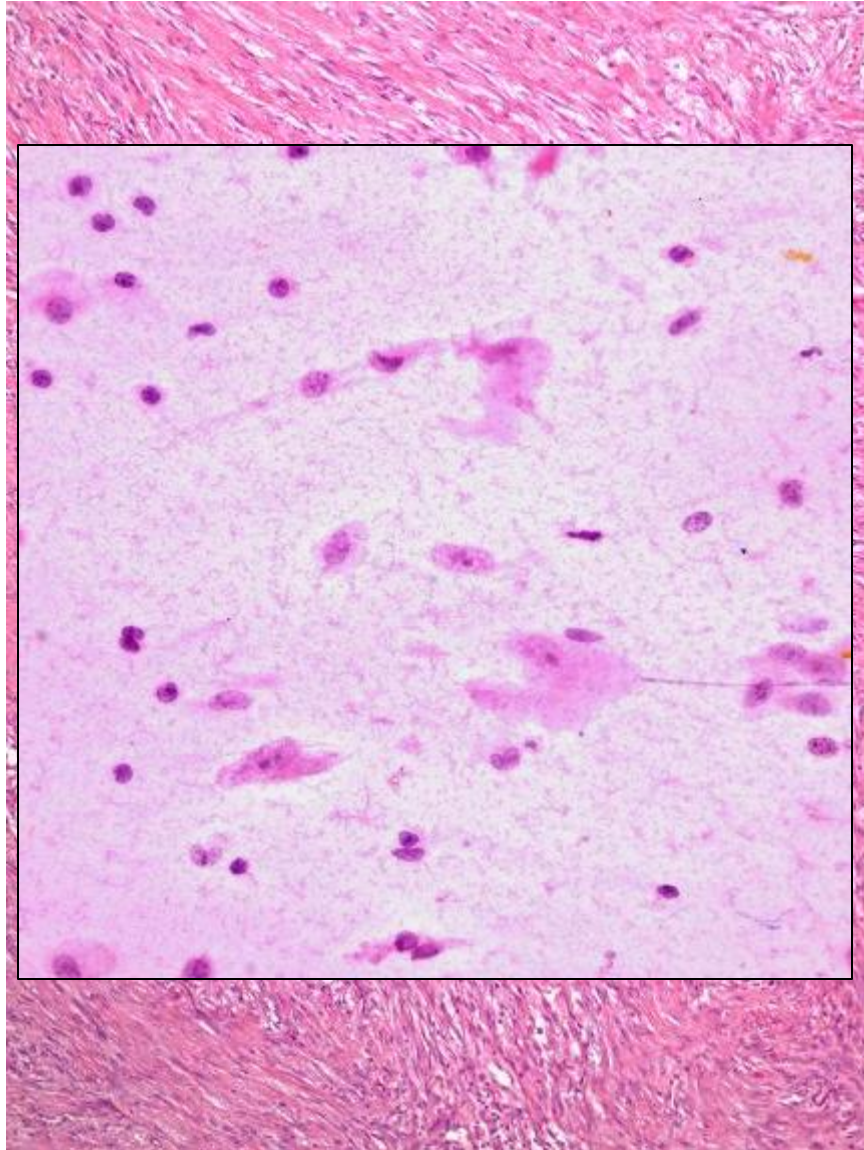
Mikzoma



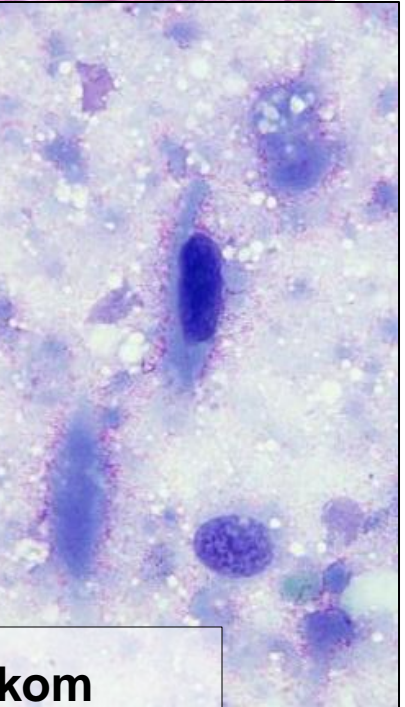
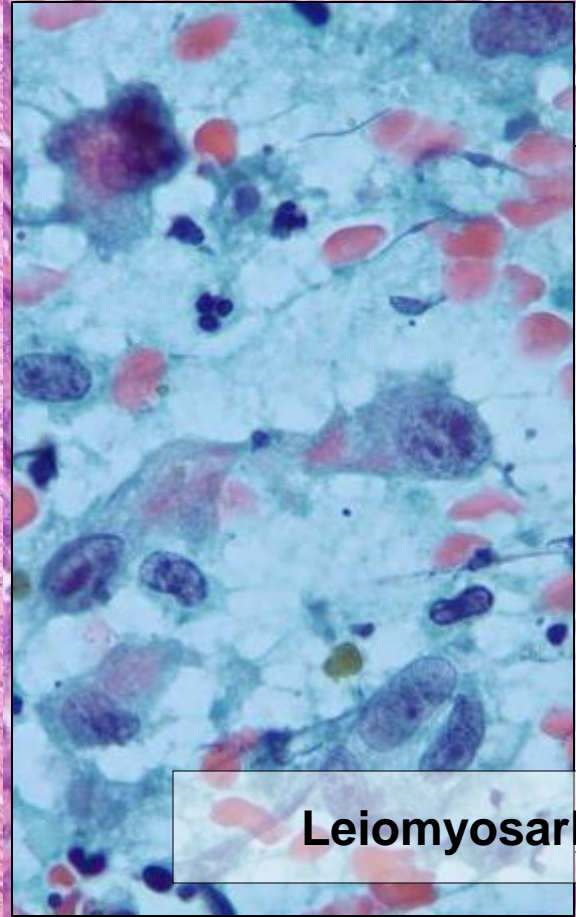
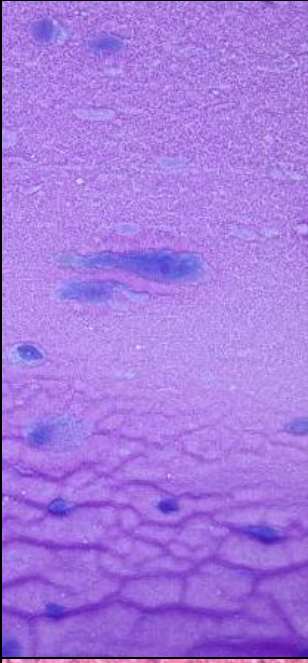
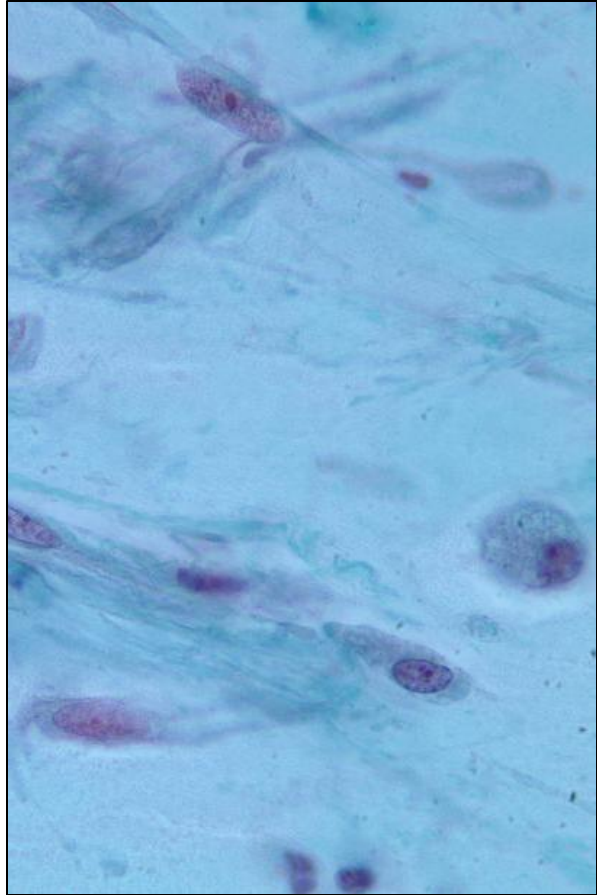
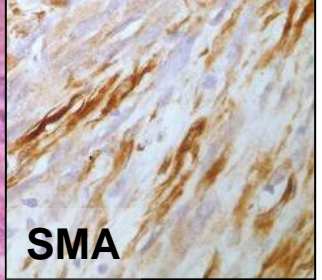
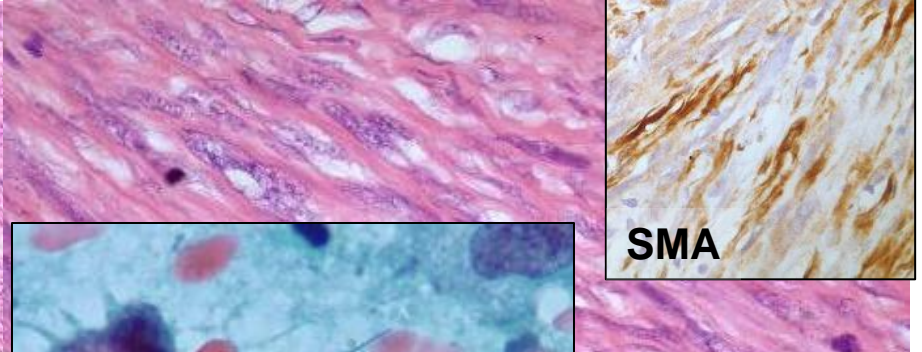
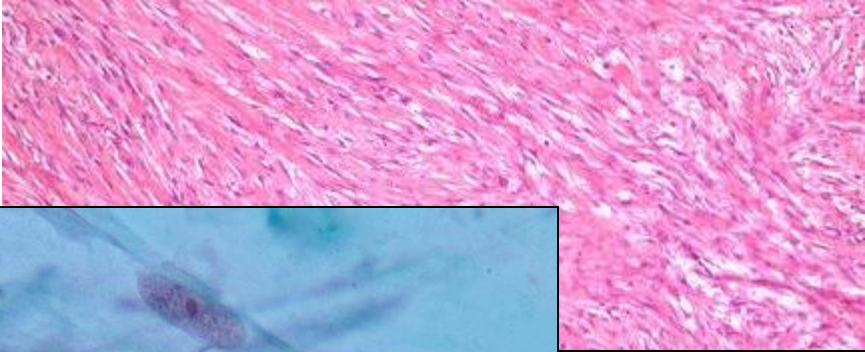
DFSP benzeri deęişiklik



Sinovyal sarkom

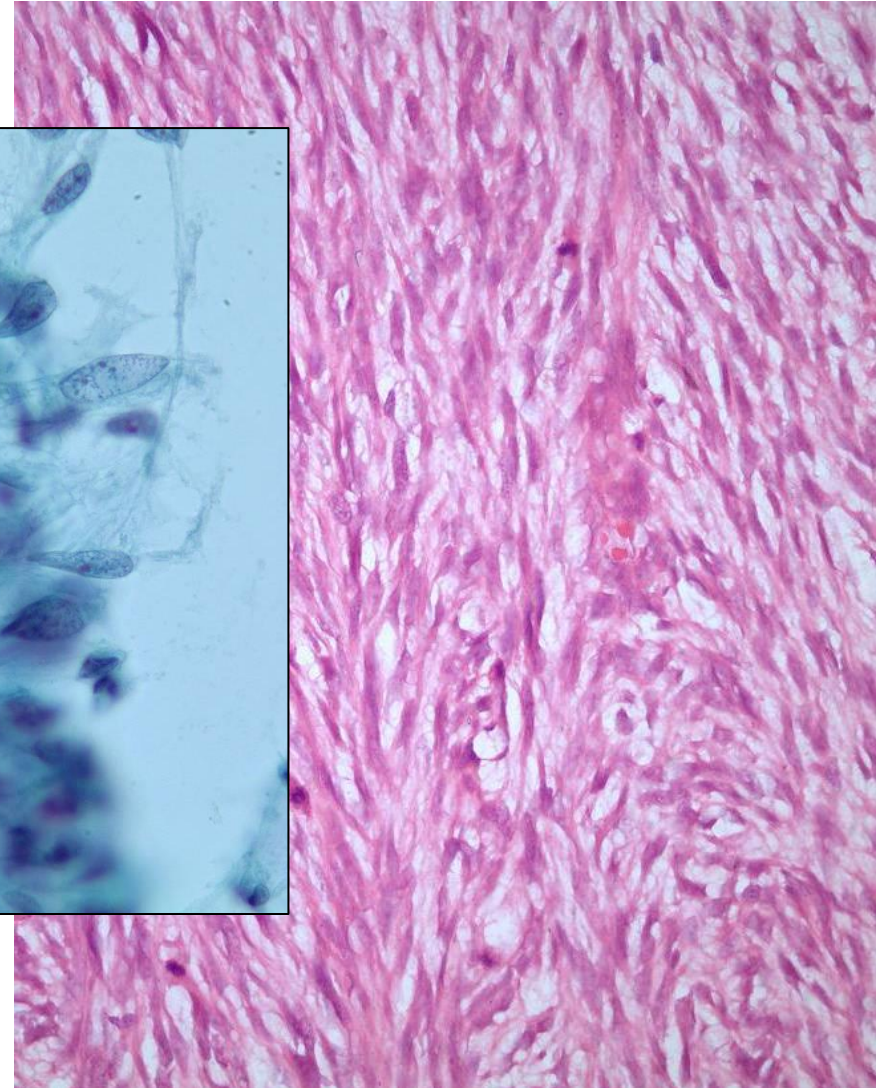
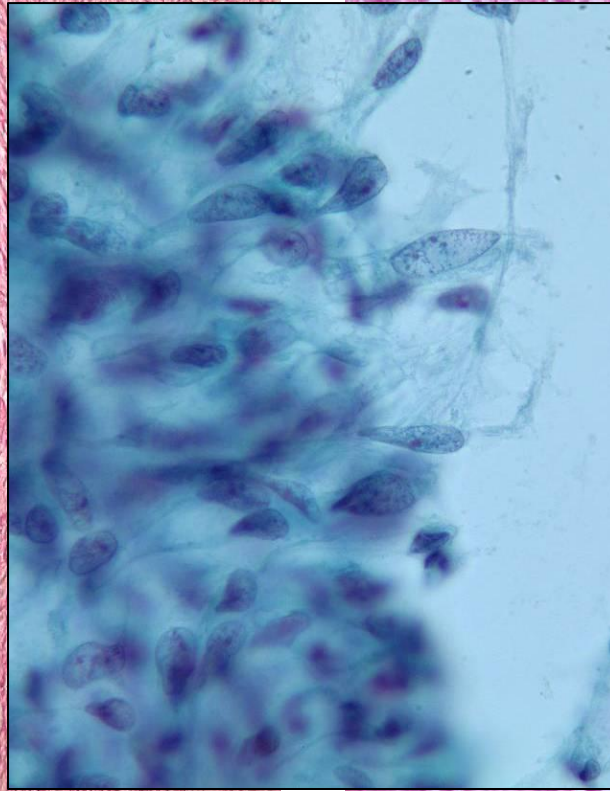
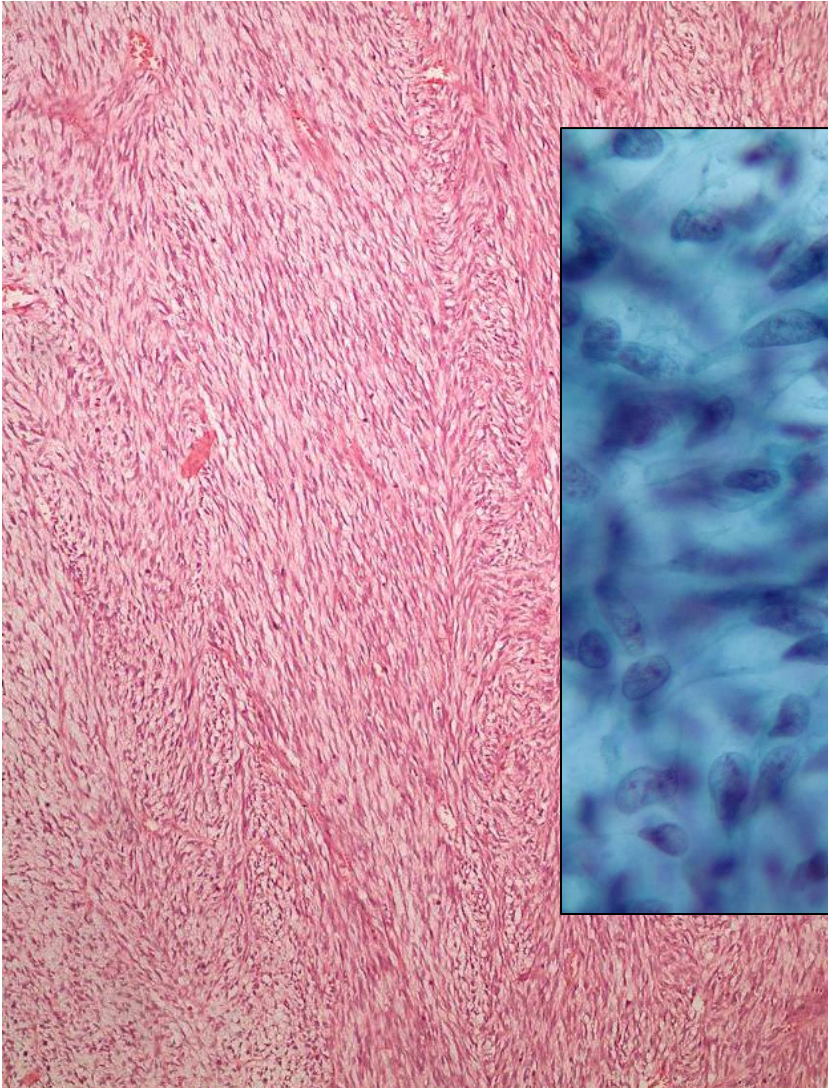


Leiomyosarkom



Leiomyosarkom

Fibrosarkom

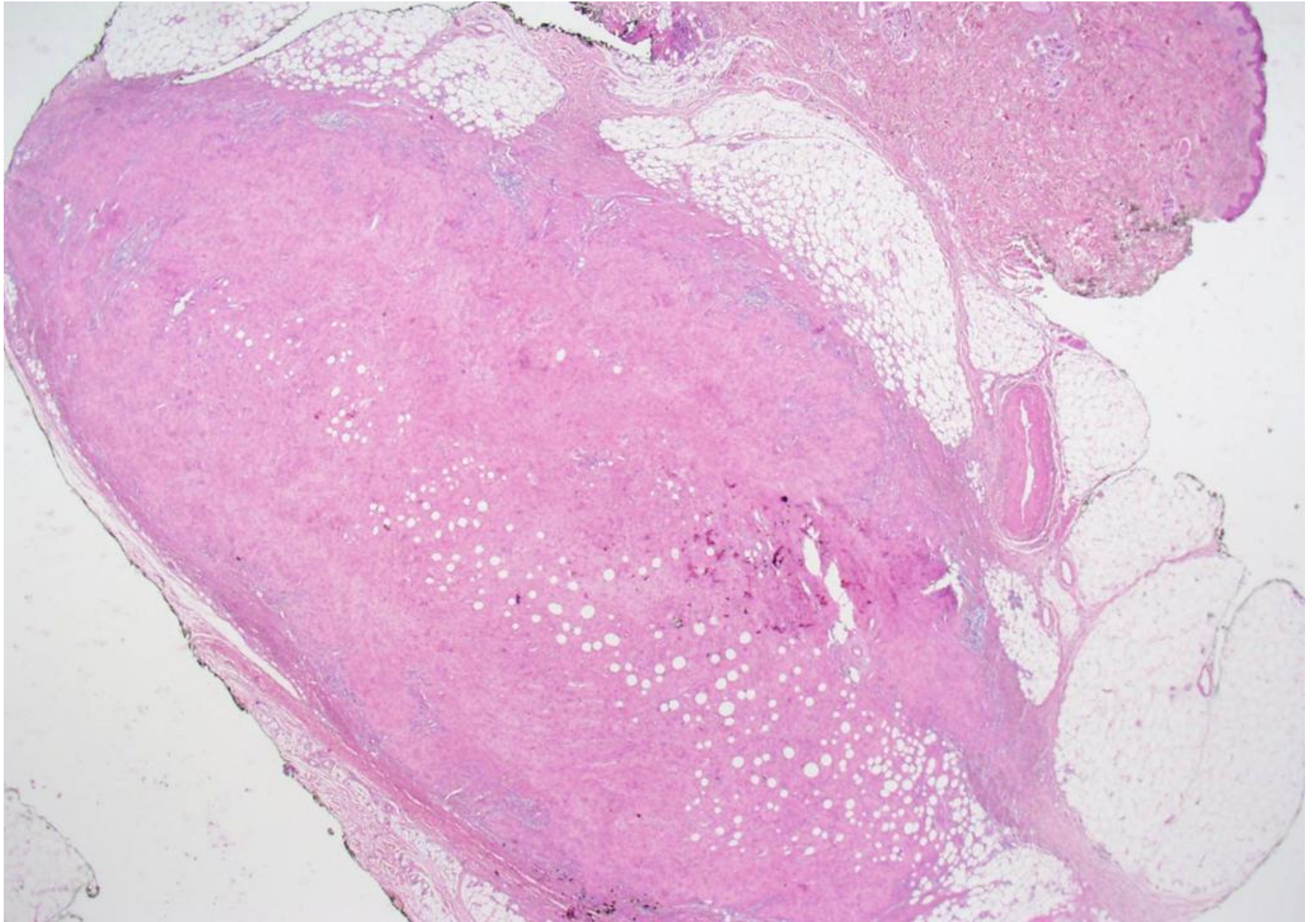


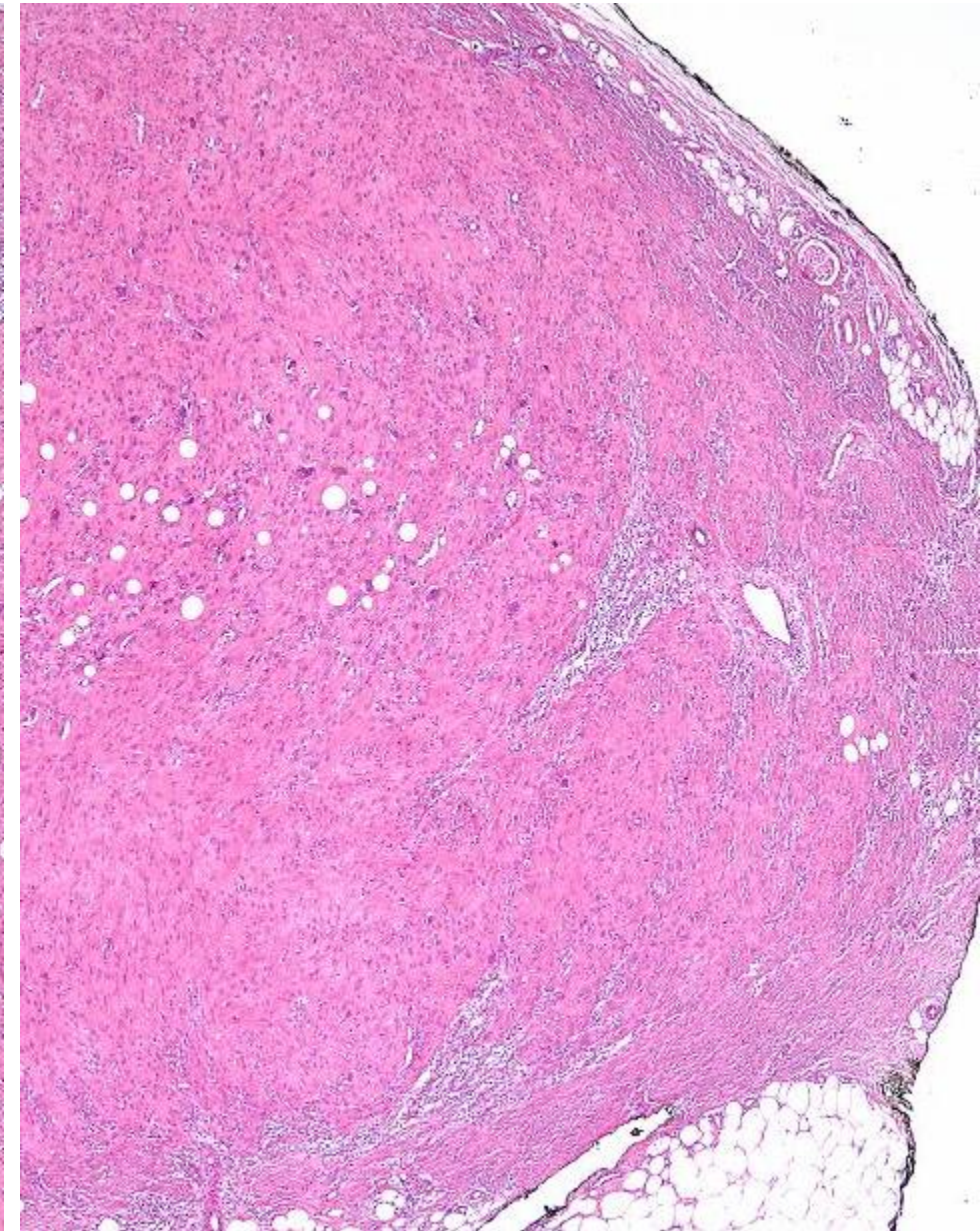
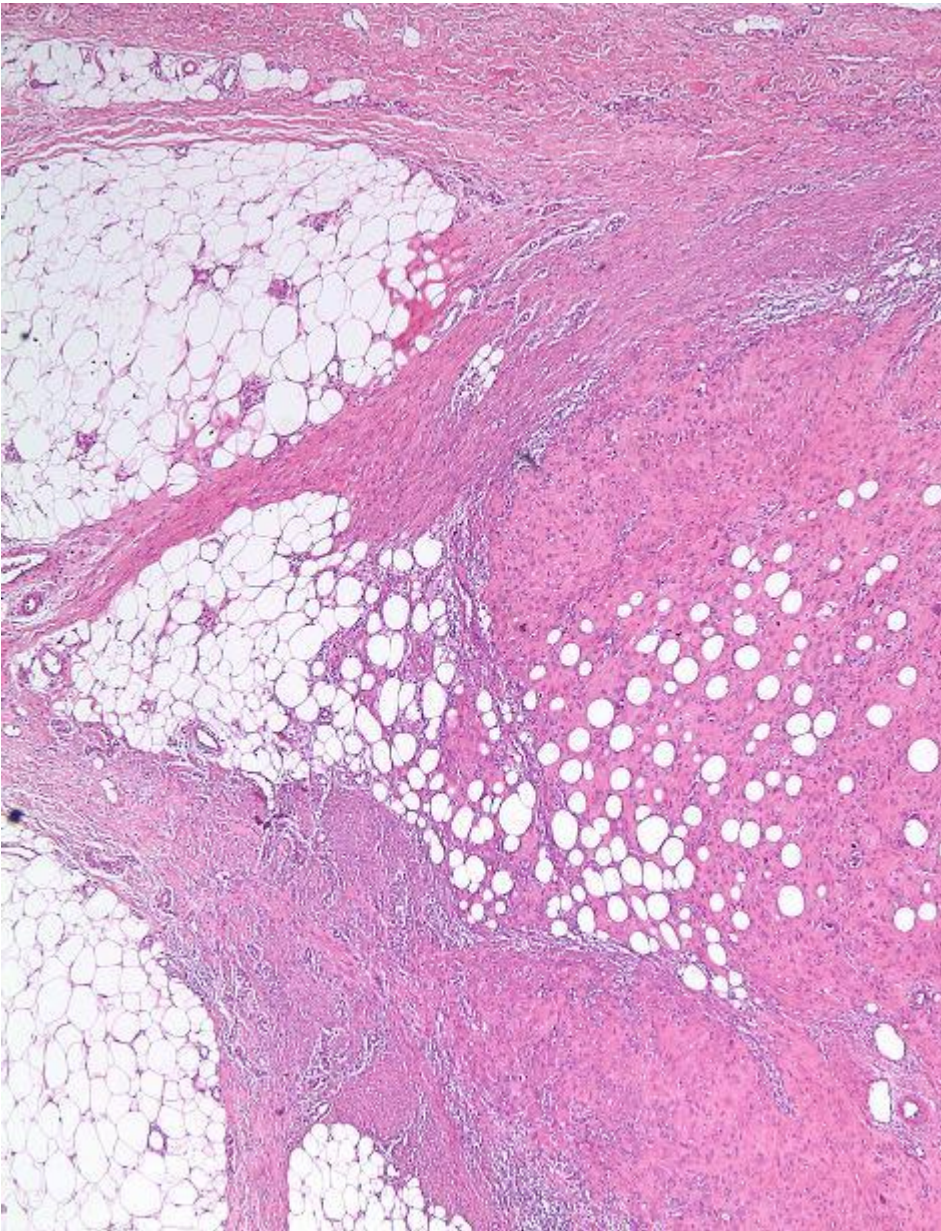
Olgu 2

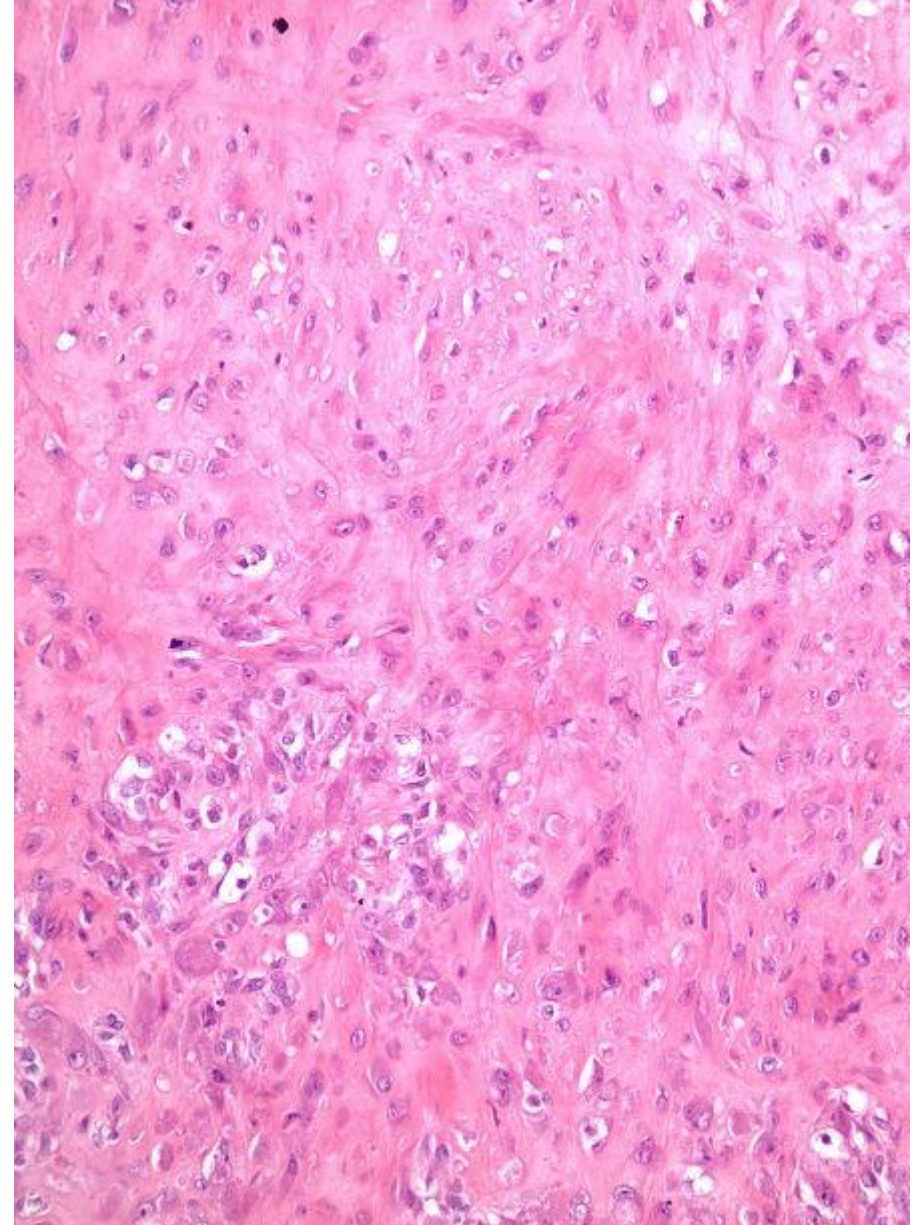
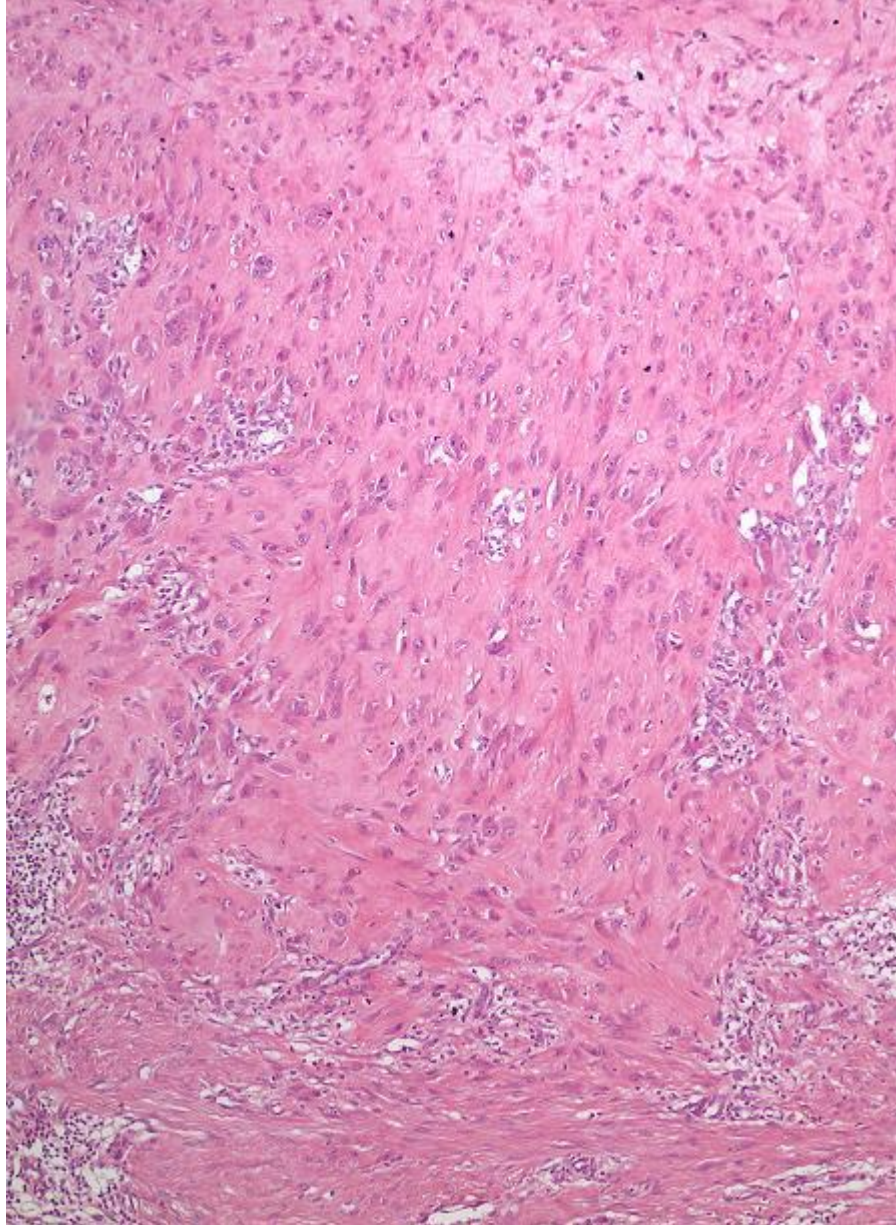
30 y ♂

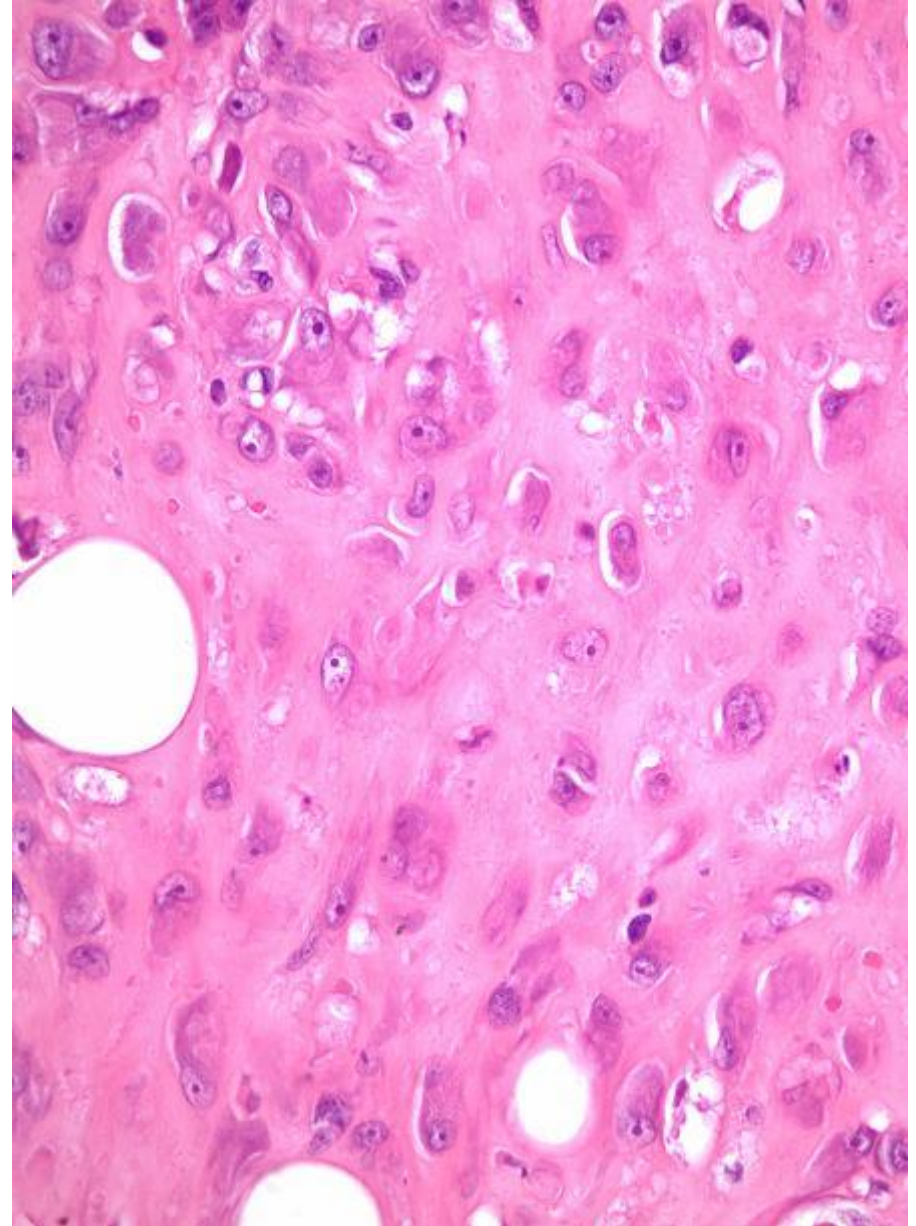
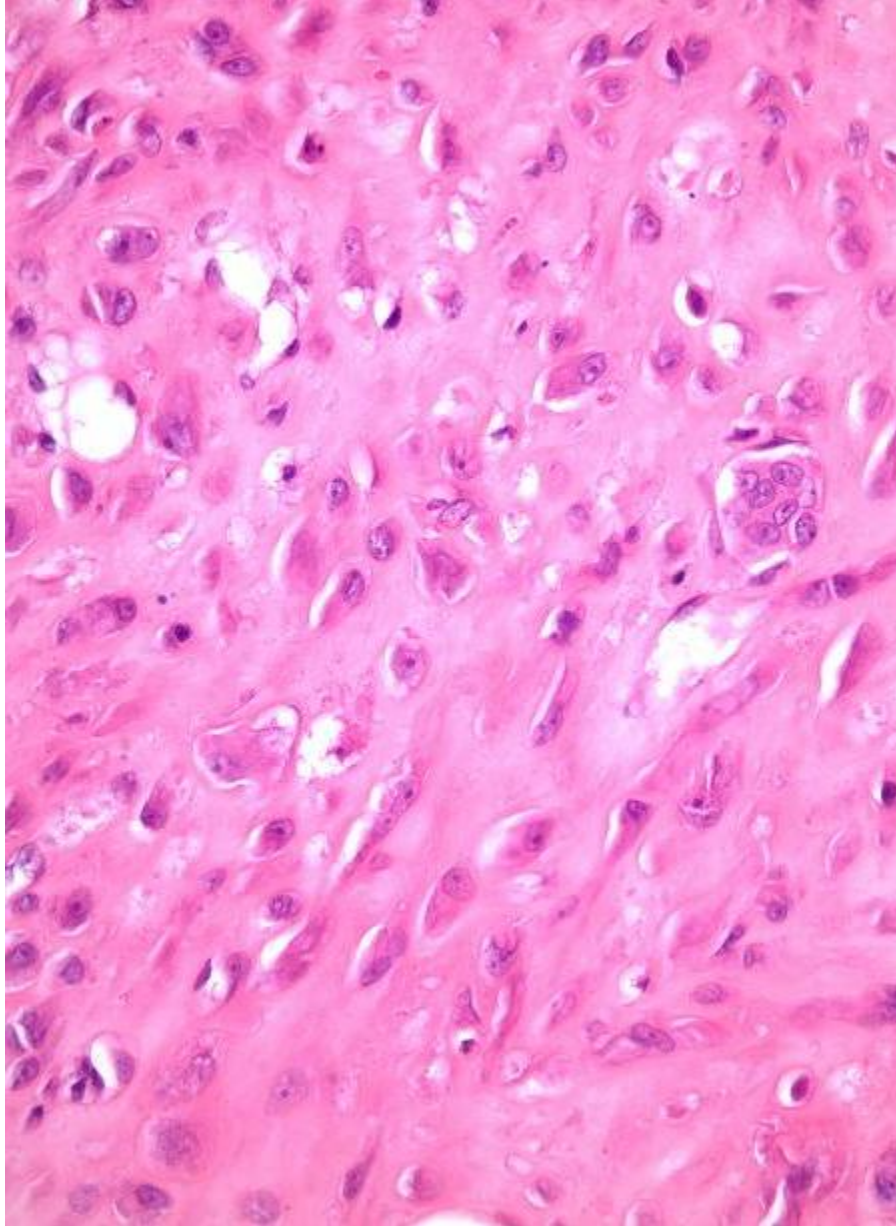
Ön kolda kitle

Schwannom?









TANI:

Proliferatif fasiit

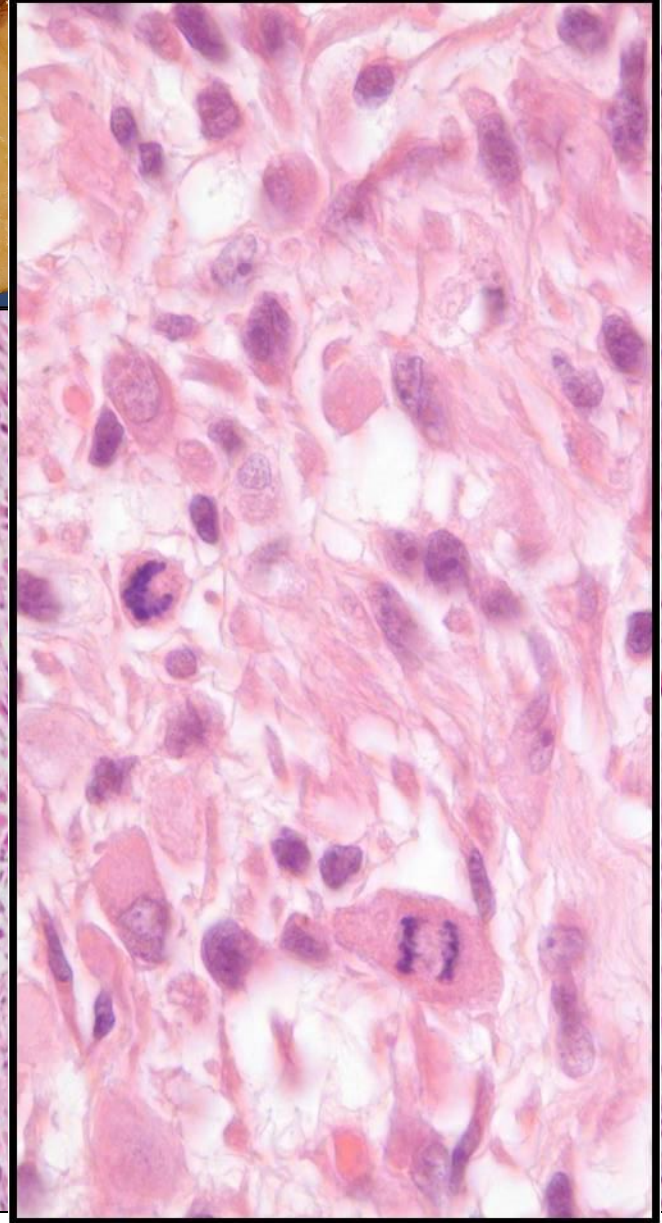
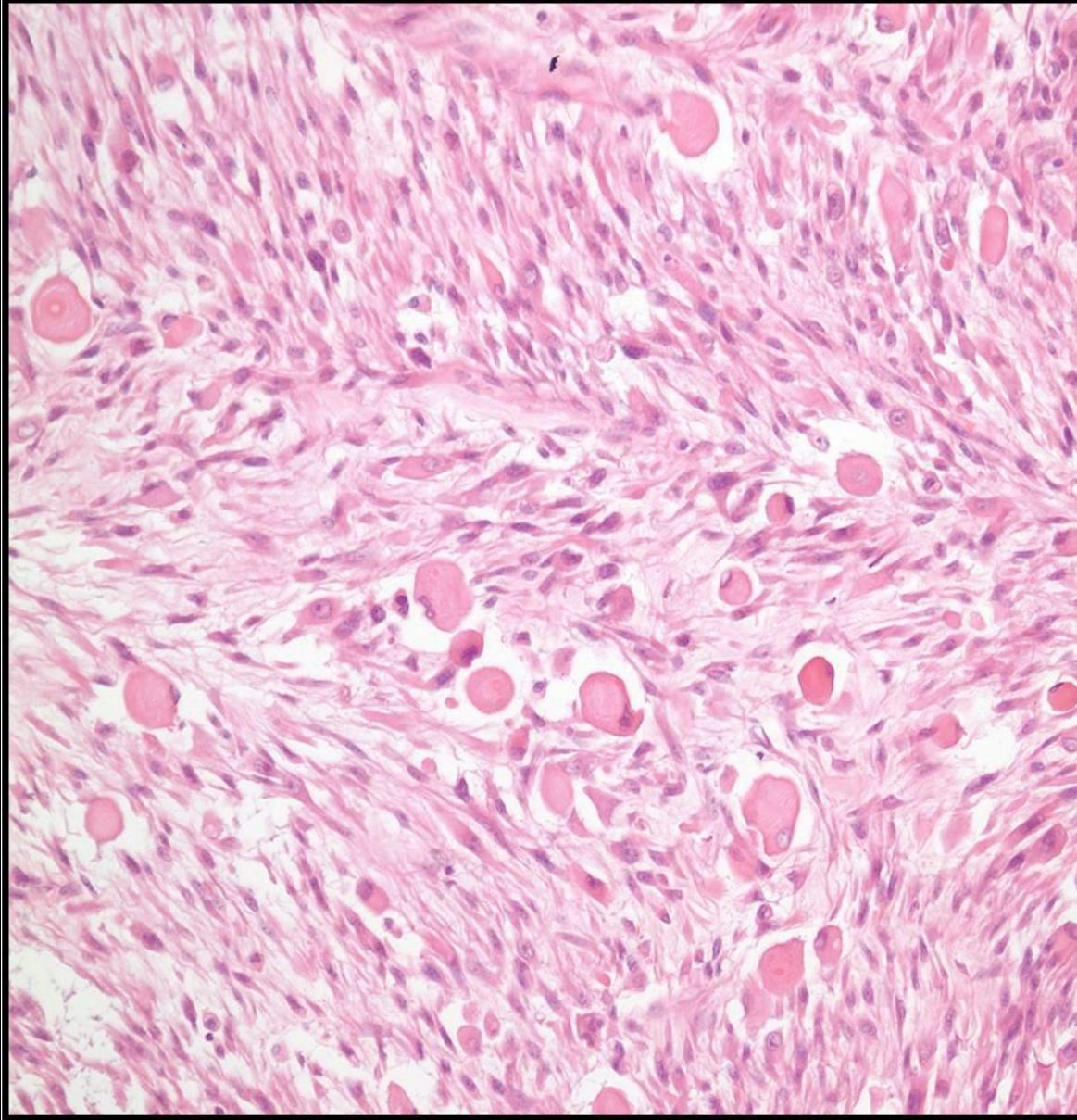
Proliferatif fasiit/myozit *İnciler*

Klinik

- Nodüler fasiit ile benzer klinik bulgular
- Myozit daha yaşlı ve gövde/omuz predominant

Morfolojik

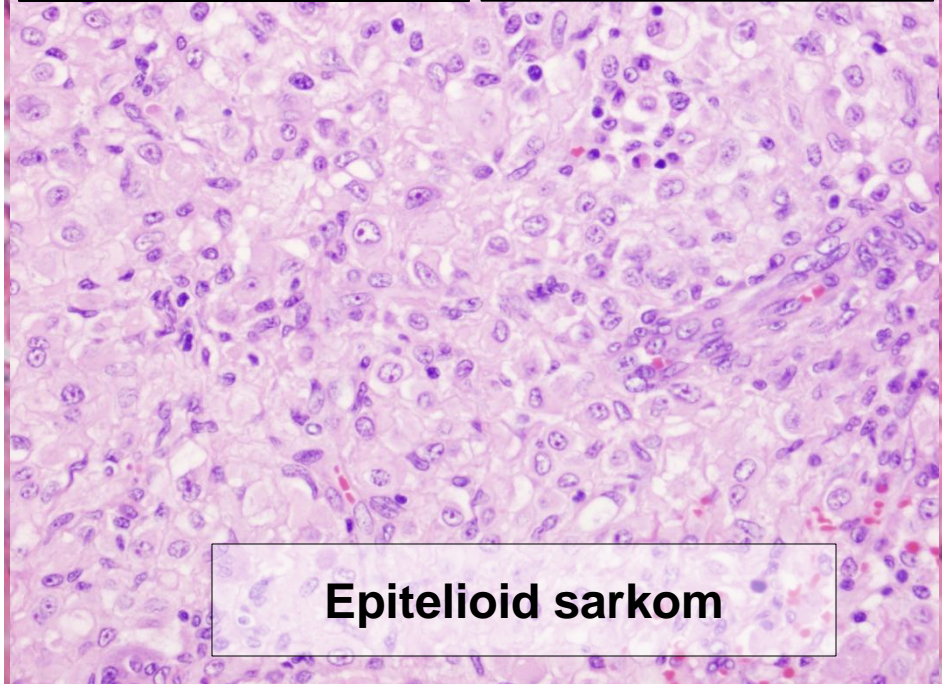
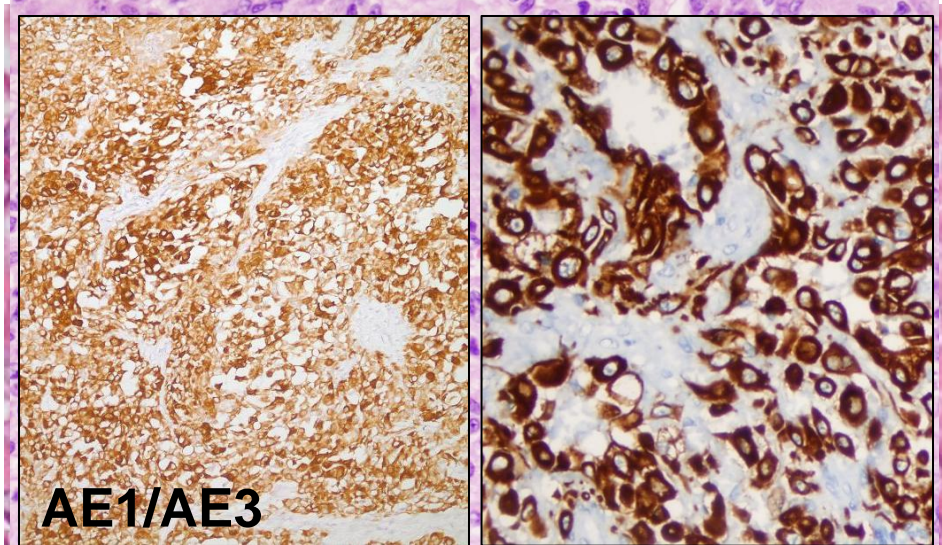
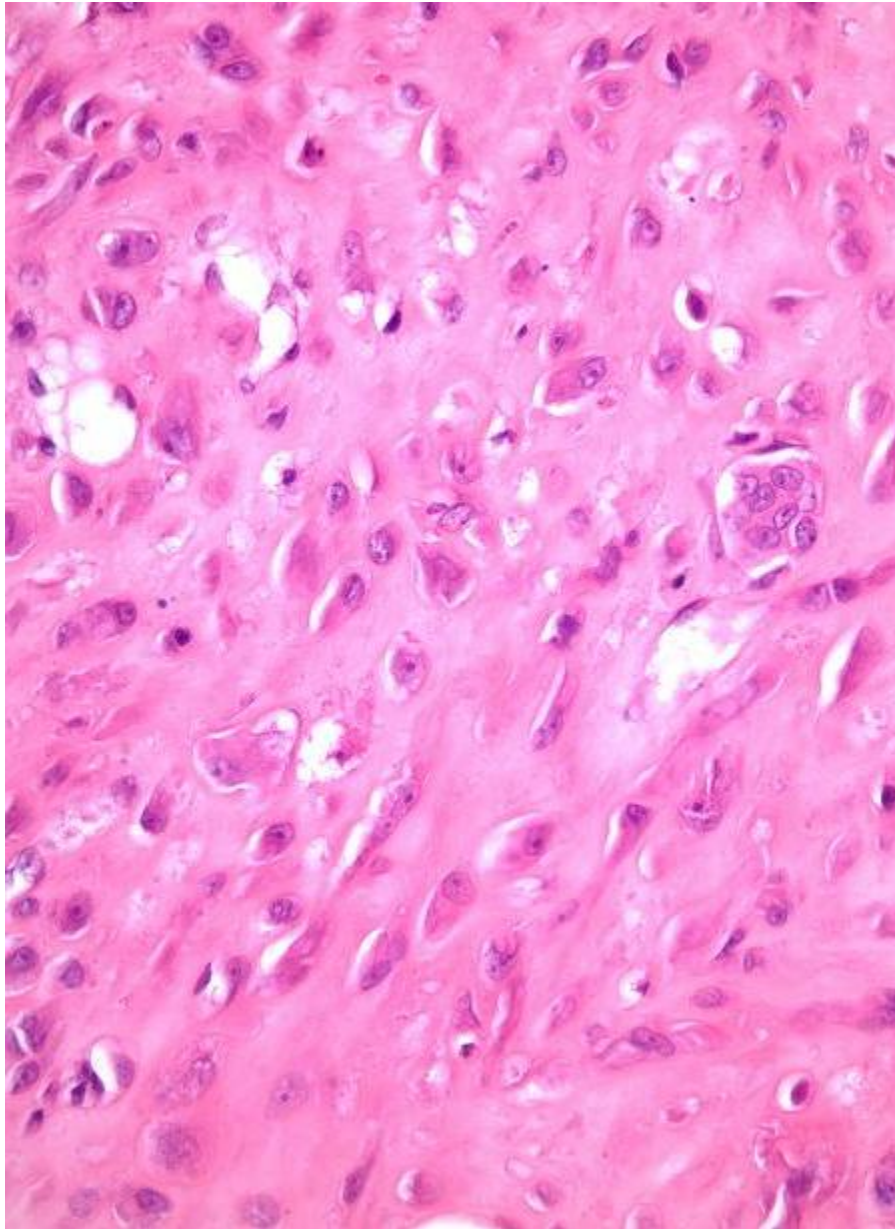
- Nodüler fasiit bulguları + bazofilik sitoplazmalı, ekzantrik nükleuslu, belirgin nükleollü ganglion benzeri myofibroblastlar



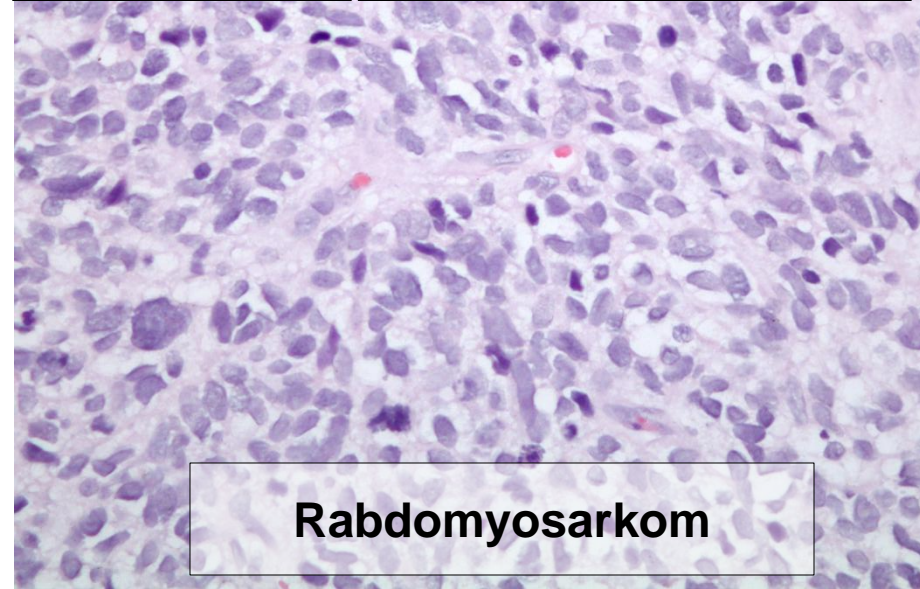
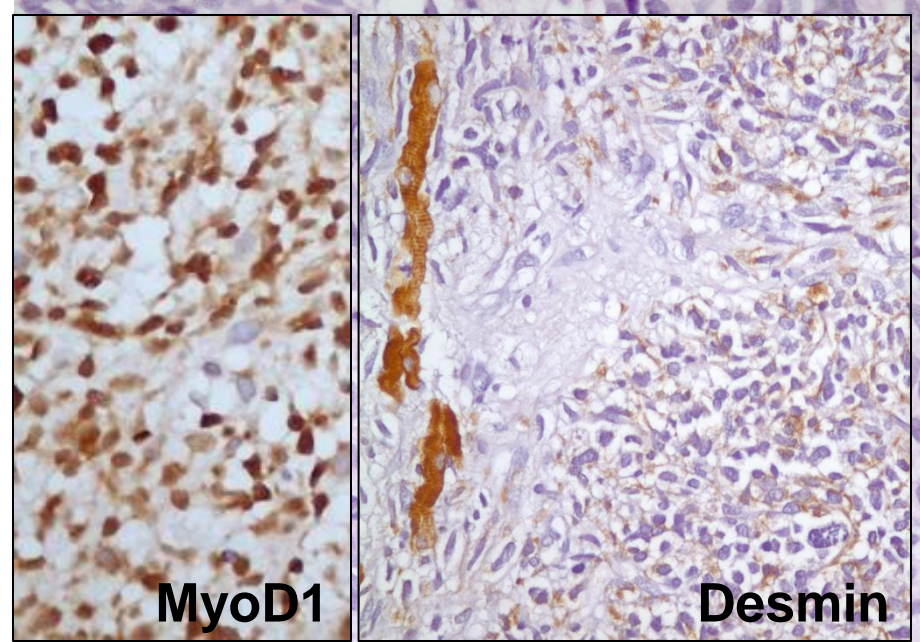
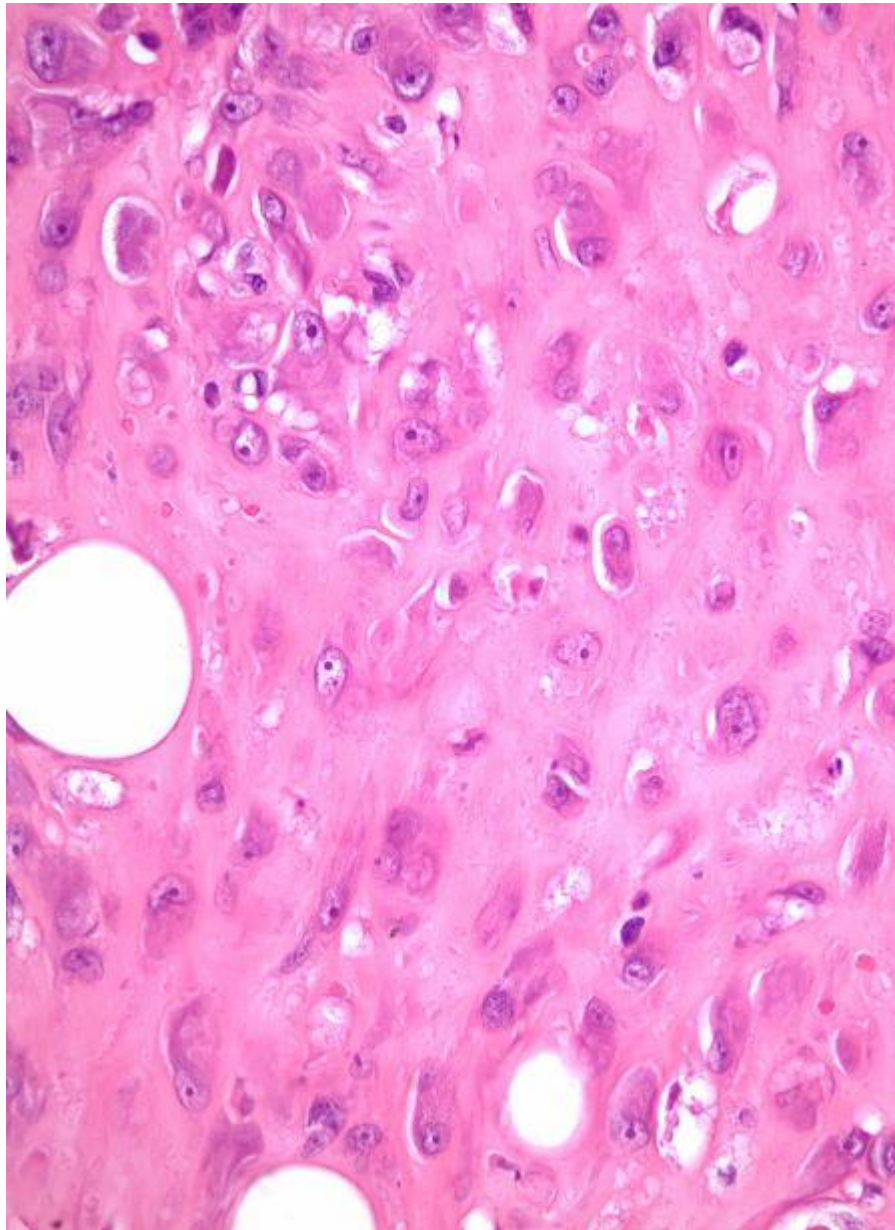
Proliferatif fasiit/myozit

Ddx

- Epitelioid sarkom
- Rabdomyosarkom



Epitelioid sarkom

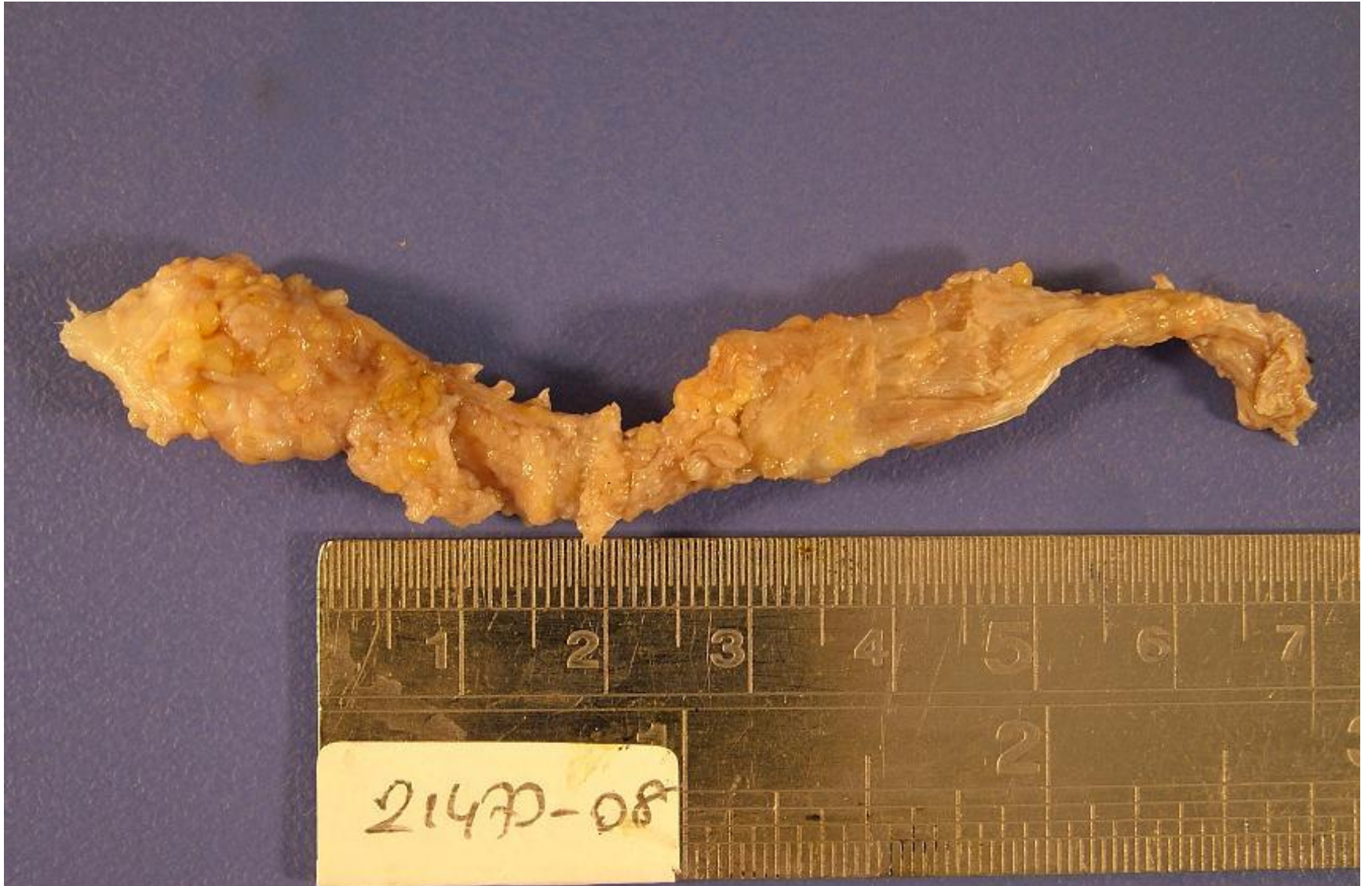

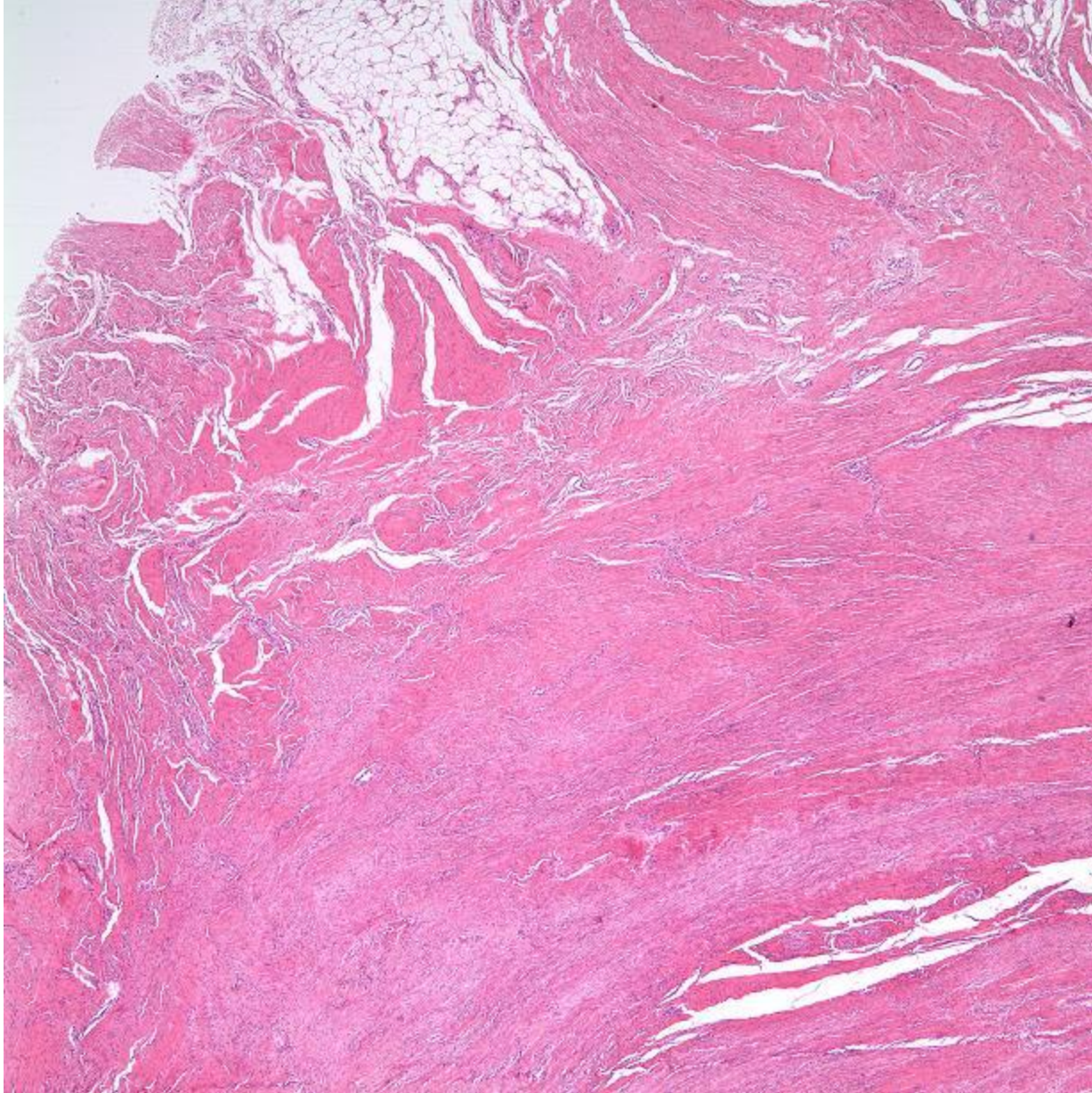
Rabdomyosarkom

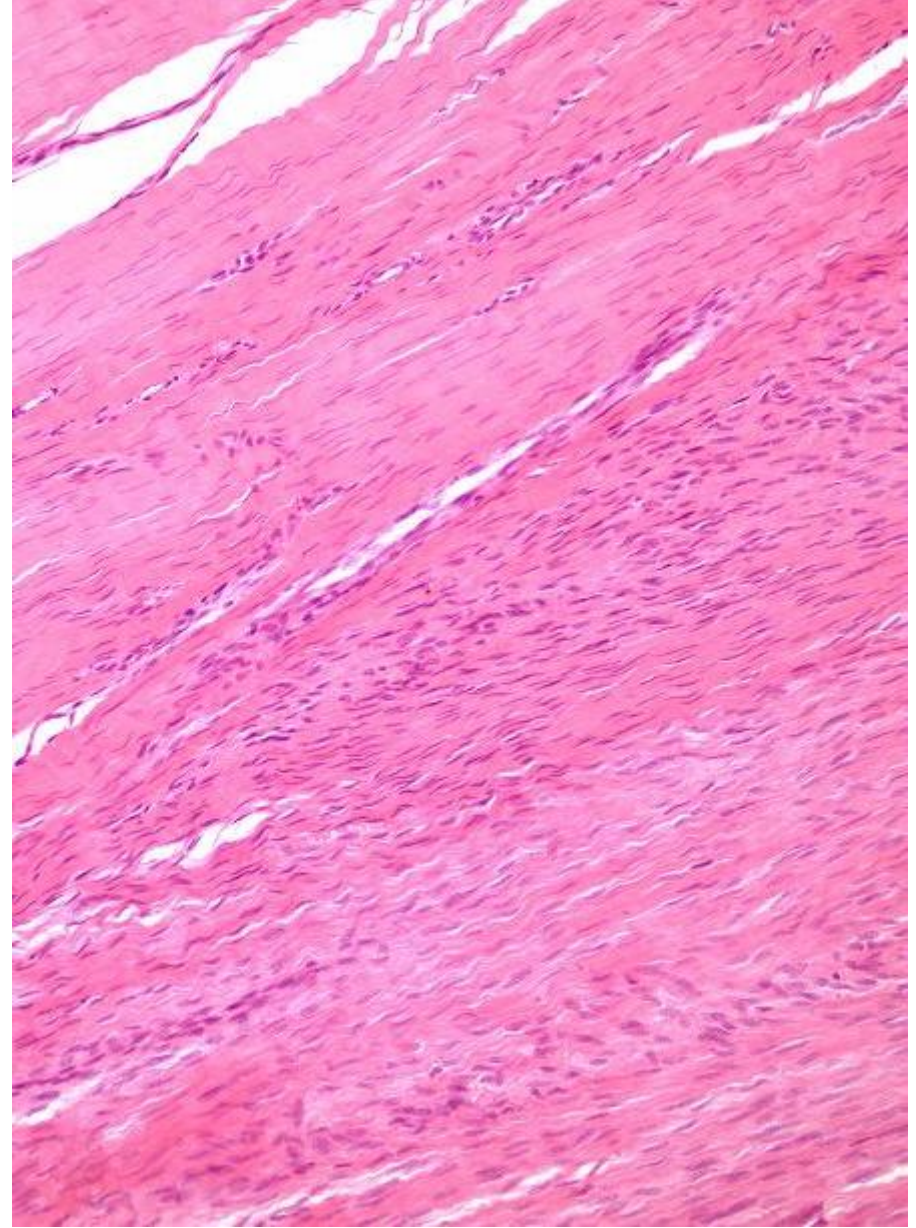
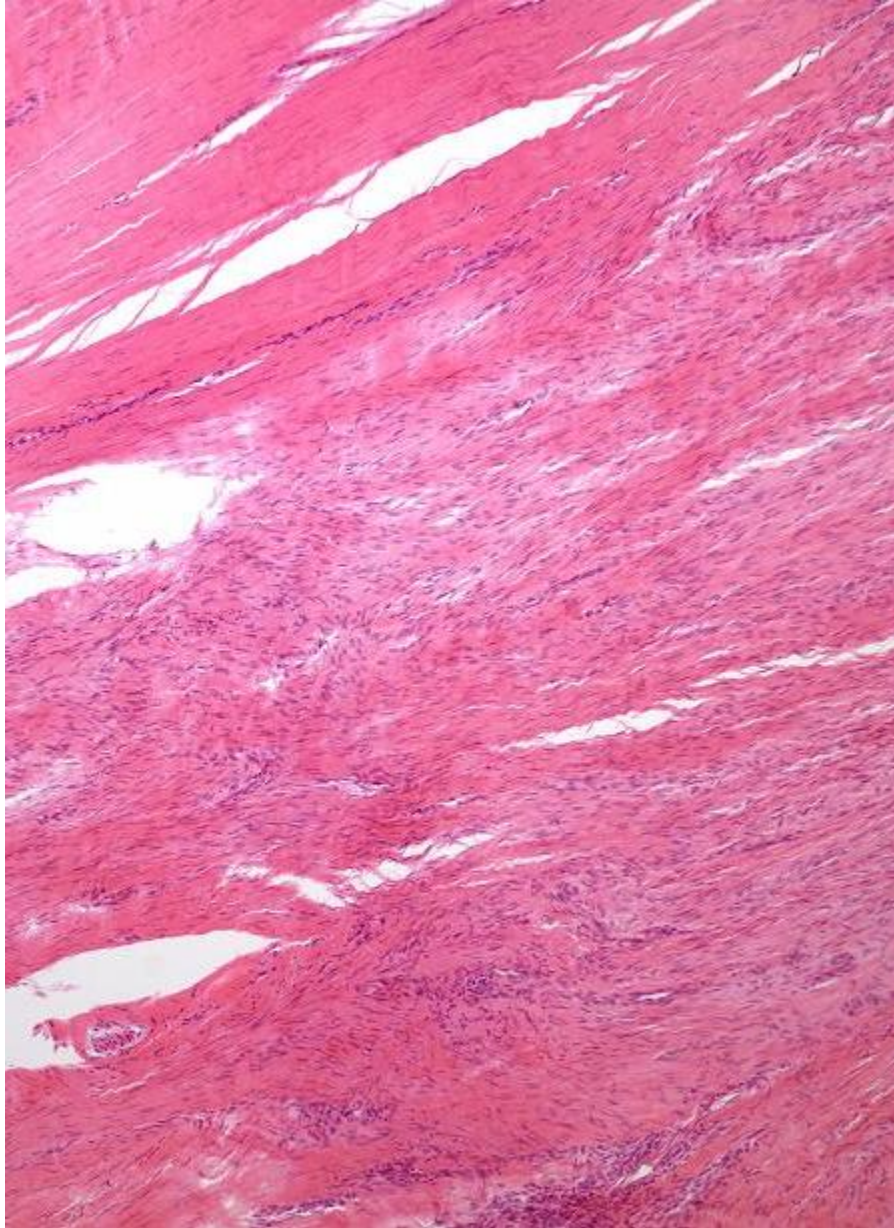
Olgu 3

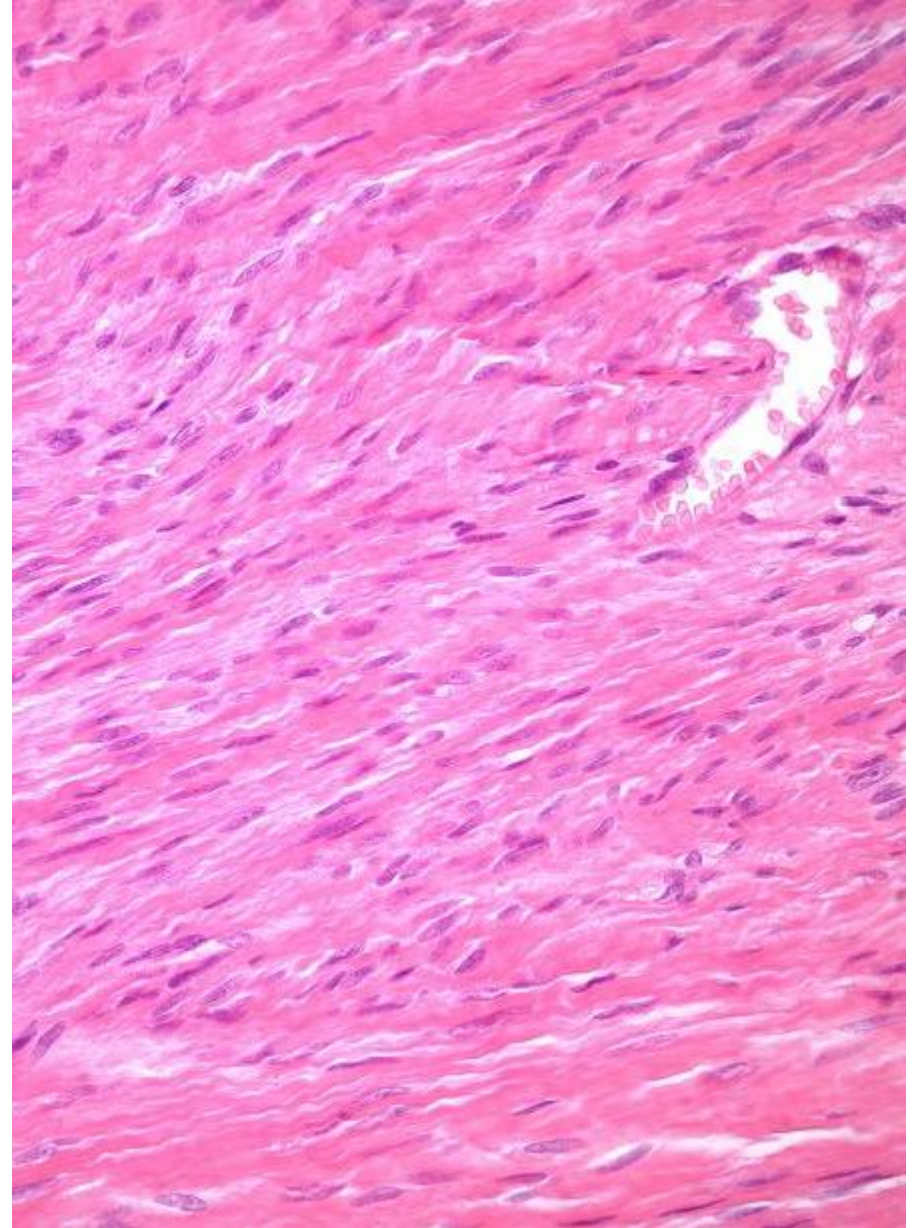
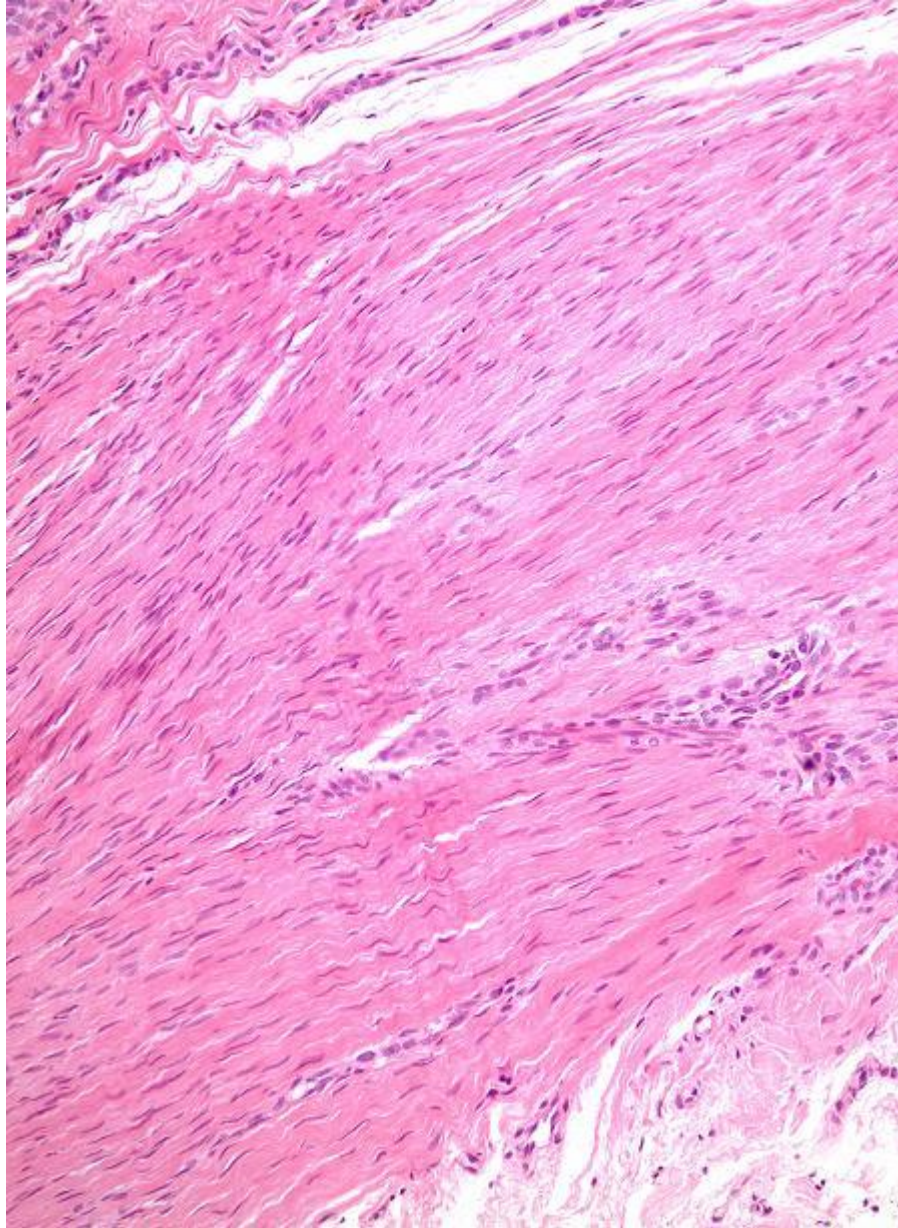
40 y ♂

El palmar yüzde çekinti









TANI:

**Yüzeyel fibromatozis
(Dupuytren Kontraktürü)**

Yüzeyel Fibromatozis

İnciler

Klinik

- **Palmar/plantar/penil**
- **Genç erişkin**
 - **Palmar: %50 bilateral, asemptomatik, sert, multinodüler izole kitle, kontraktür**
 - **Plantar: yürüyüş ya da ayakta kalma ile ortaya çıkan ağrı**

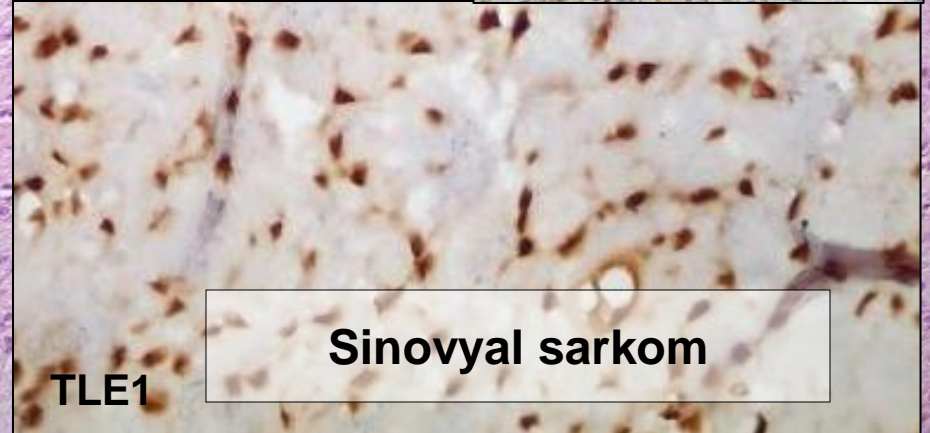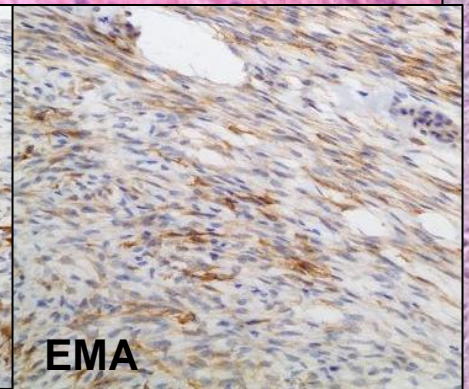
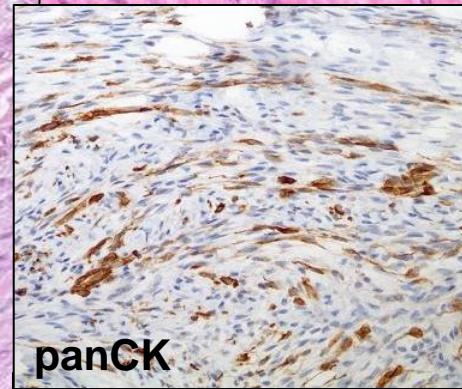
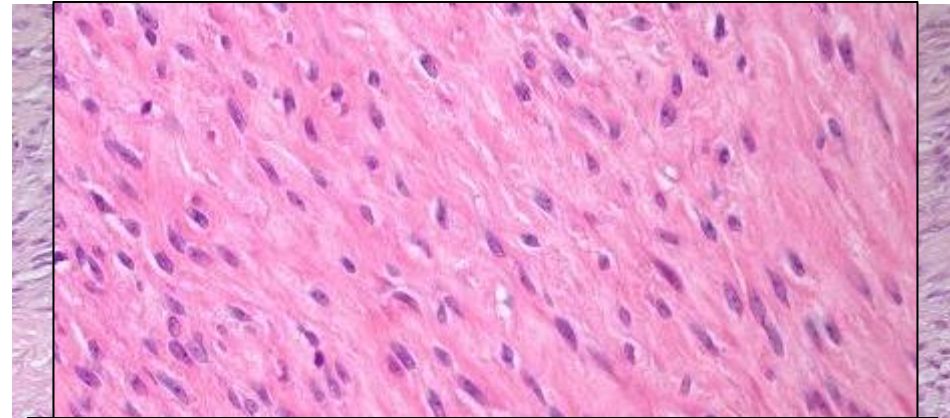
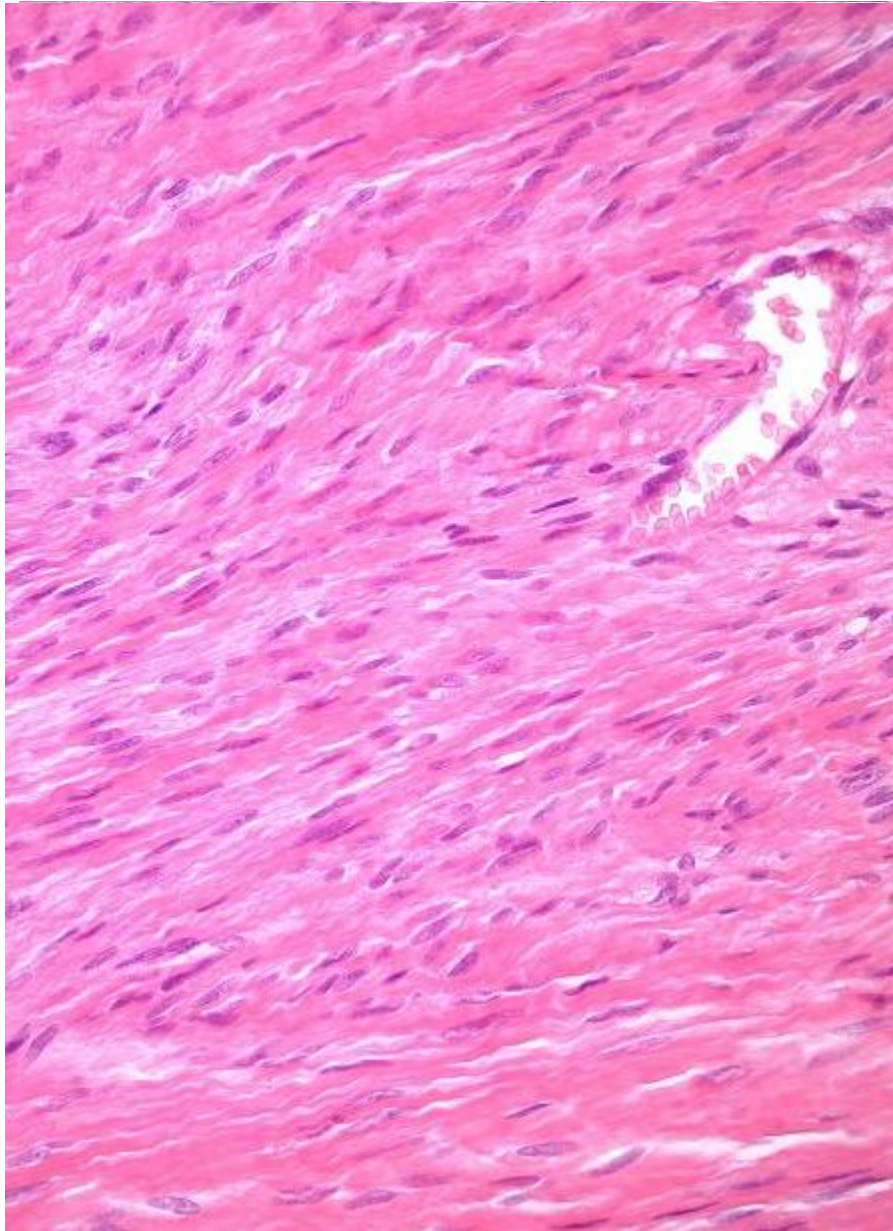
Morfoloji

- **Lezyon yaşına bağlı**
- **Aponöroz ve tendonların çevresinde**
- **Subkütan yerleşimli, multinodüler**
- **İmmatür fibroblastik proliferasyon**

Yüzeyel Fibromatozis

DDx

- **Monofazik sinovyal sarkom**
- **Tendon kılıfının fibromu**
- **Fibrosarkom**

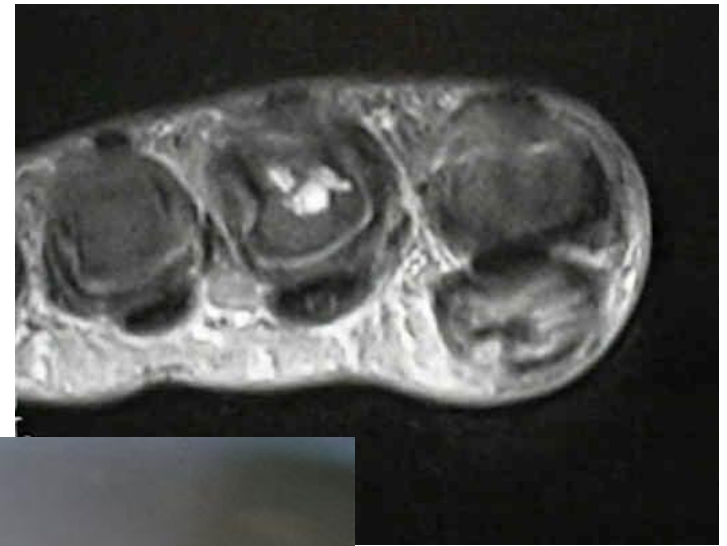
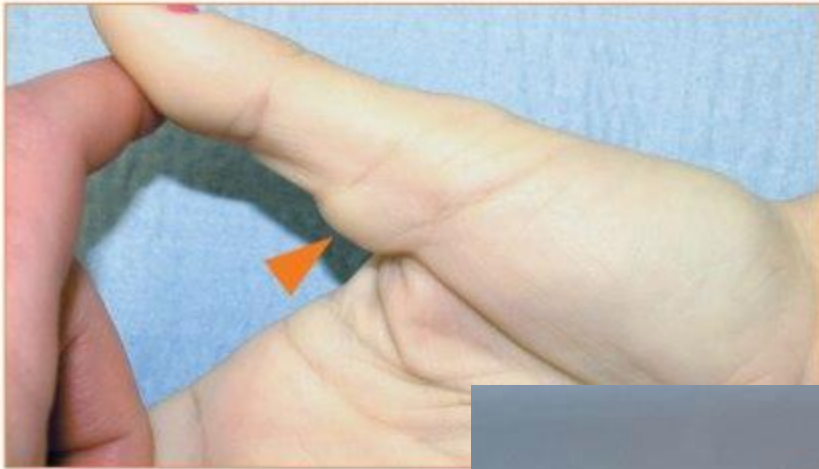


Sinovyal sarkom

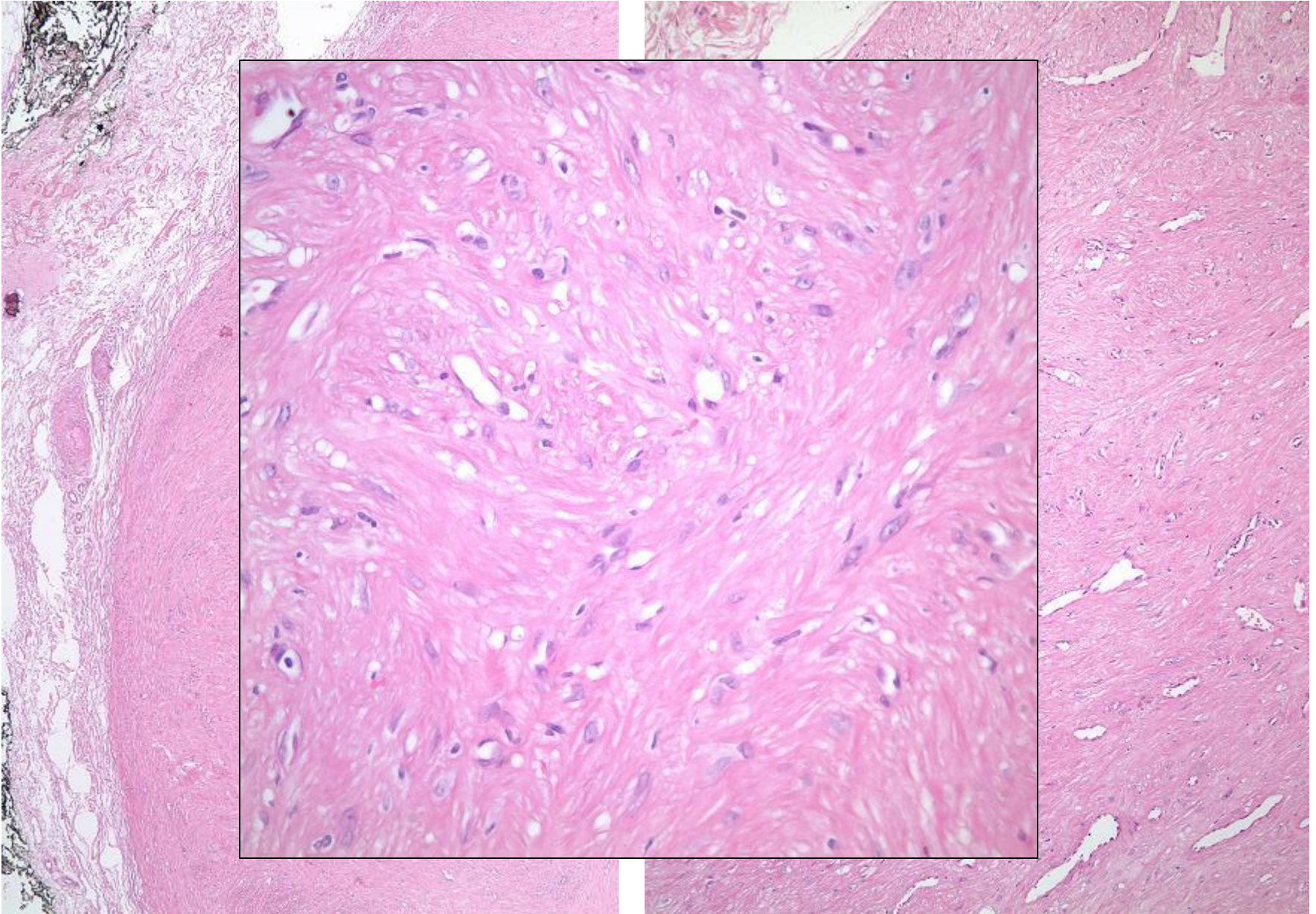
TLE1

TLE1

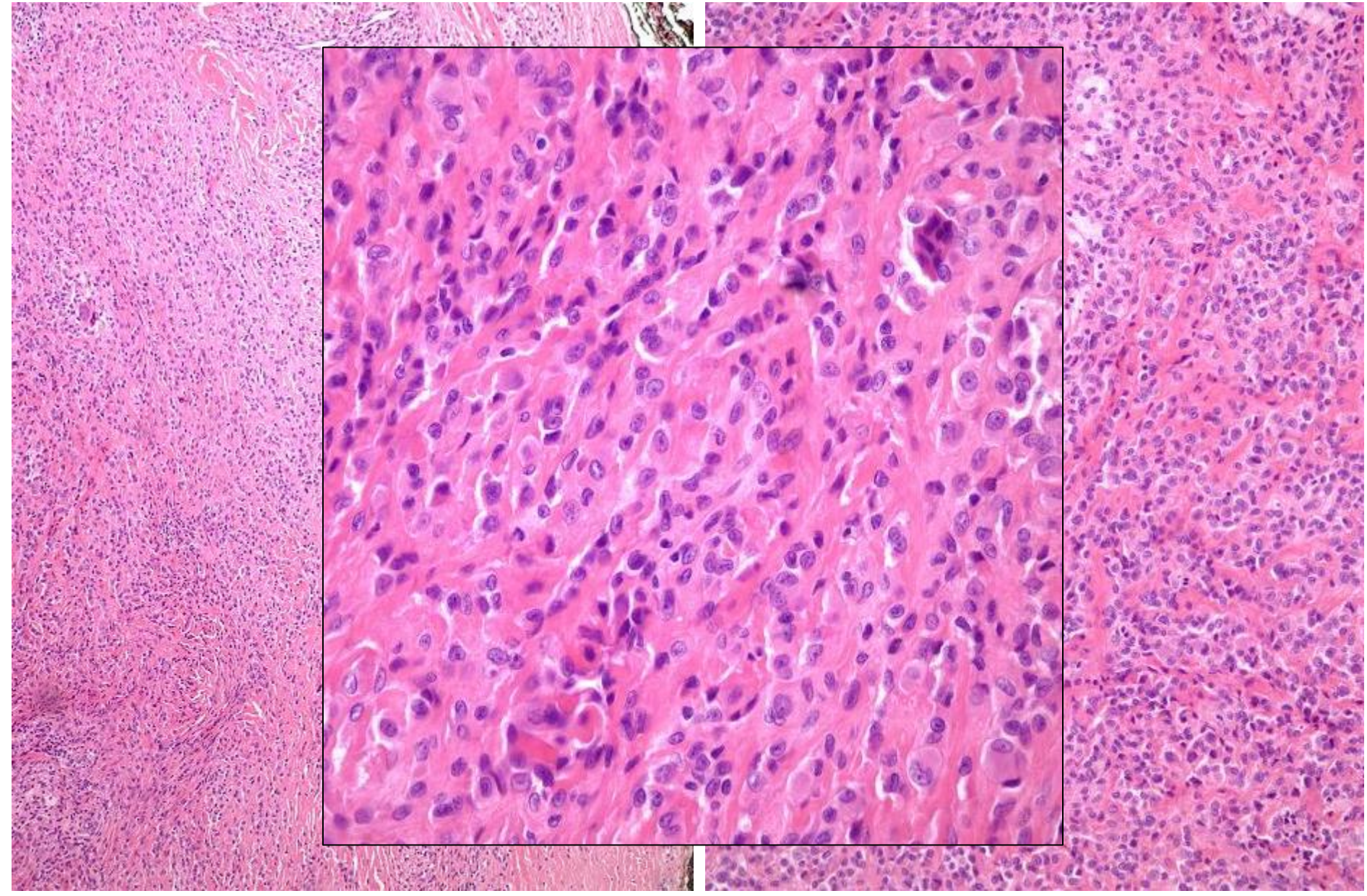
- ***TLE* gen ailesinin üyesi**
- **Hematopoez kontrolü, nöronal diferansiasyon ve terminal epitelyal diferansiasyon**
- **Wnt/ β -catenin sinyal yolağı ile ilişkili**
- **Sinovyal sarkom için sensitivitesi %85-97
spesifitesi %75!**



Tendon kılıfının fibromu



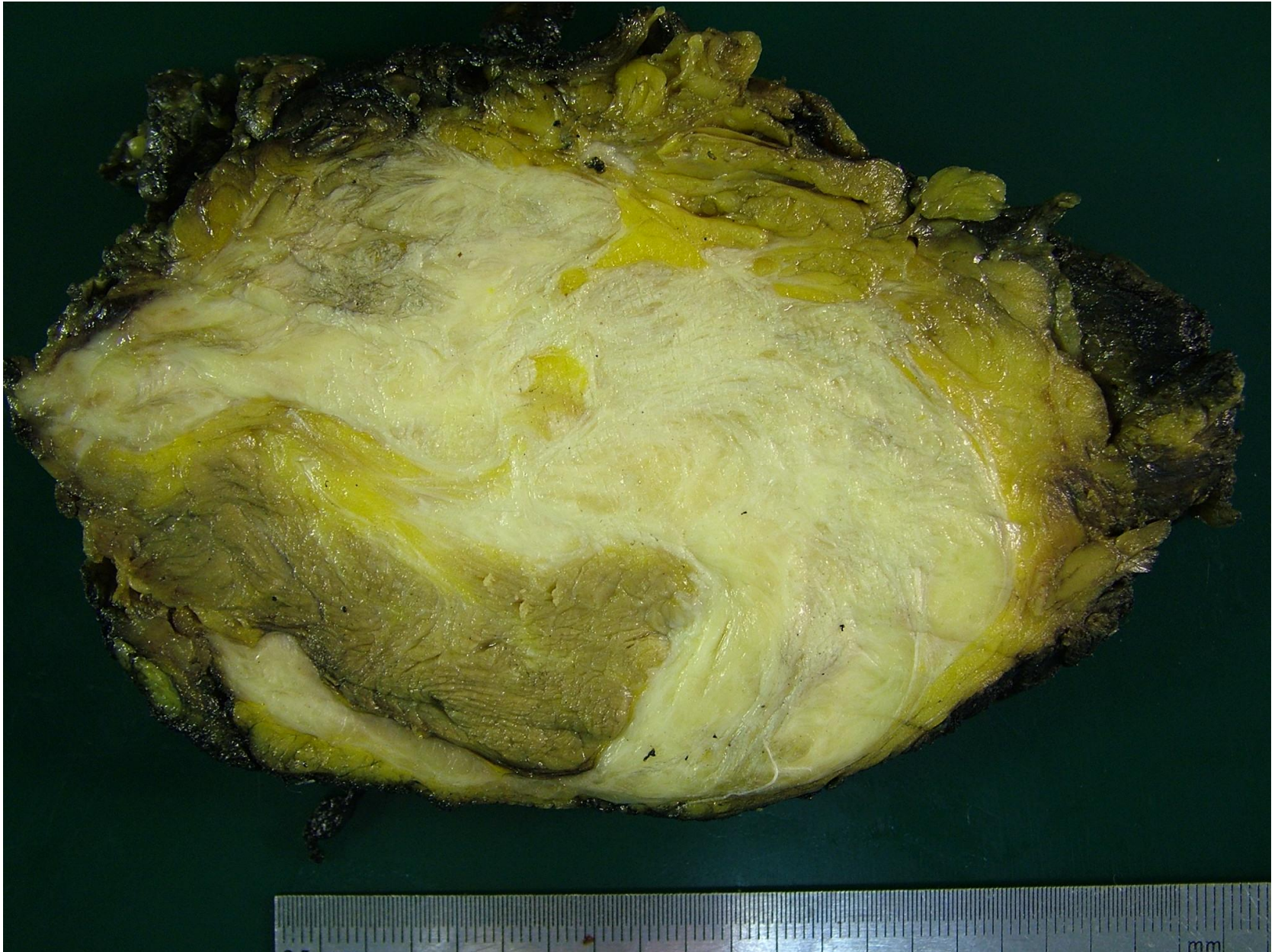
Tendon kılıfının dev hücreli tümörü

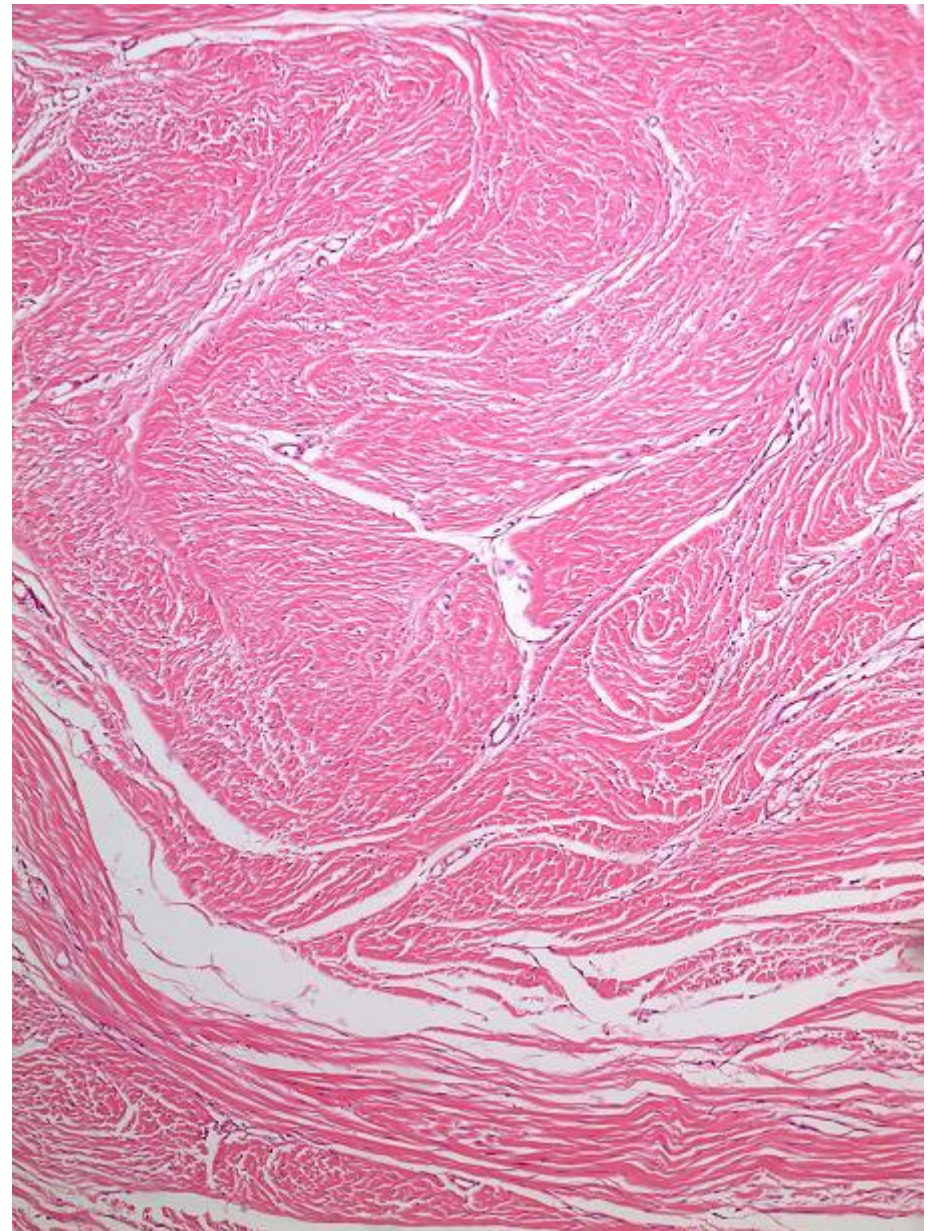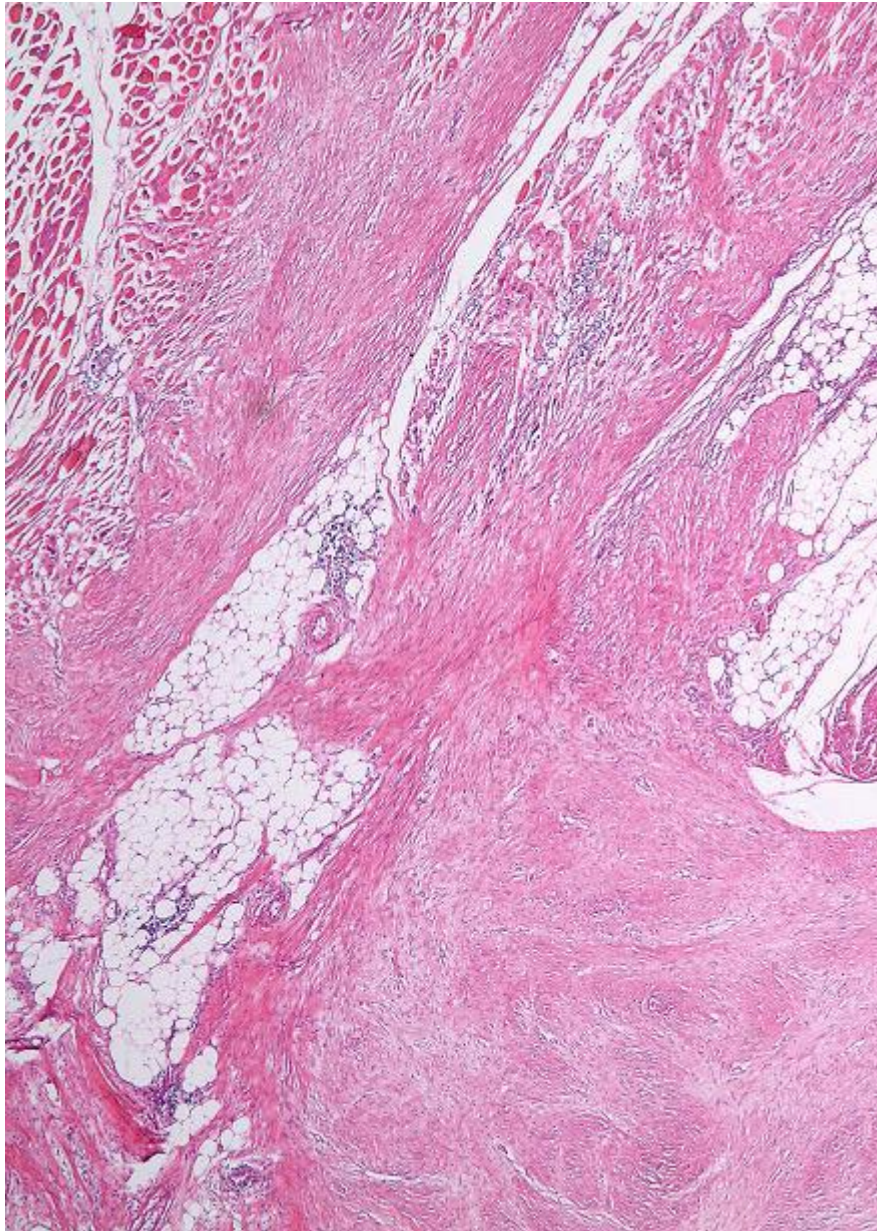


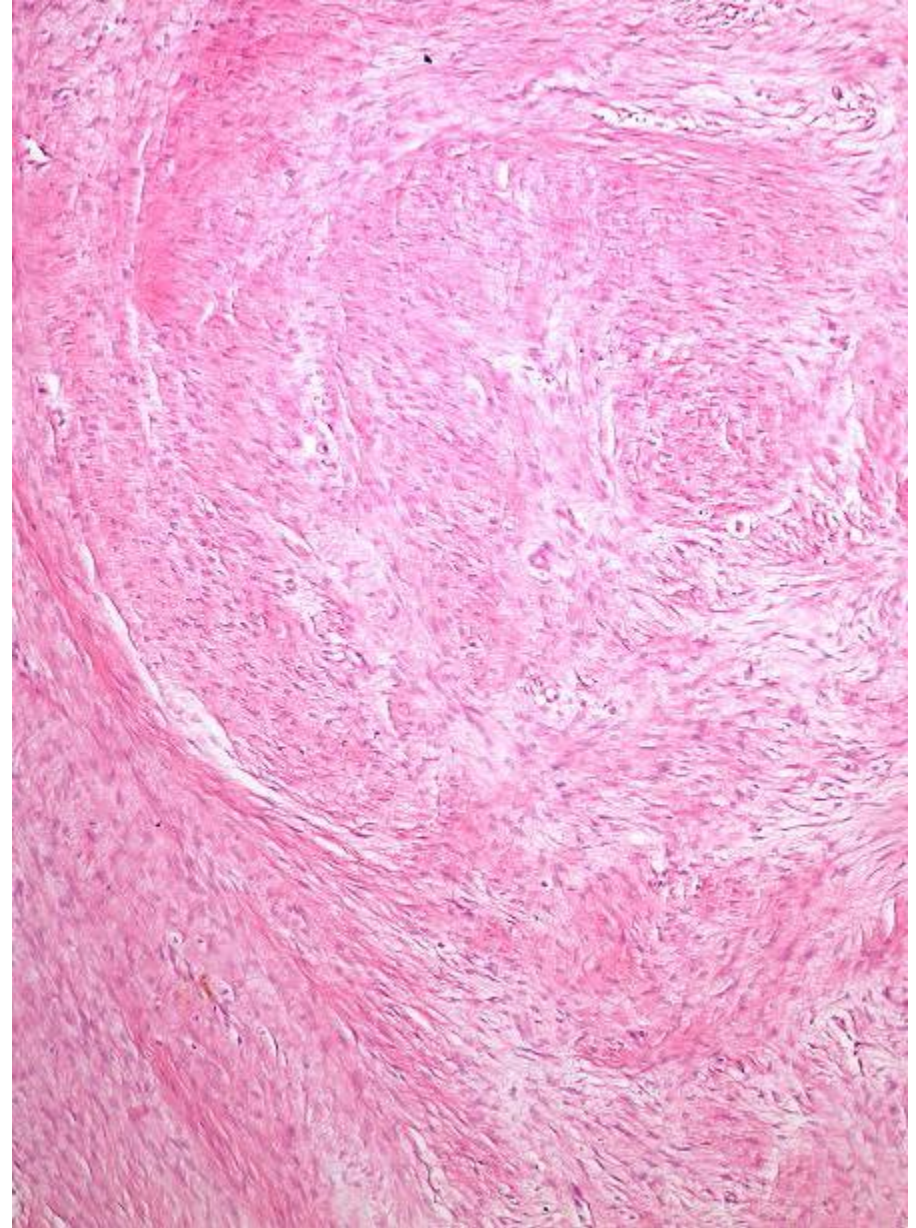
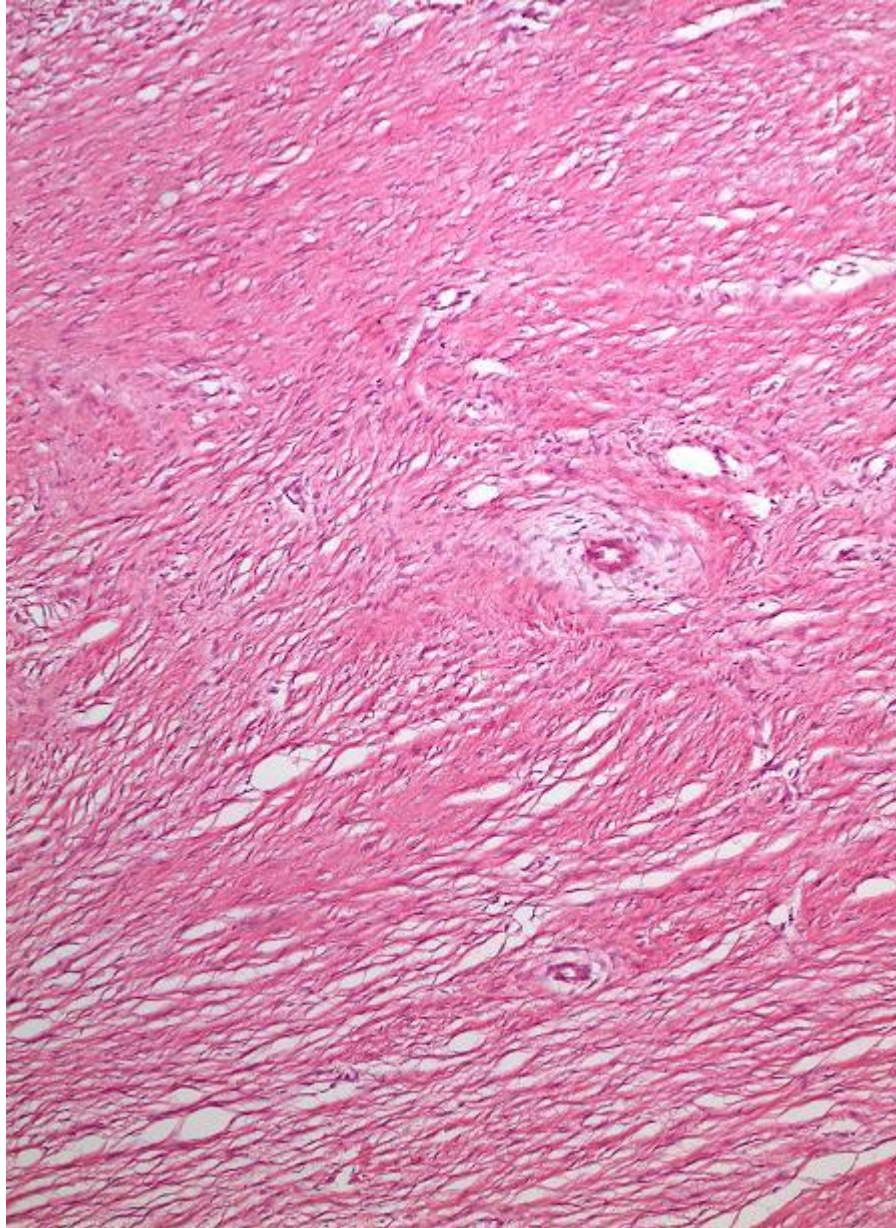
Olgu 4

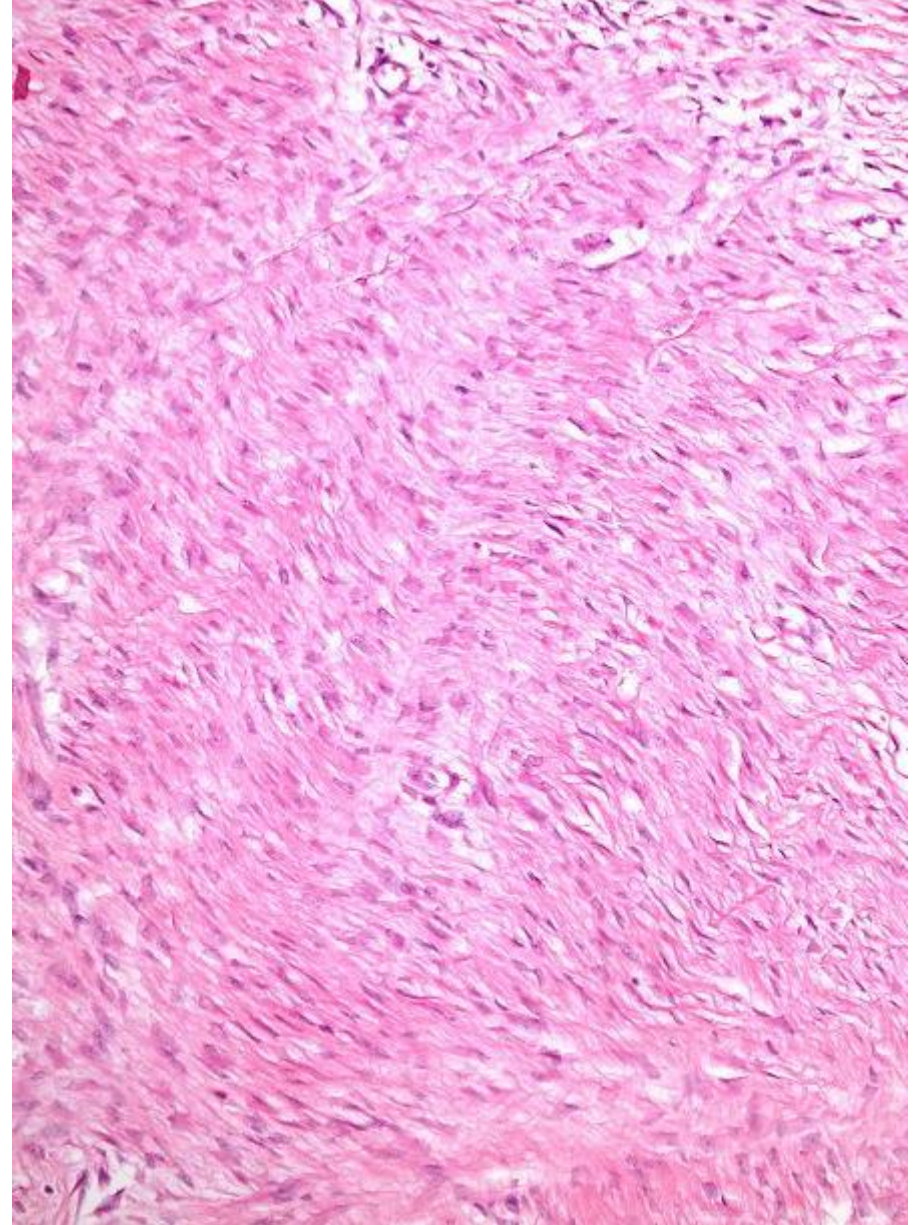
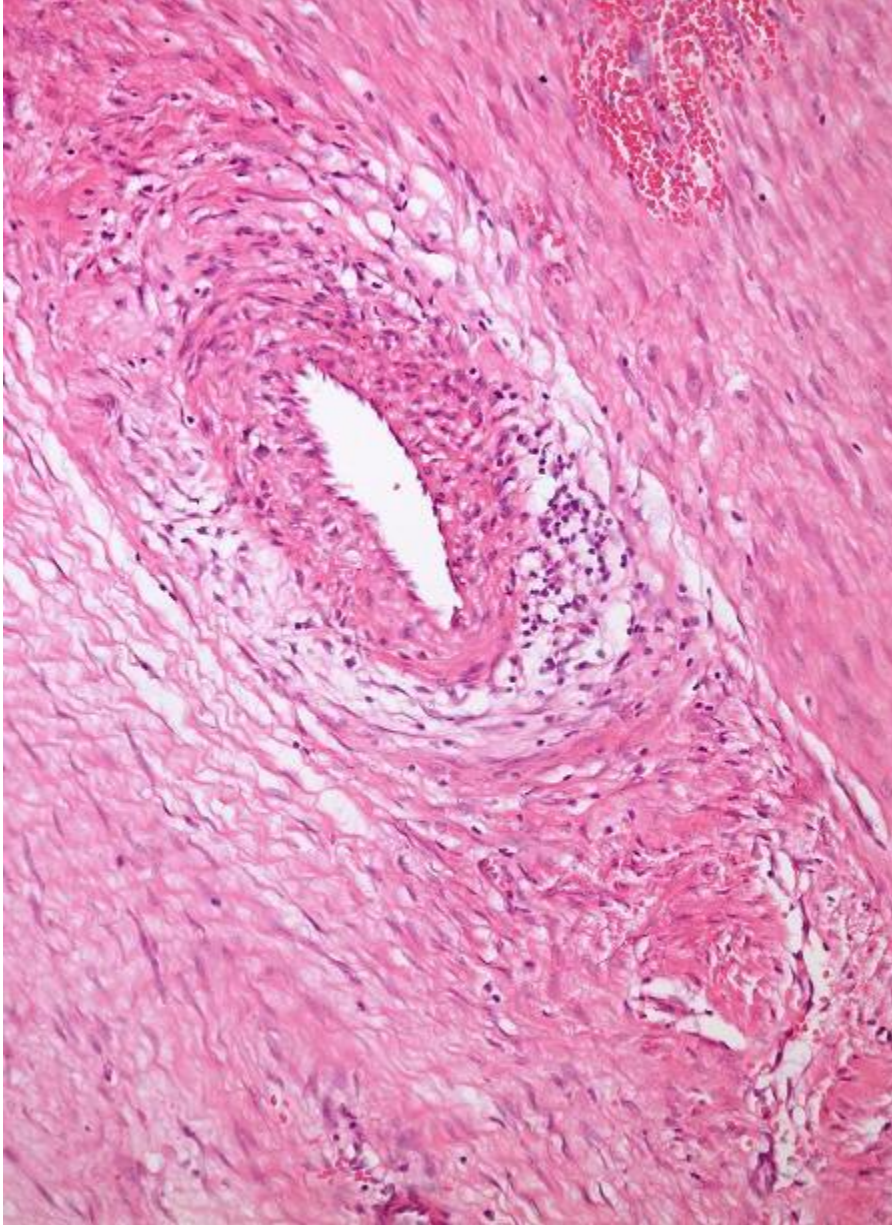
40 ♀

Sağ omuzda kitle









TANI:

**Ekstraabdominal derin
(desmoid) fibromatozis**

Desmoid fibromatosis

İnciler

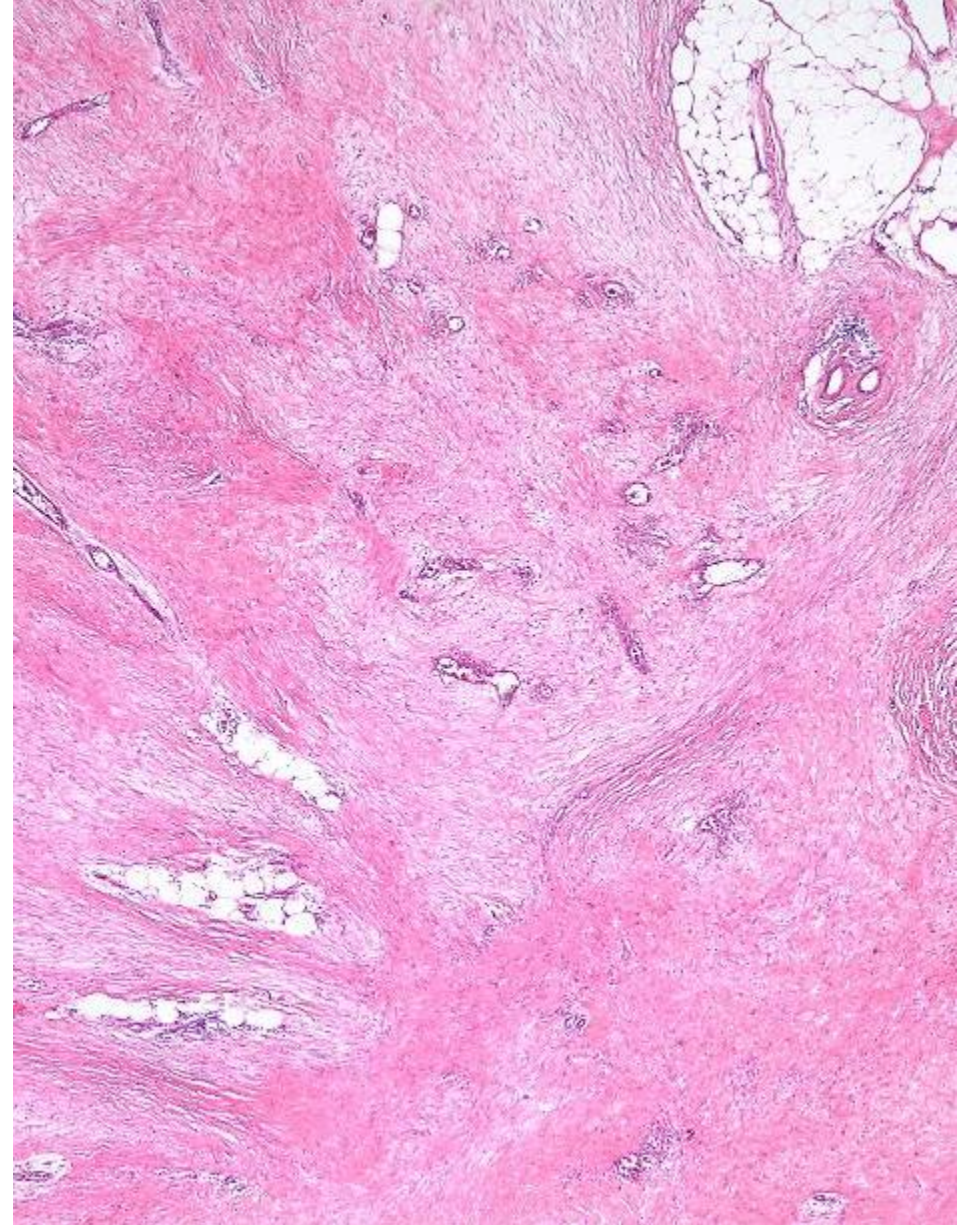
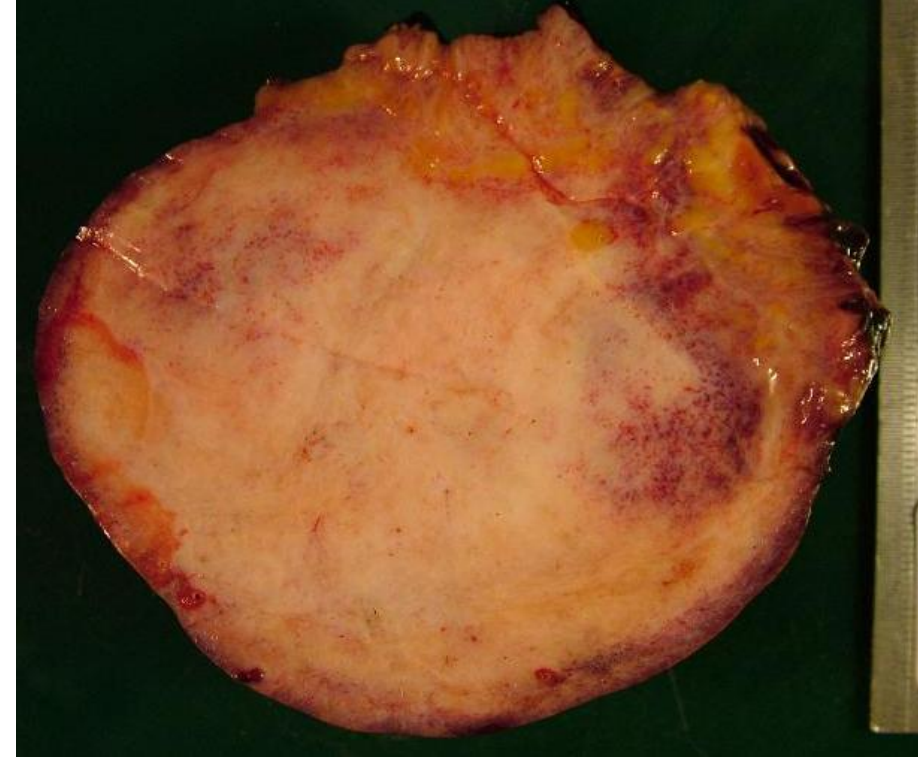Klinik

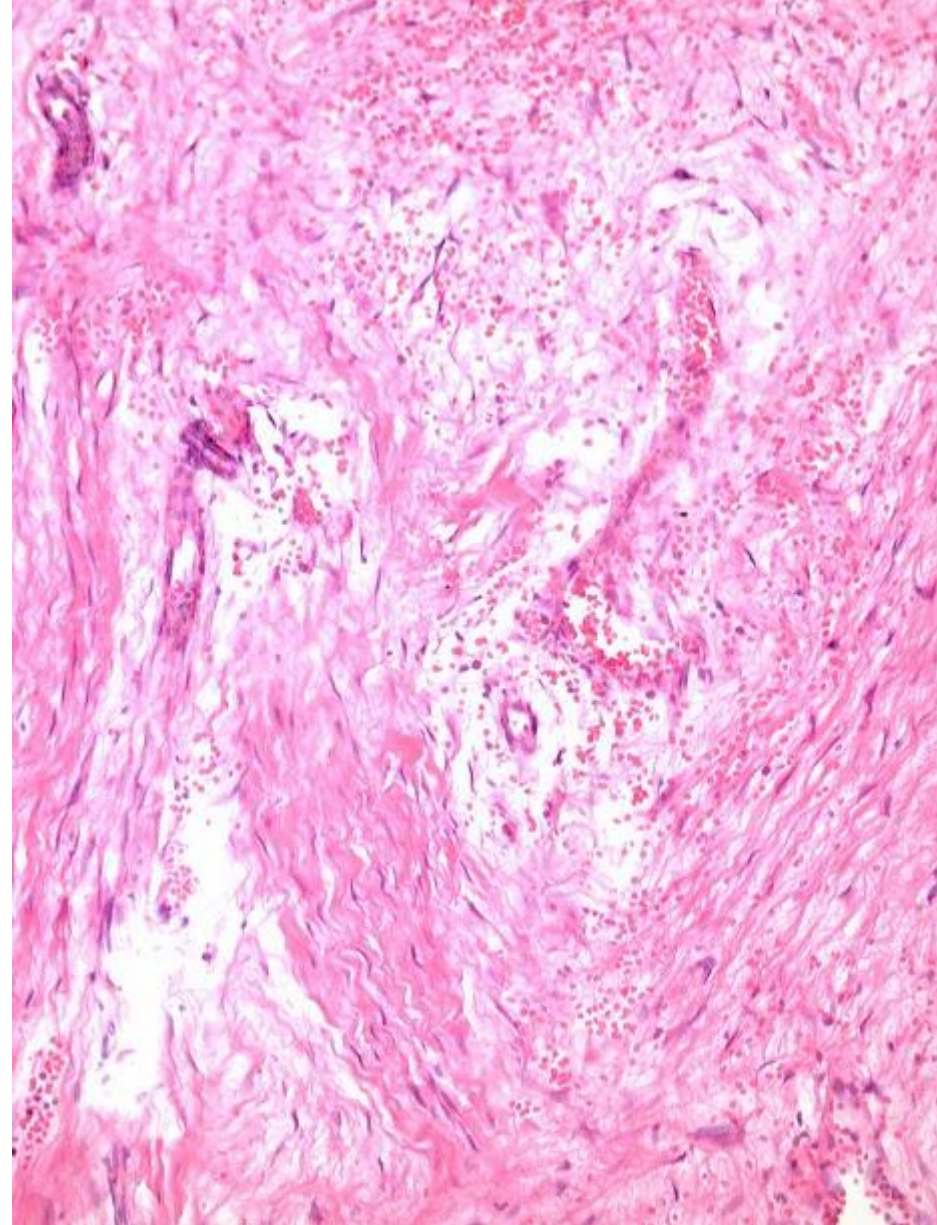
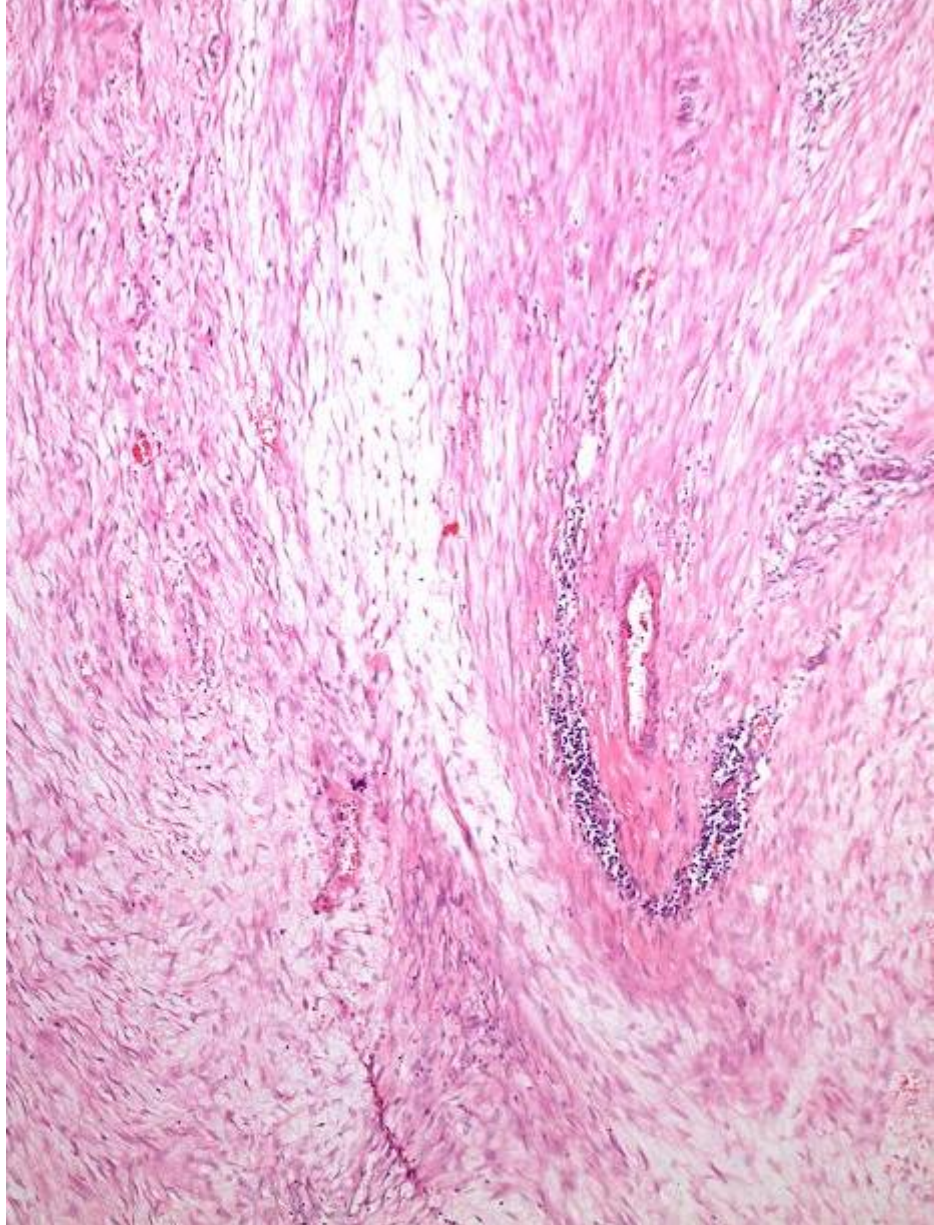
- Omuz
- Ağrısız 5-10 cm kitle

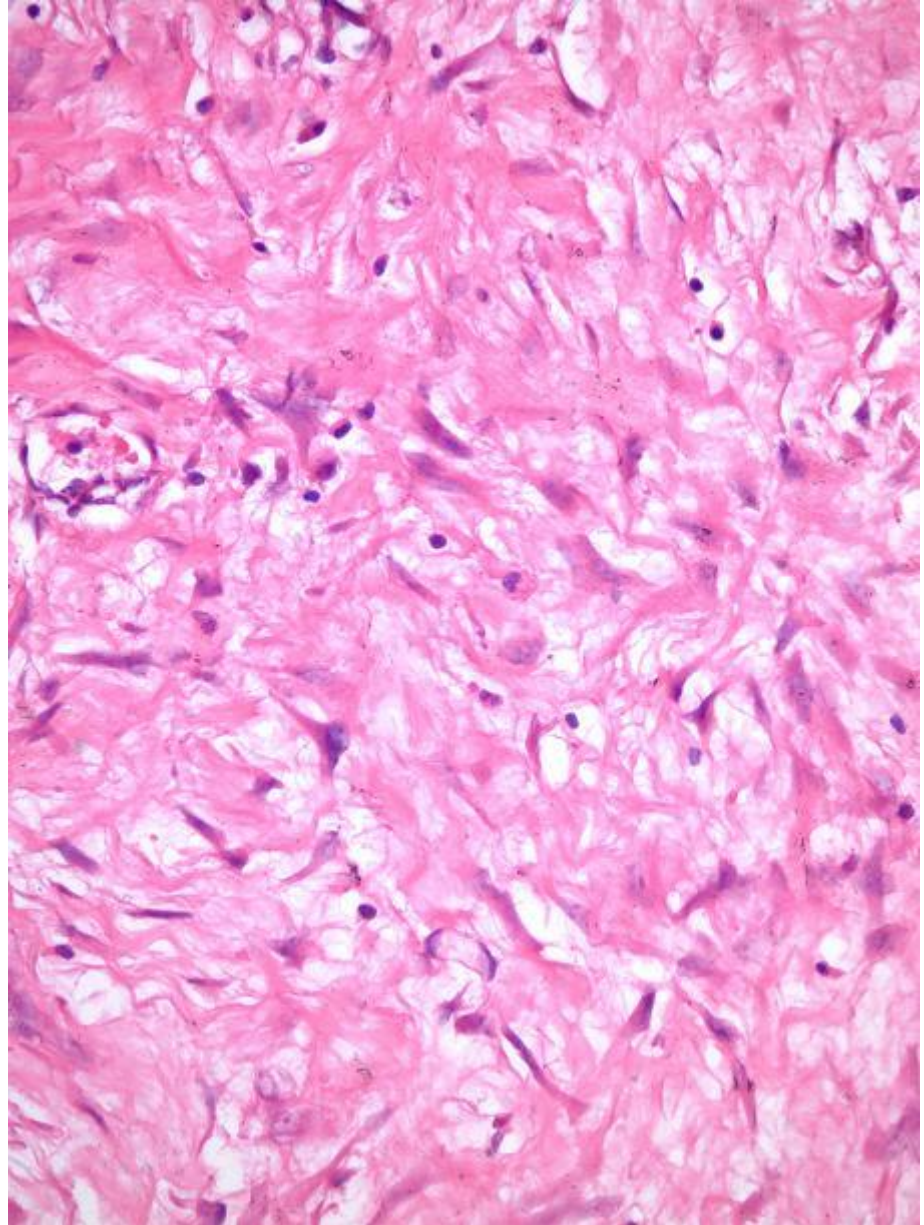
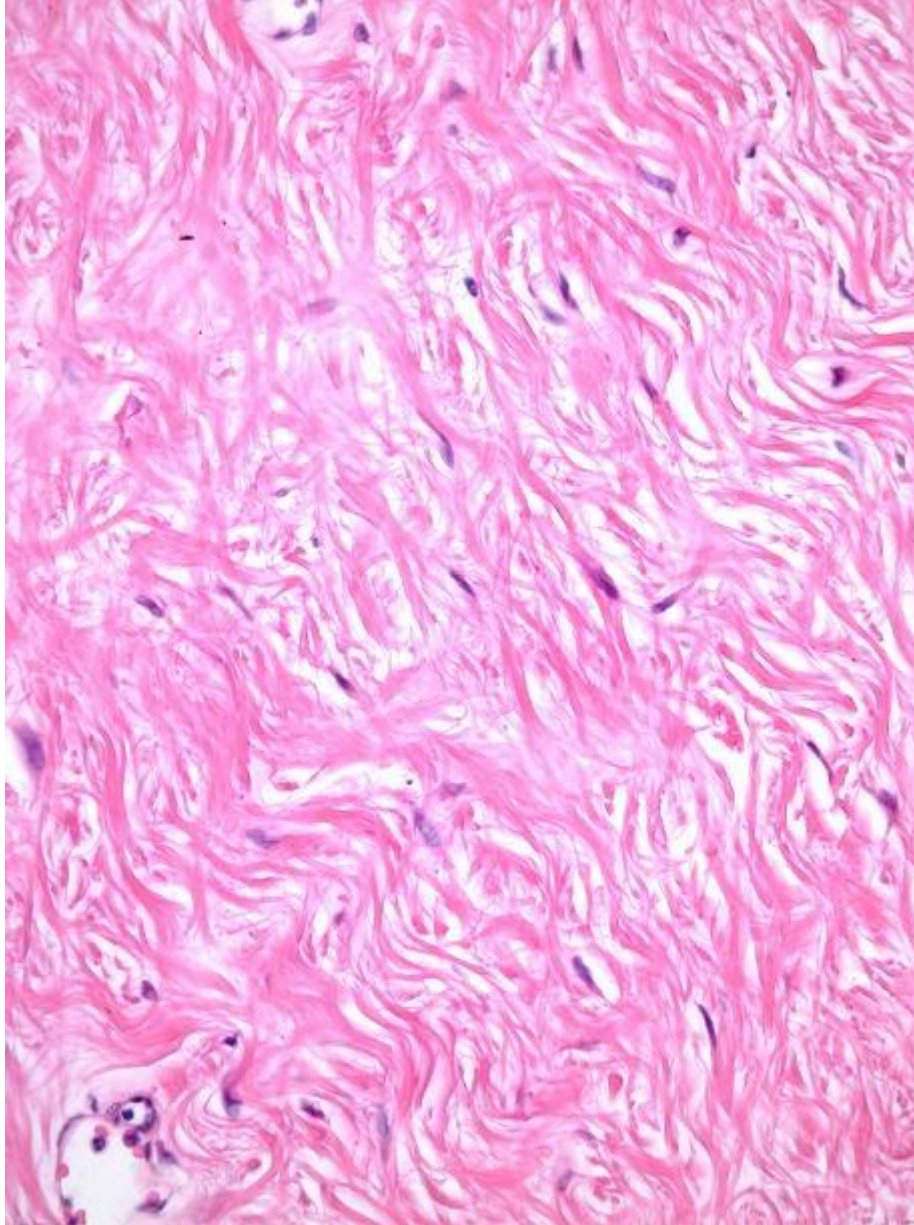
Morfoloji

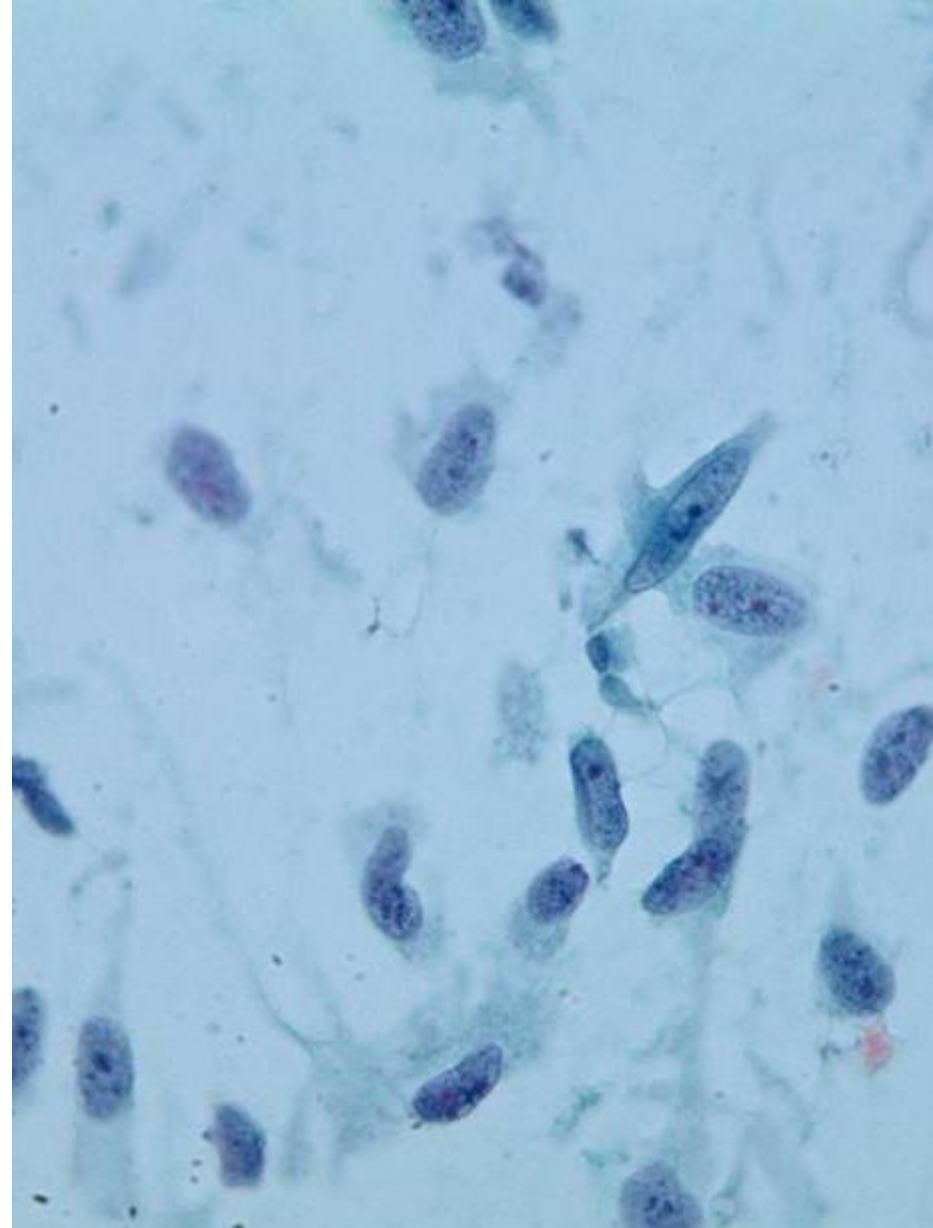
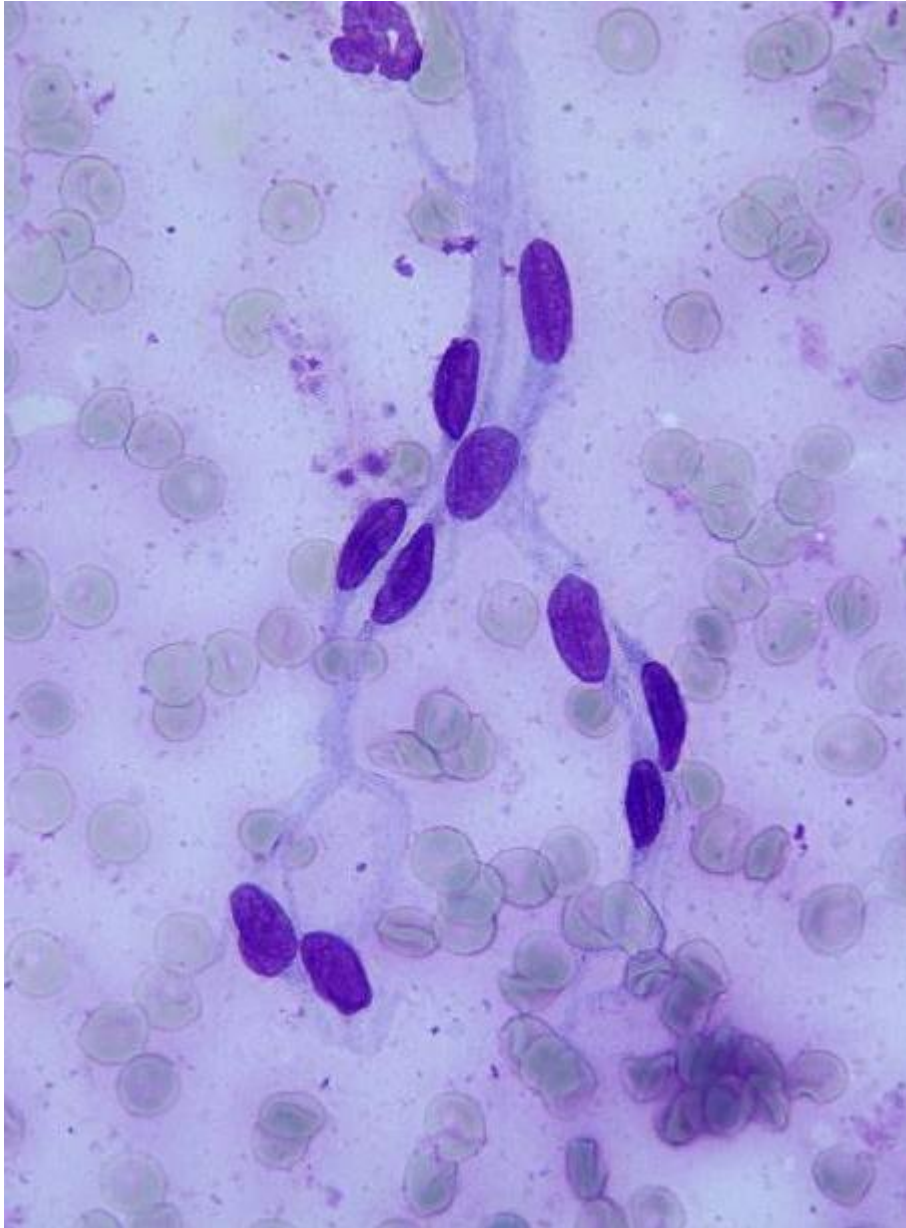- Çevre dokulara infiltrasyon
- Kalın çevresi ödemli damarlar
- Saçılmış lenfositler
- Mitoz Ø

- 30 ♀
- Mezenterik kitle





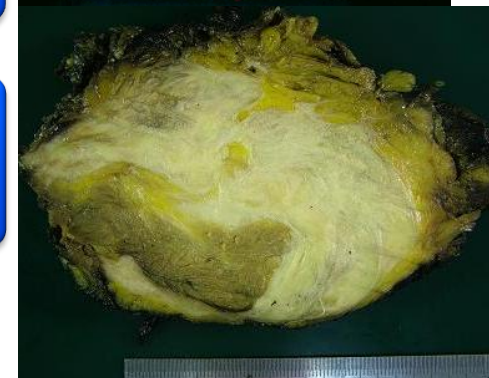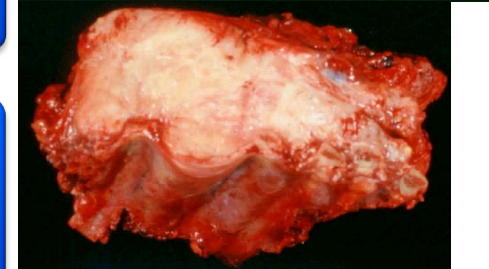
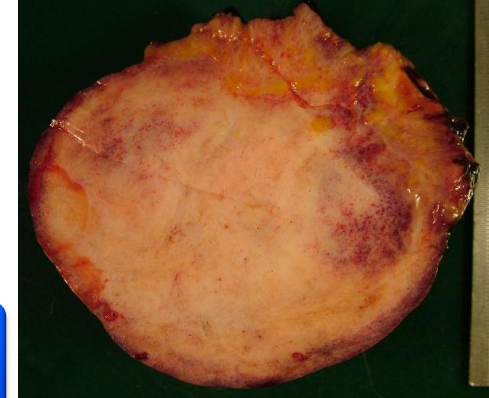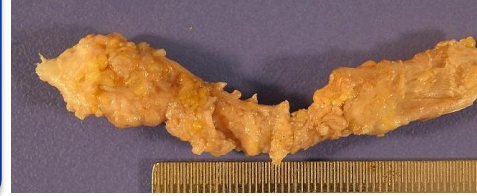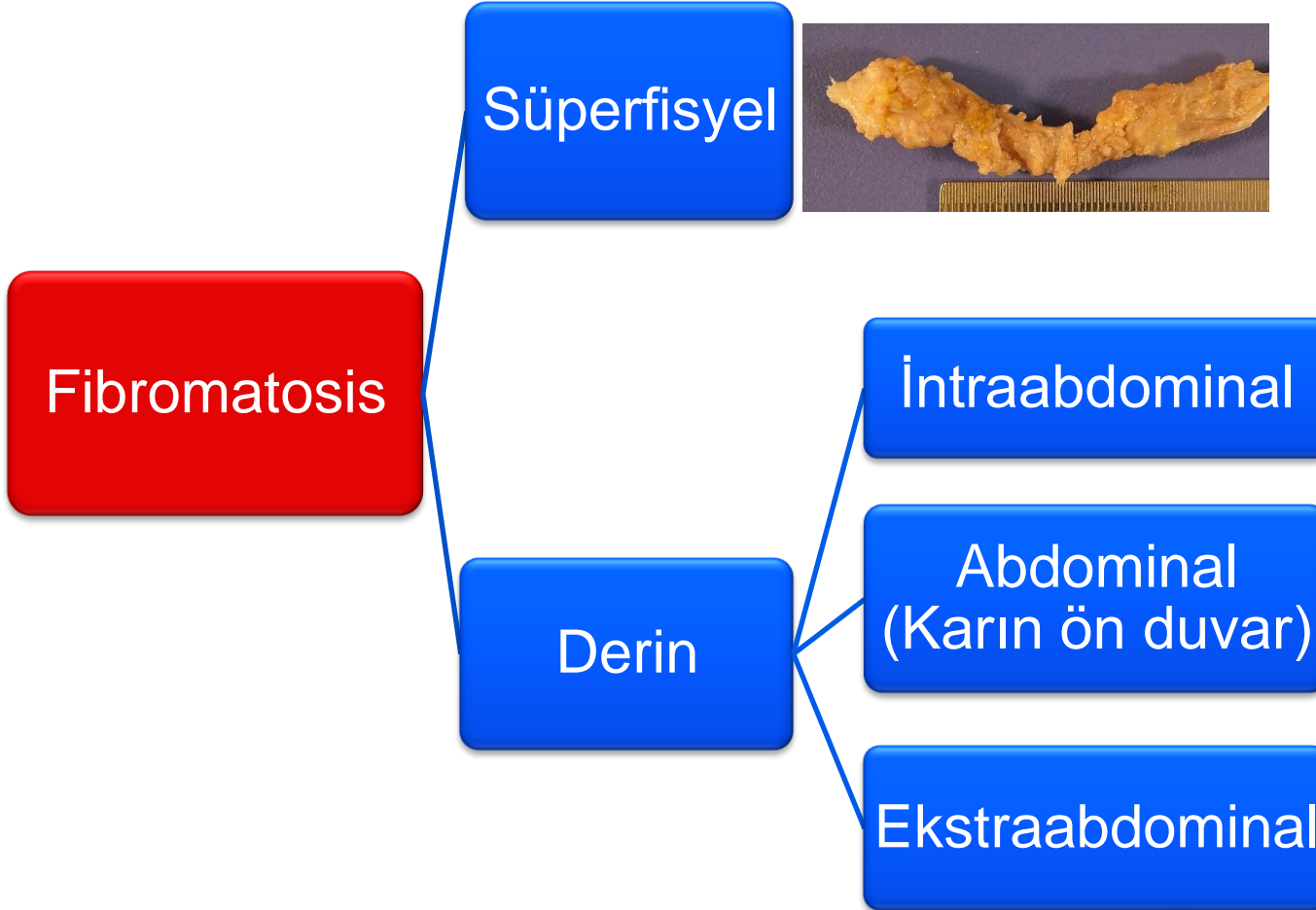




TANI:

**İntraabdominal derin
(desmoid) fibromatozis**

Fibromatosis

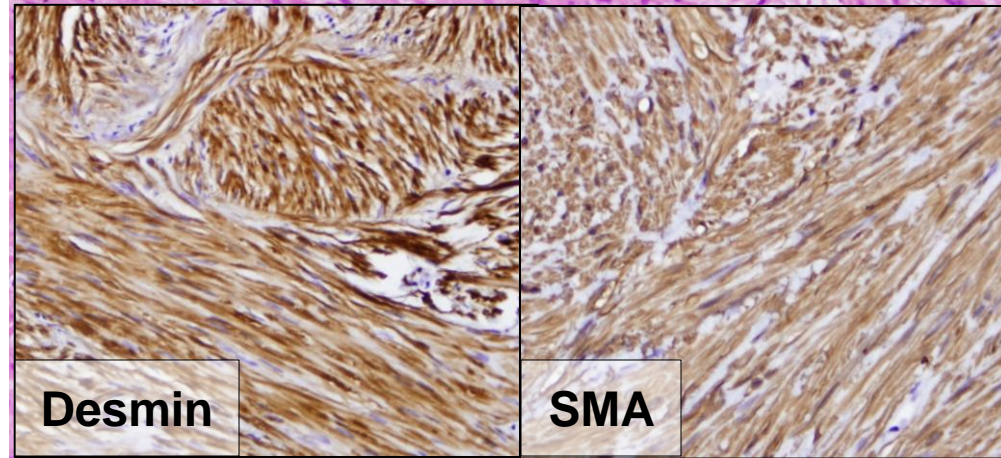
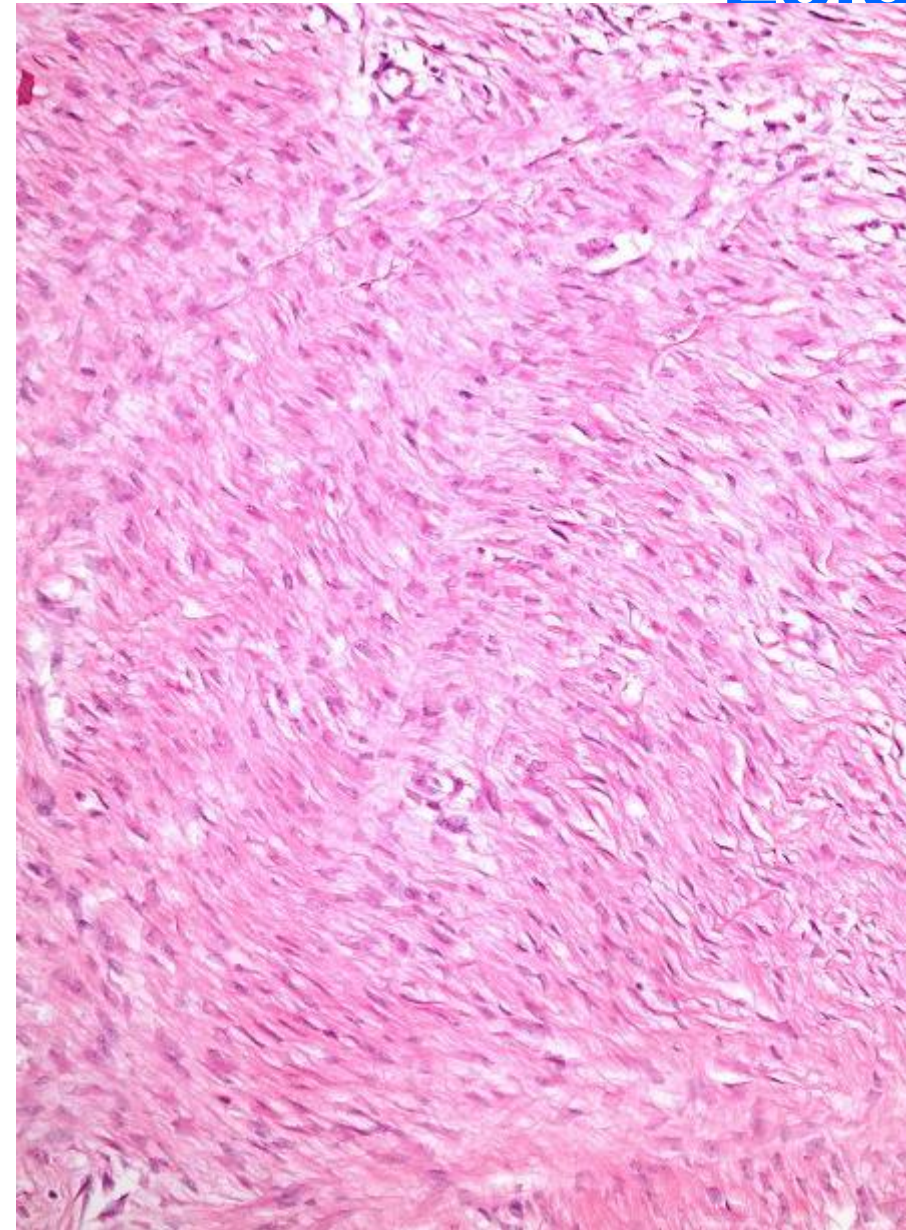


Desmoid fibromatosis

DDx

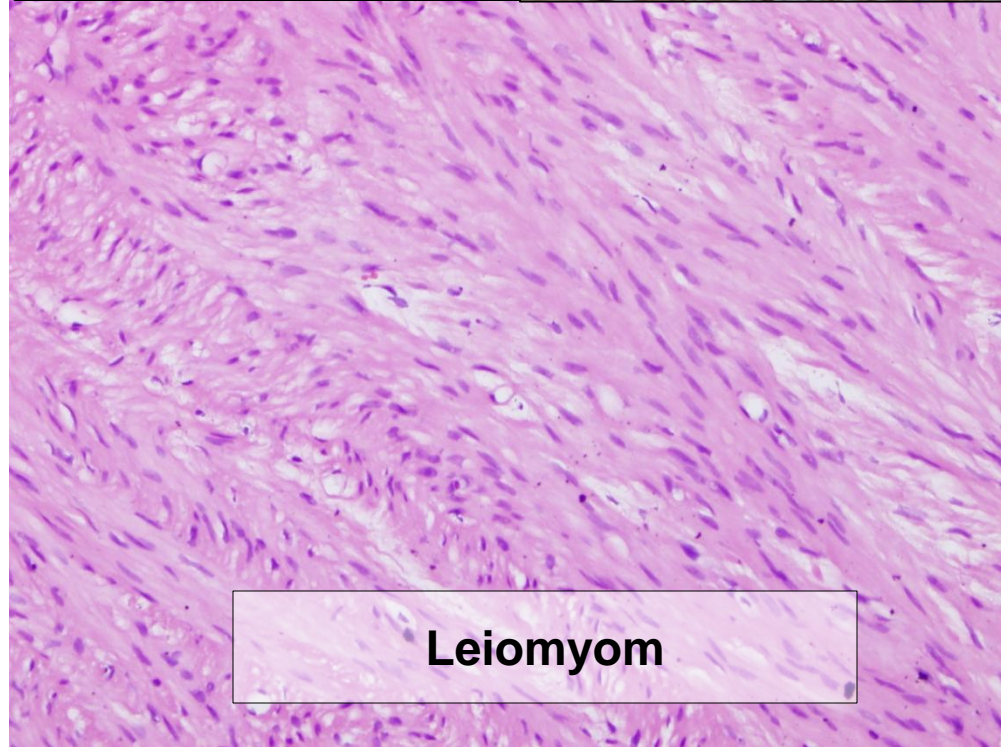- Nodüler fasiit
- Fibrosarkom
- Sinovyal sarkom
- Düşük dereceli fibromikzoid sarkom
- Düşük dereceli MPNST
- Düz kas tümörleri
- İdiopatik retroperitoneal fibrozis
- Keloid
- GIST

Leiomyom



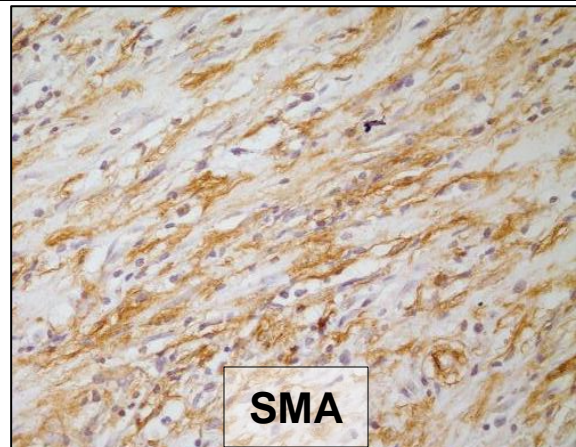
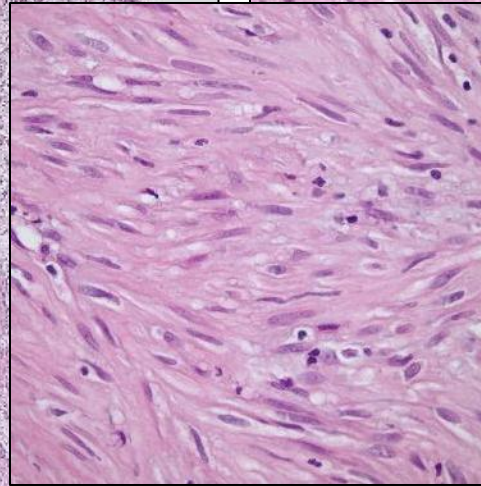
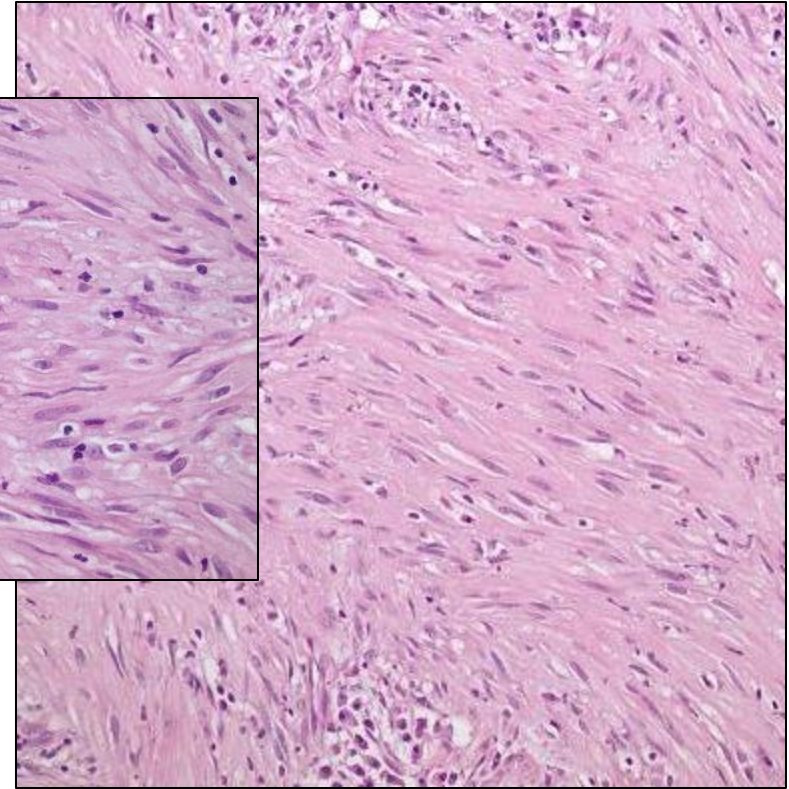
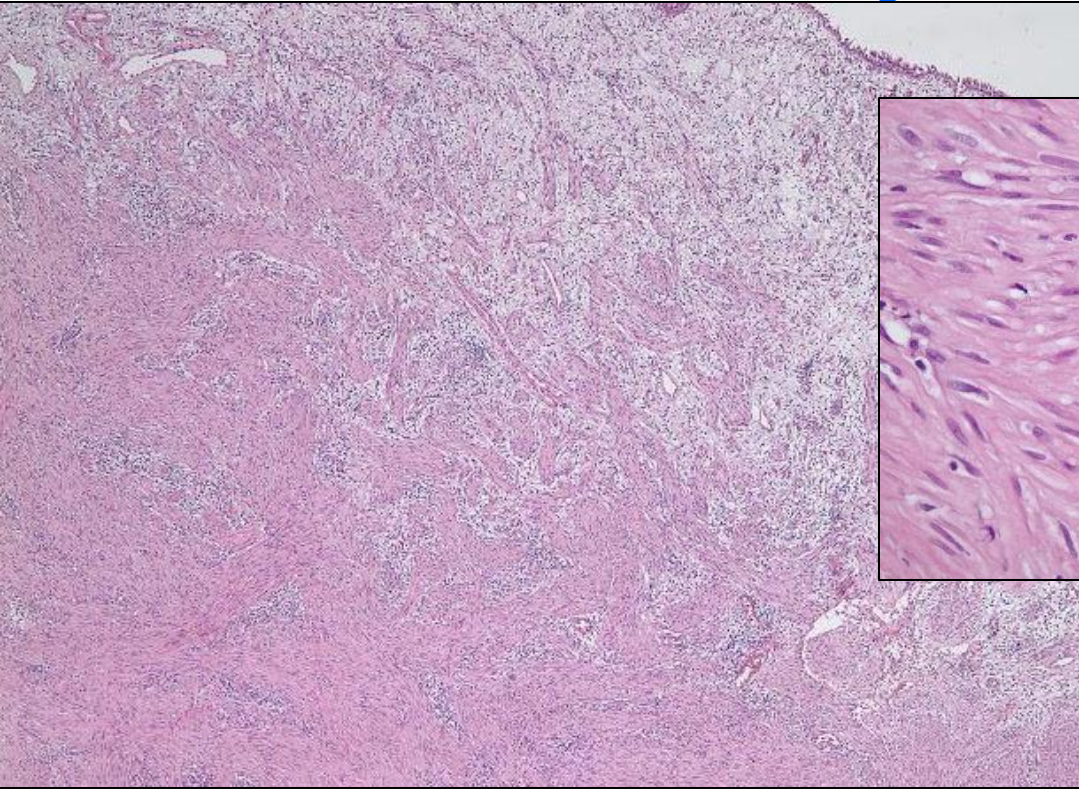
Desmin

SMA

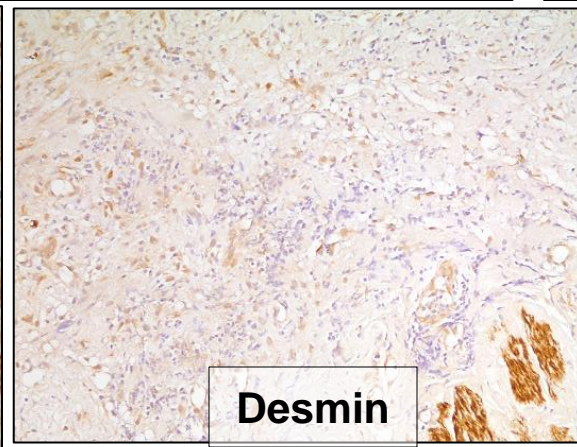


Leiomyom

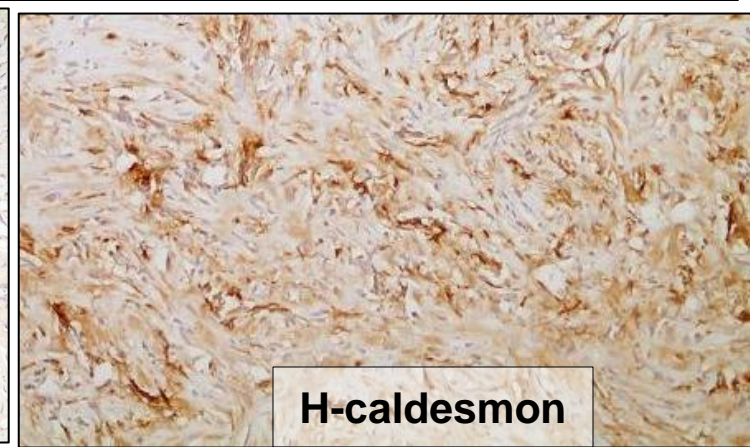Leiomyosarkom



SMA

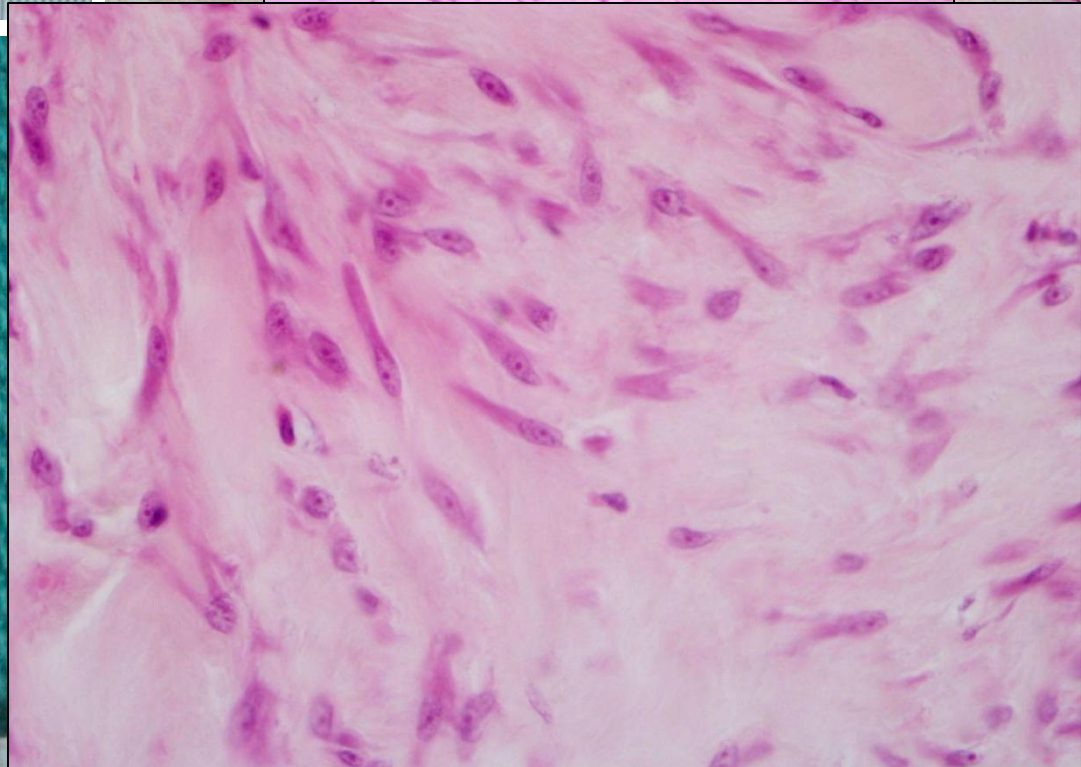
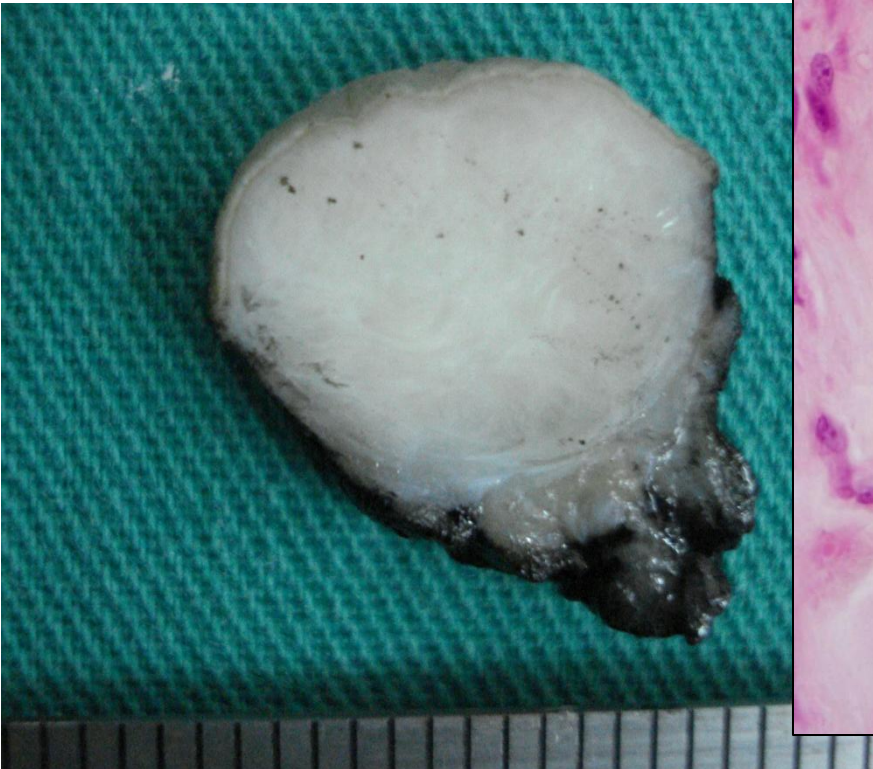
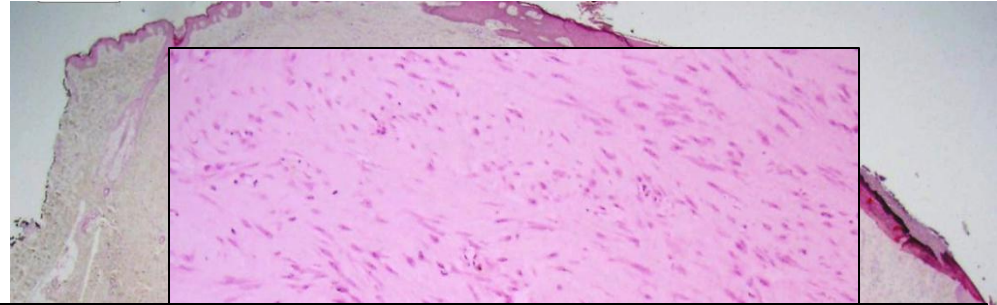
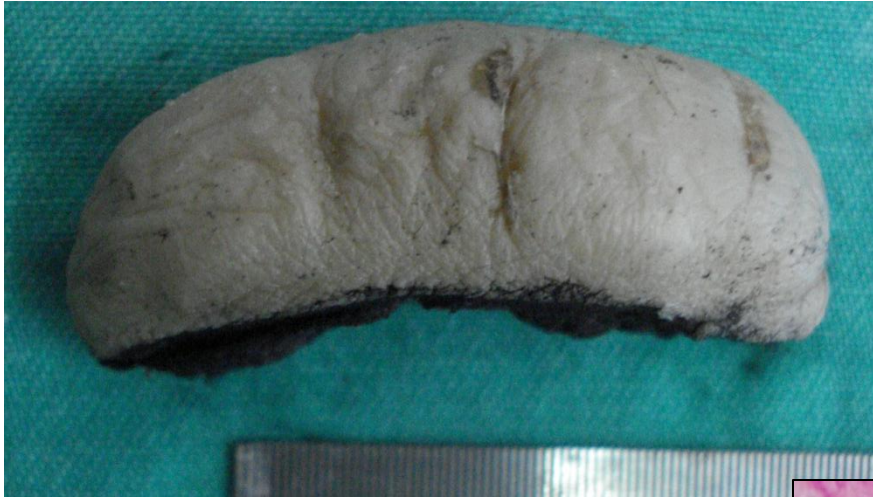

Desmin

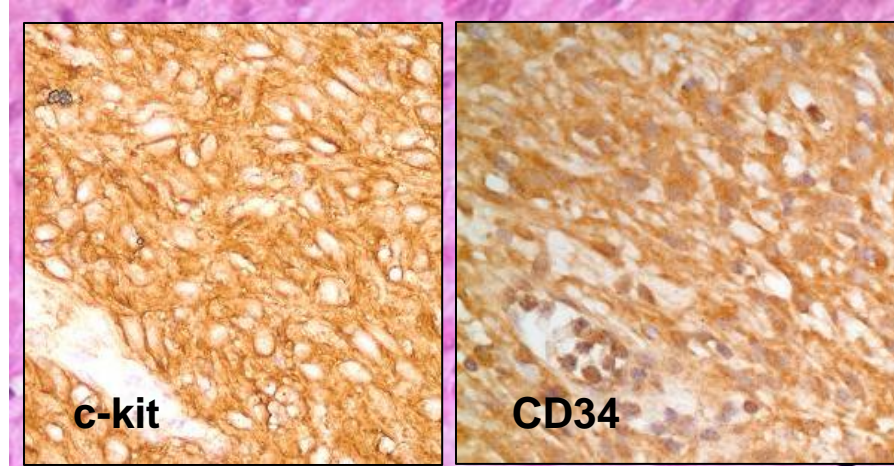
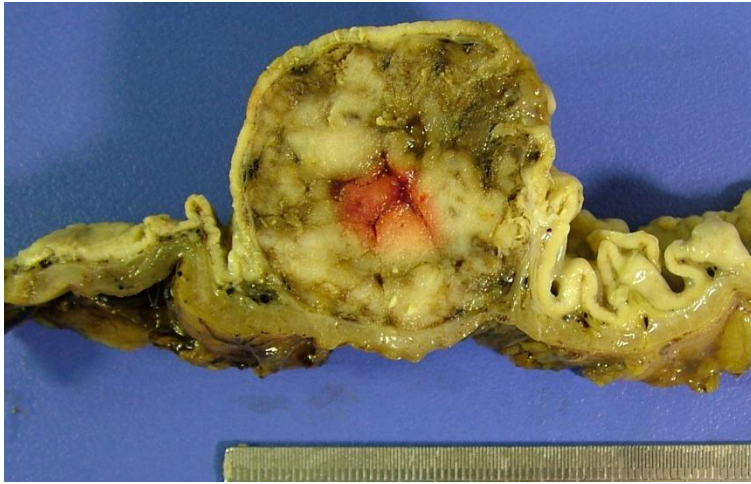

H-caldesmon

Keloid



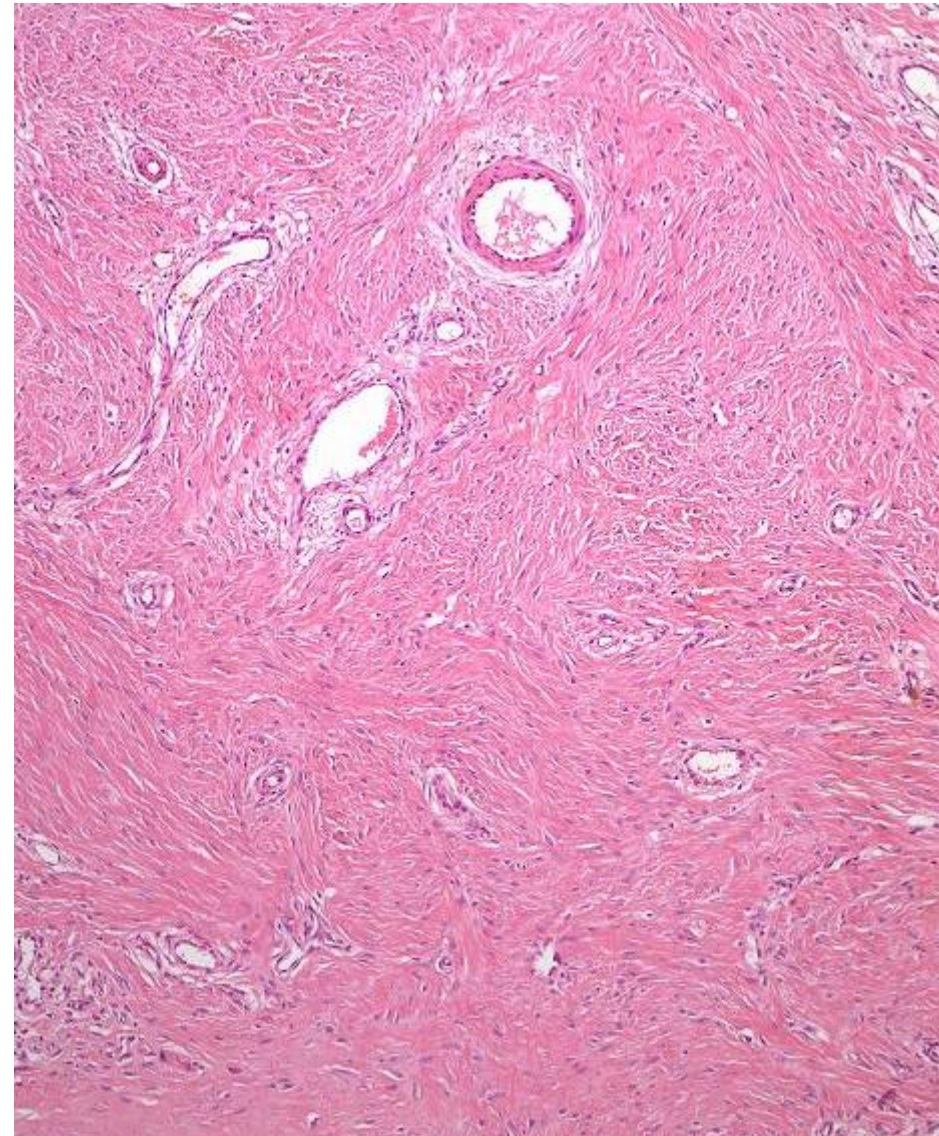
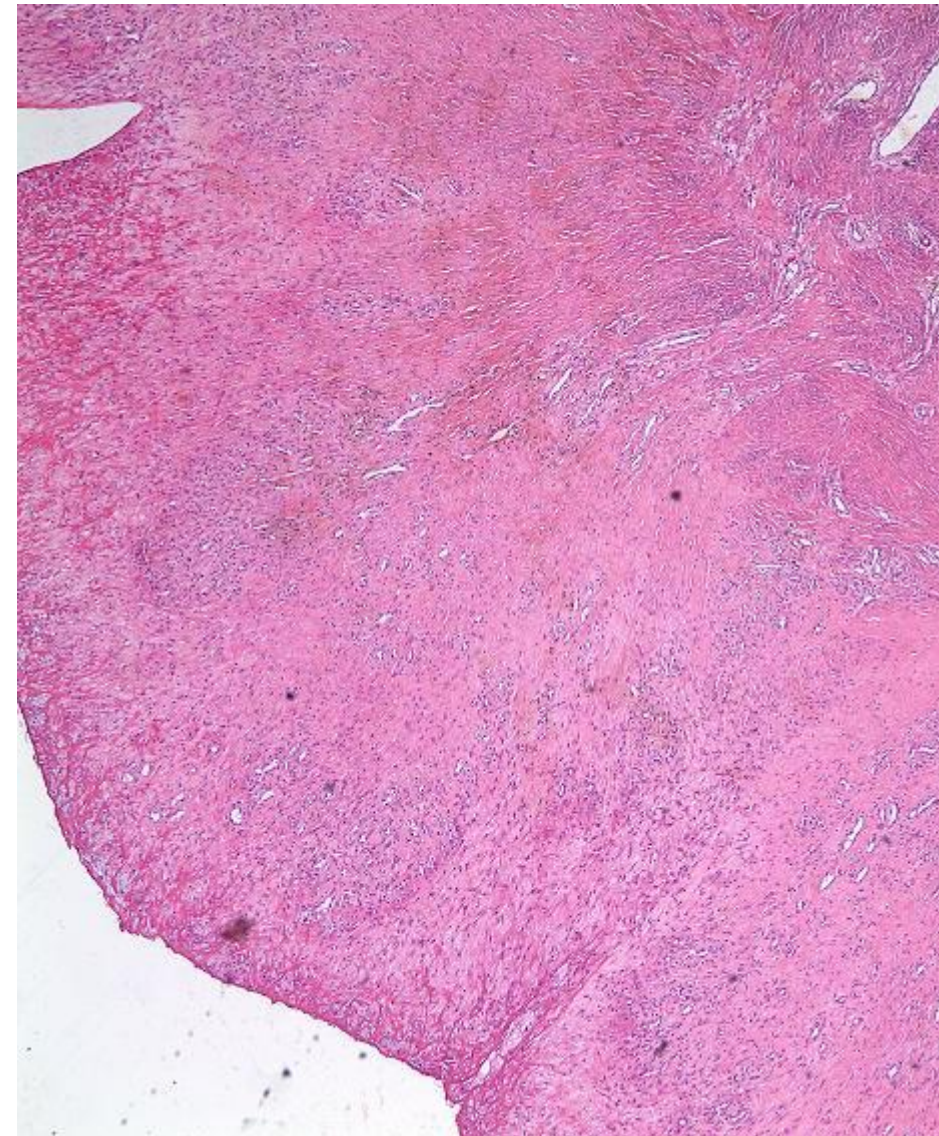
GIST



Her ikisi de c-kit + olabilir!

**Fibromatozis: β -katenin+
GIST: DOG1, CD34+**

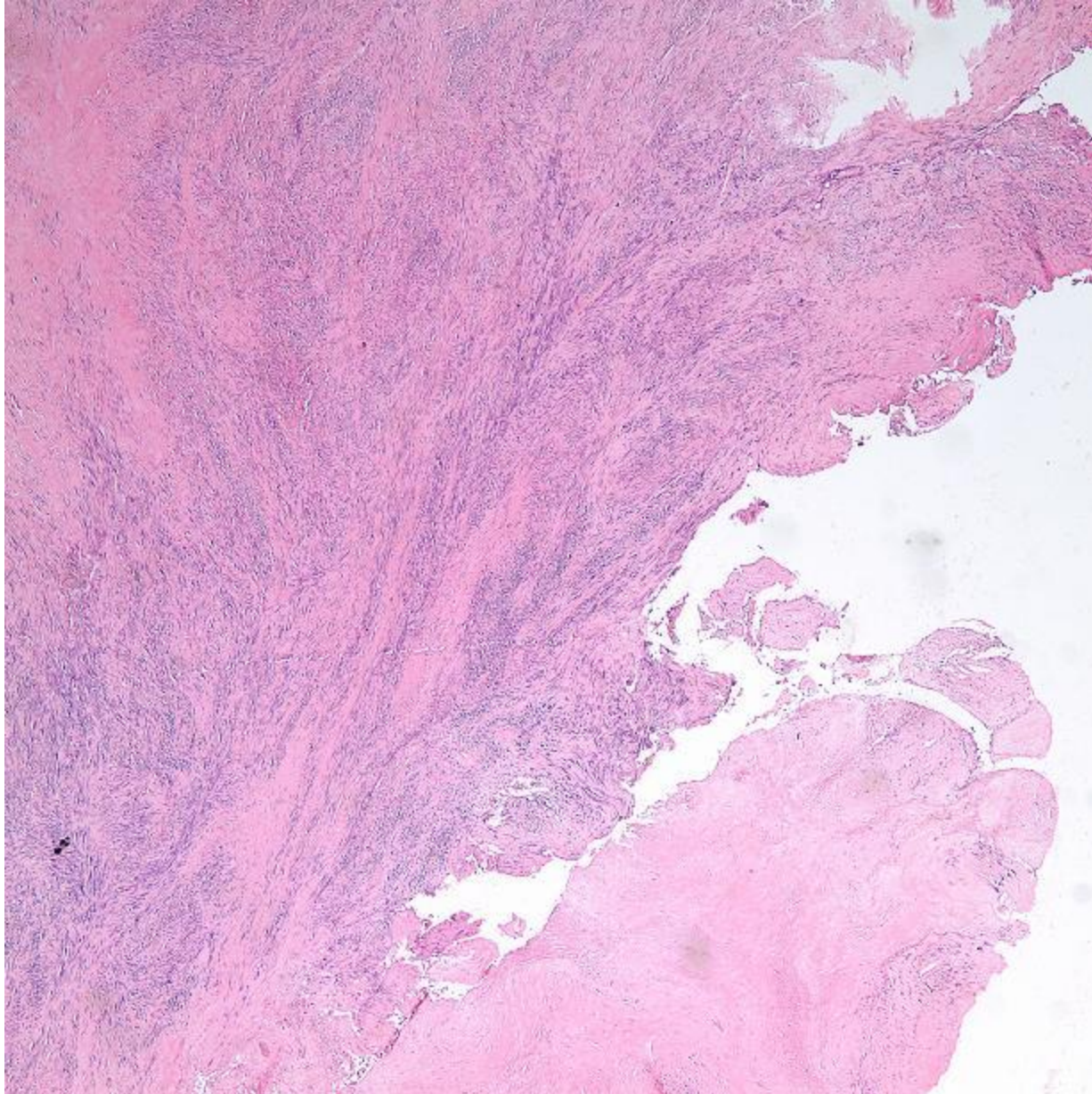
Periprostetik fibromatozis benzeri alanlar

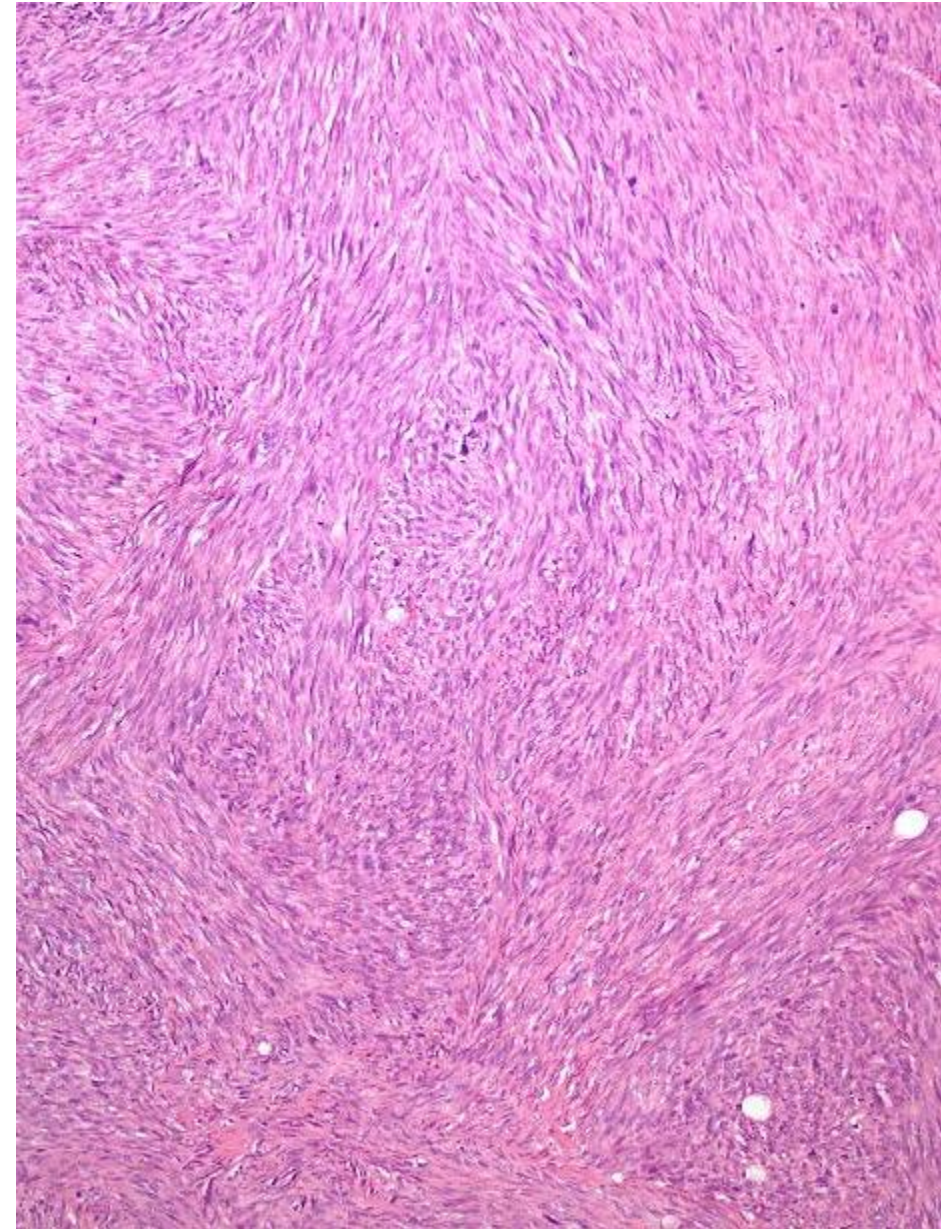
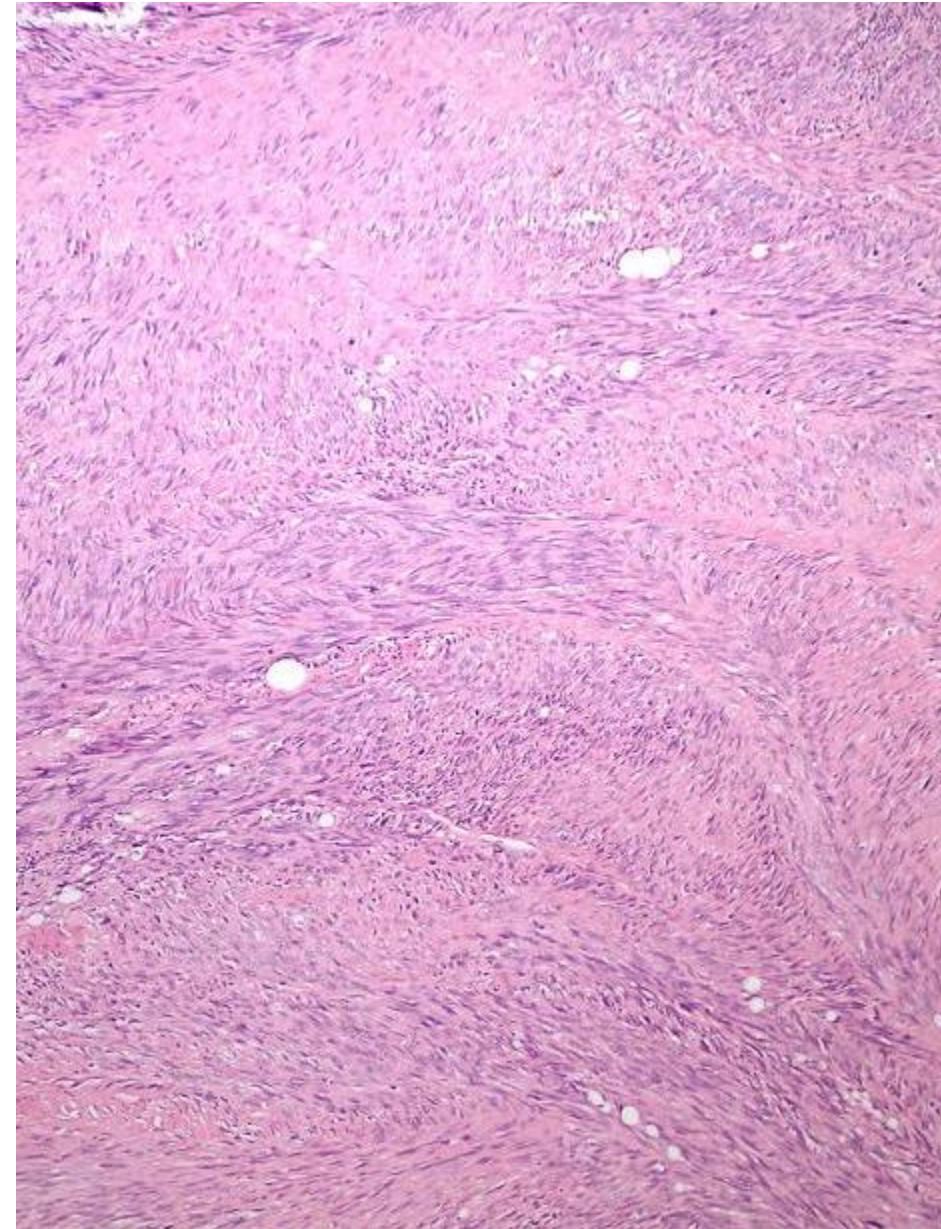


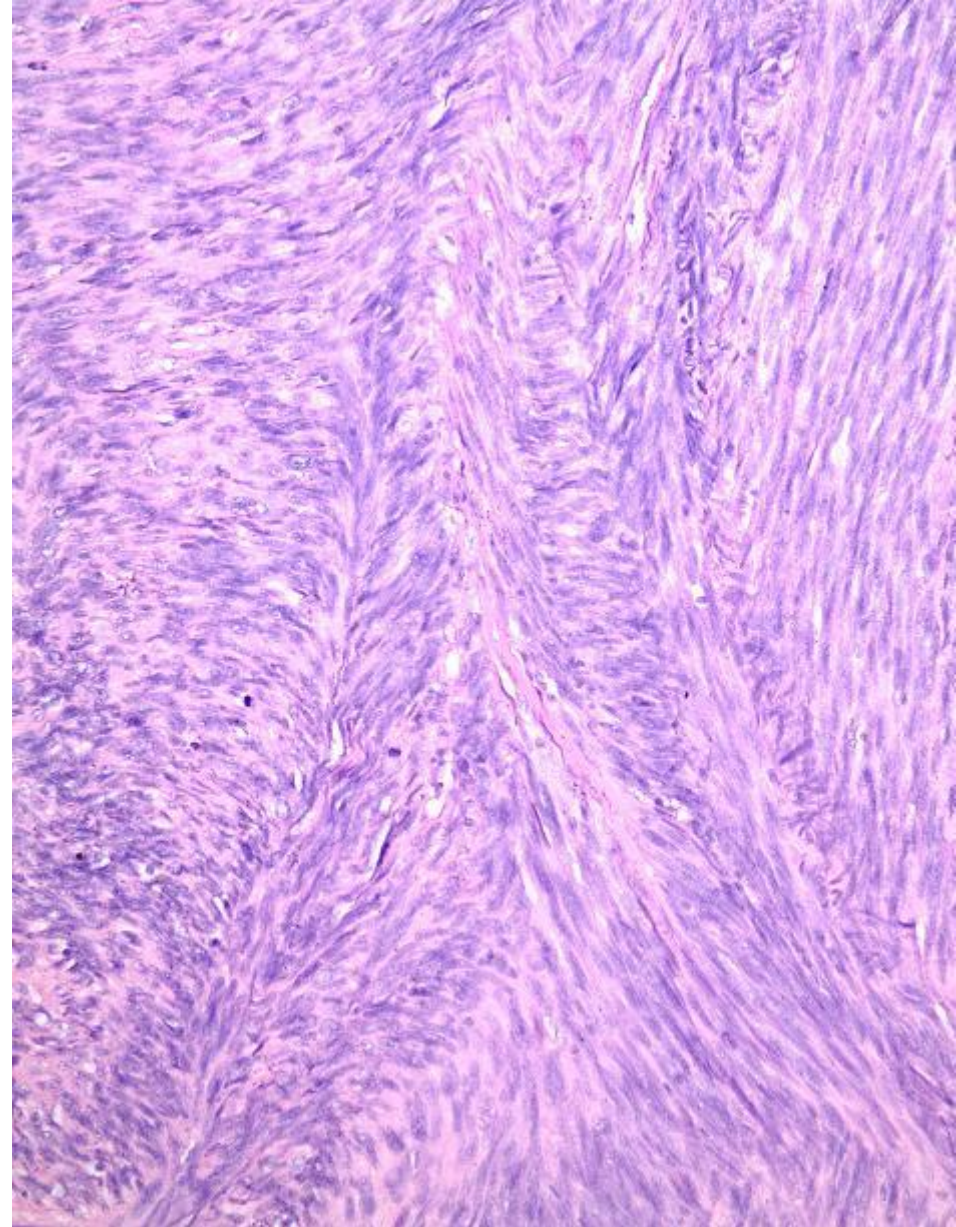
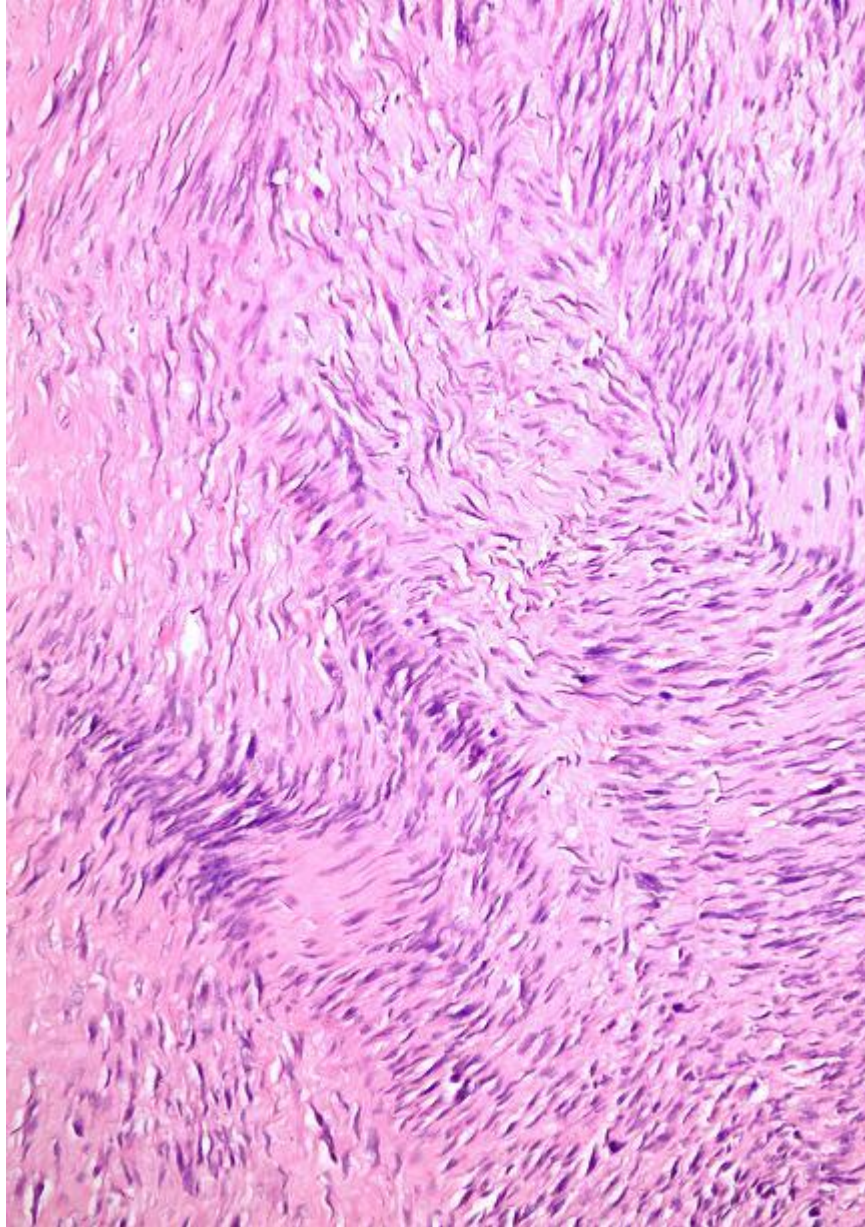
Olgu 5

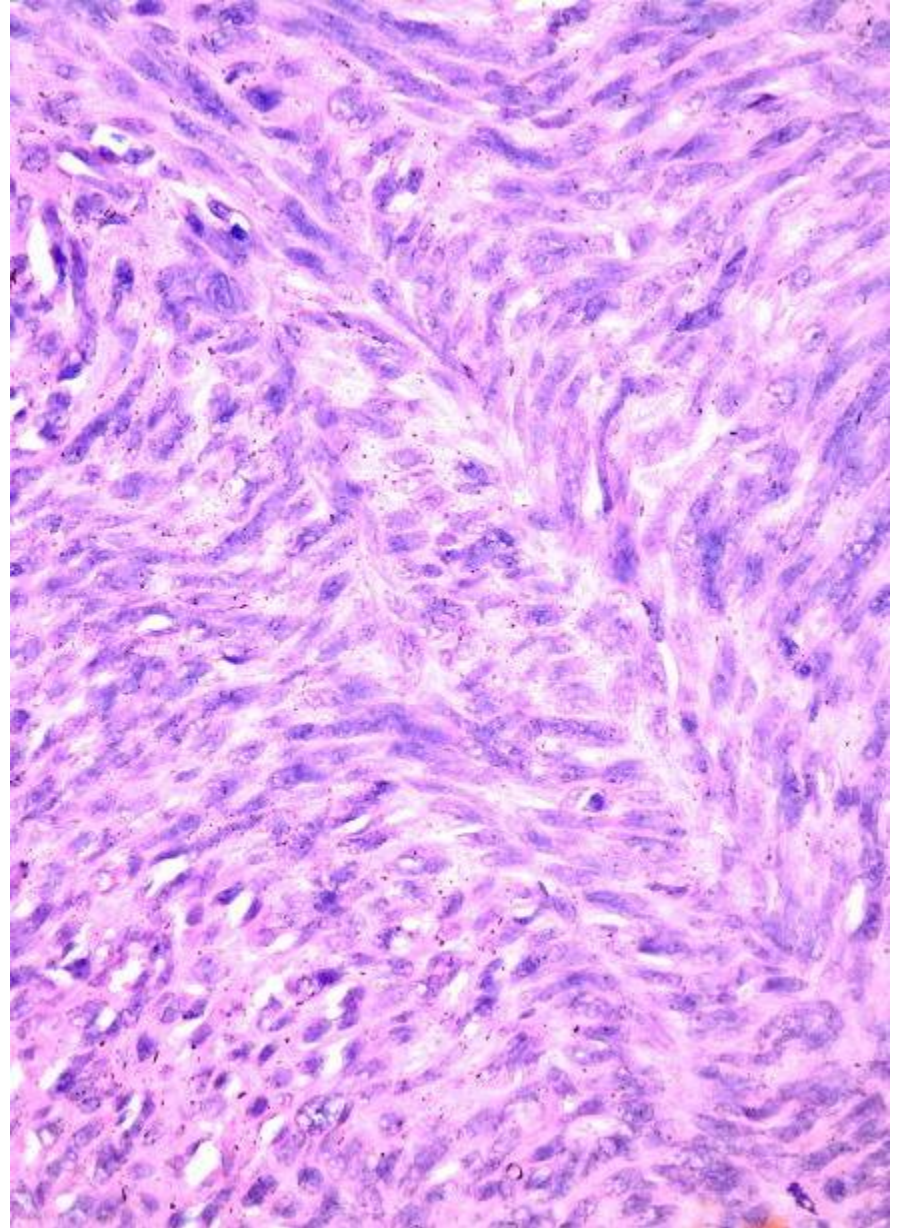
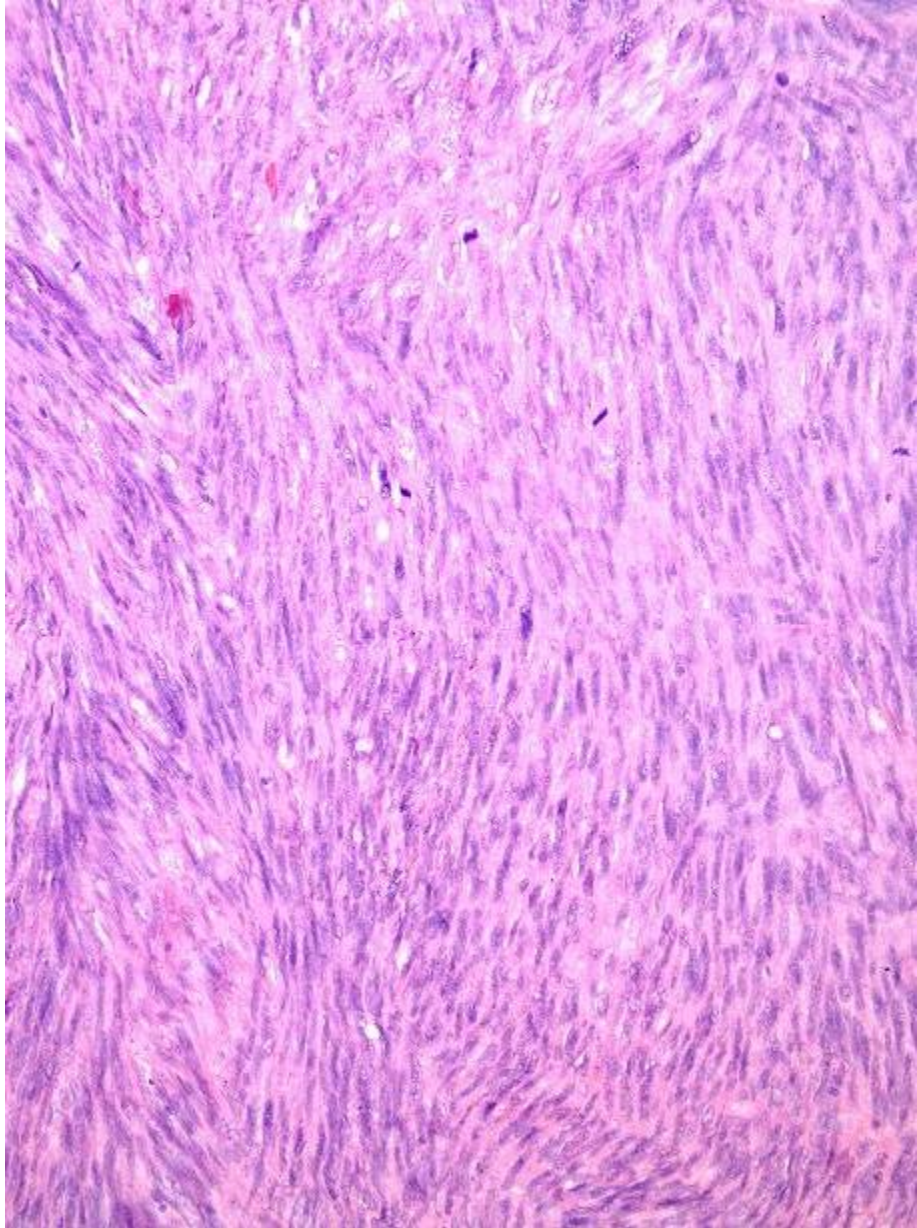
67 ♀

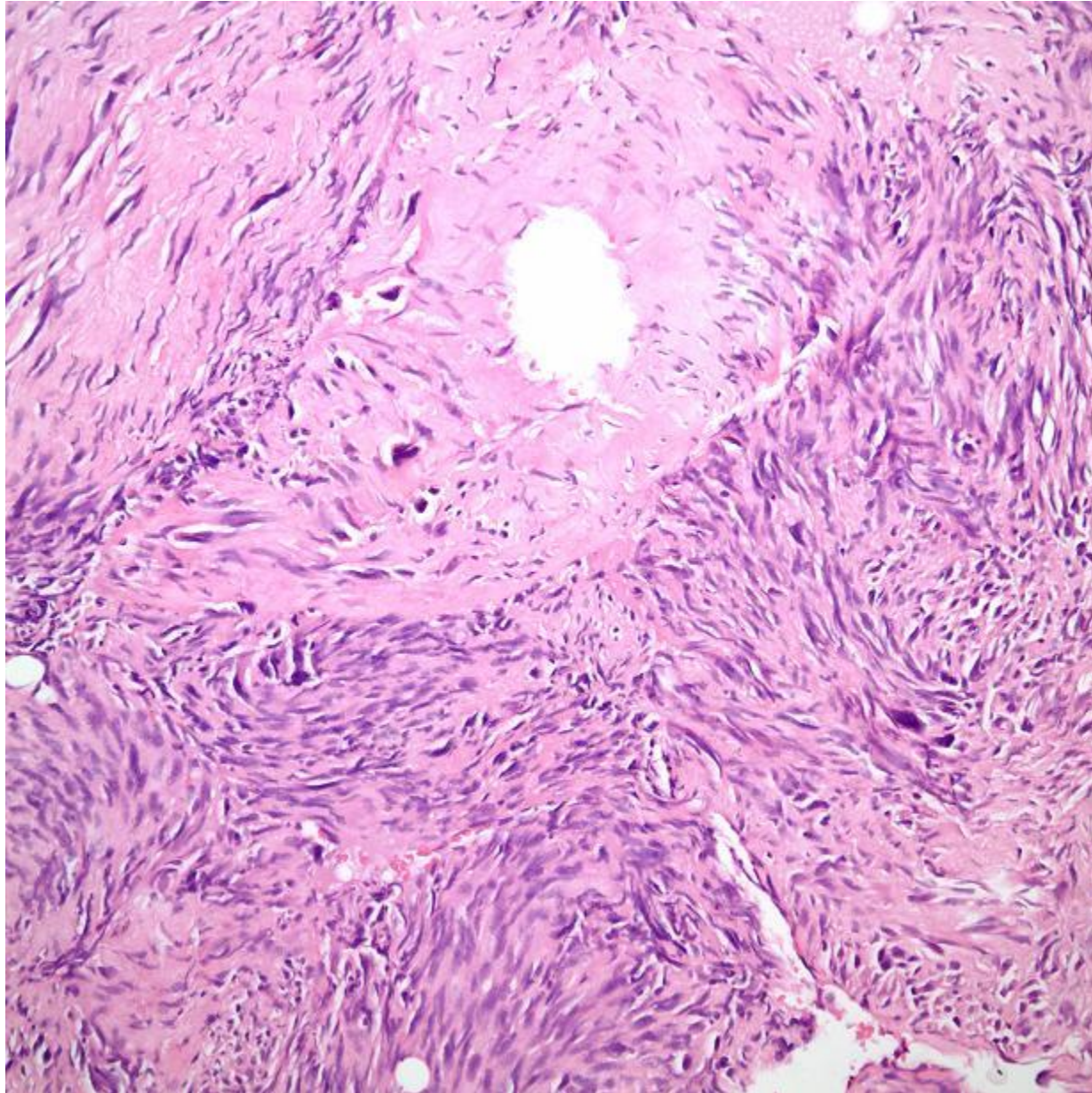
Sağ kalça protezi çevresinden periprostetik dokular

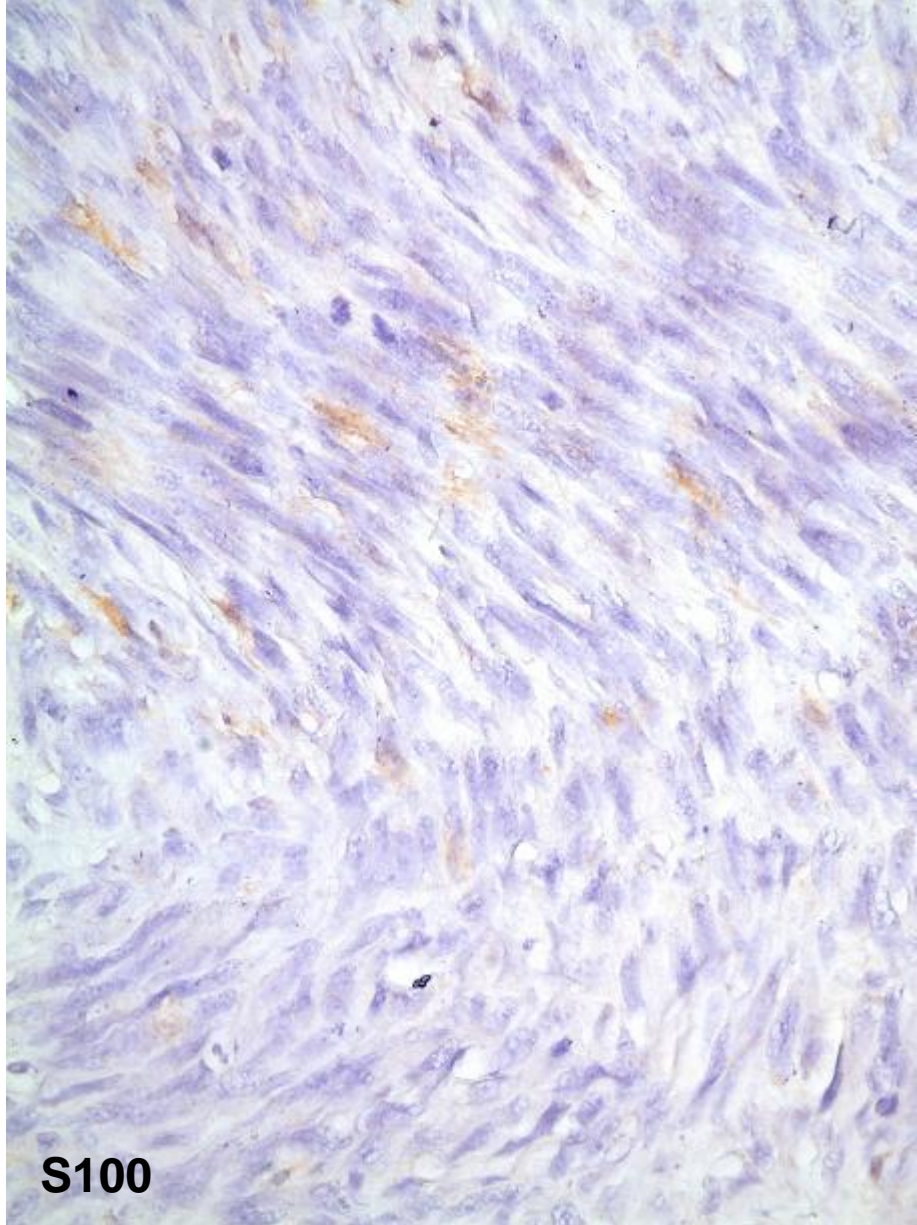




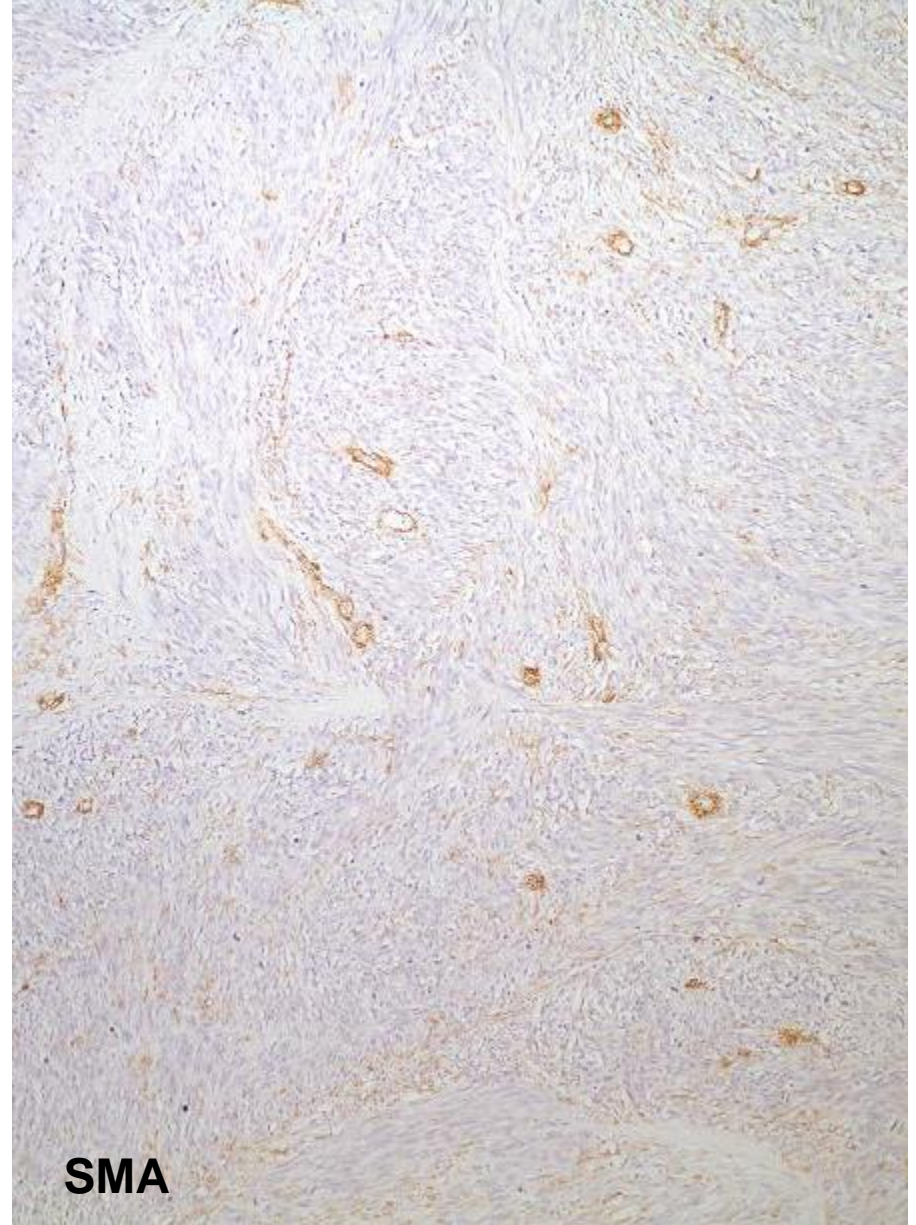








S100



SMA

TANI:

**Fibrosarkom,
protez çevresinde gelişen**

Fibrosarkom

İnciler

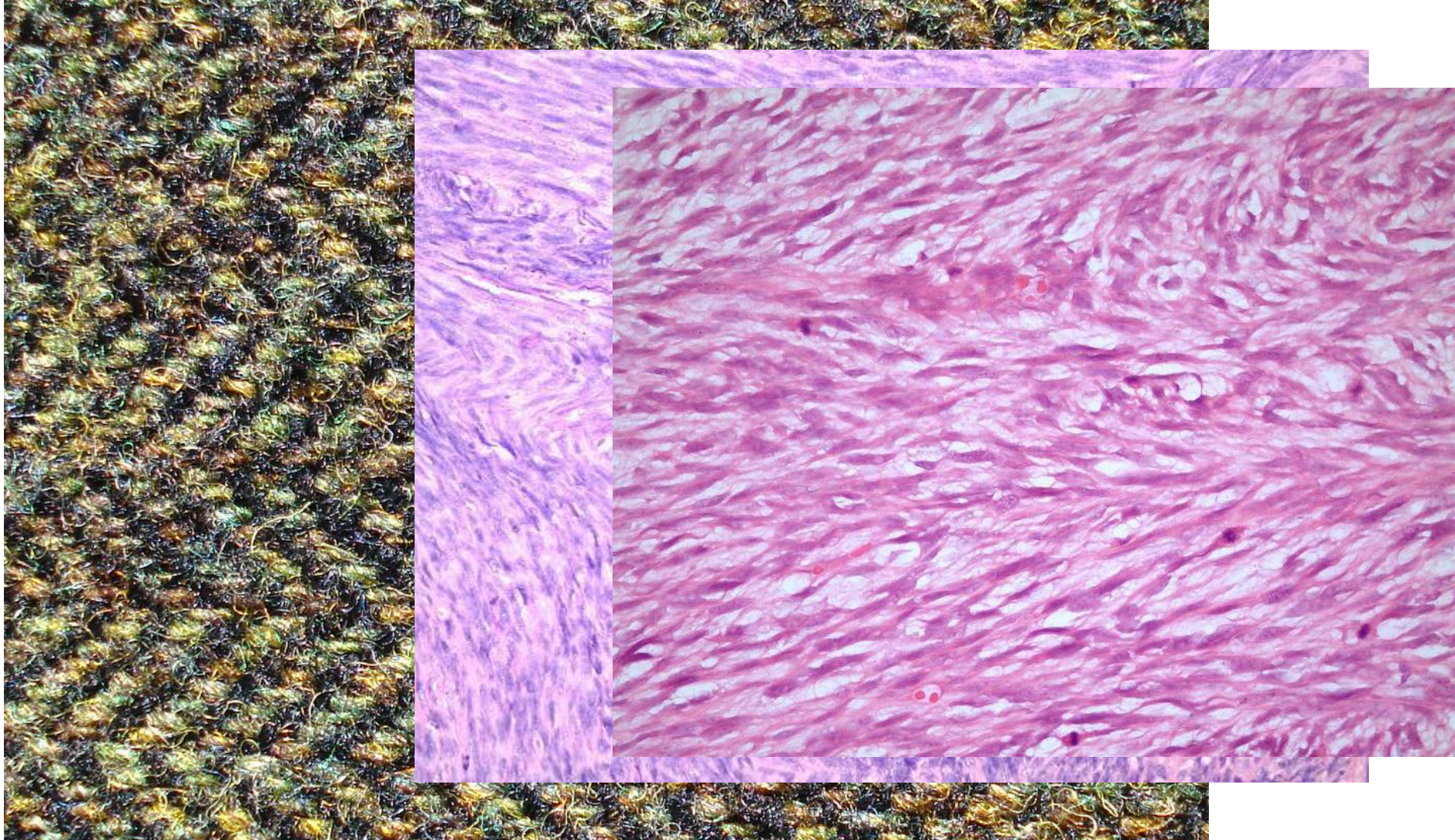
Klinik

- Genç erişkin, ekstremiteler
- Derin yerleşim (Yüzeyel ise DFSP zemini?)

Morfoloji

- Herringbone patern
- Mitoz, sellülerite artışı, nükleer atipi

Fibrosarkom



Fibrosarkom

İnciler



Fibrosarkom tanısı bir dışlama tanısıdır.

- 1. Soliter fibröz tümör, monofazik sinovyal sarkom ve düşük dereceli MPNST nin immünohistokimyasal, ultrastrüktürel ve moleküler yöntemlerle ekarte edilmesi gerekmektedir.**
- 2. Myofibroblastik diferansiasyon fibrosarkom tanısına engel değildir.**
- 3. Yüksek dereceli nükleer atipi içeren kollajen üreten tümör indiferansiye pleomorfik sarkom olarak sınıflandırılır.**

Adult-type Fibrosarcoma: A Reevaluation of 163 Putative Cases Diagnosed at a Single Institution Over a 48-year Period

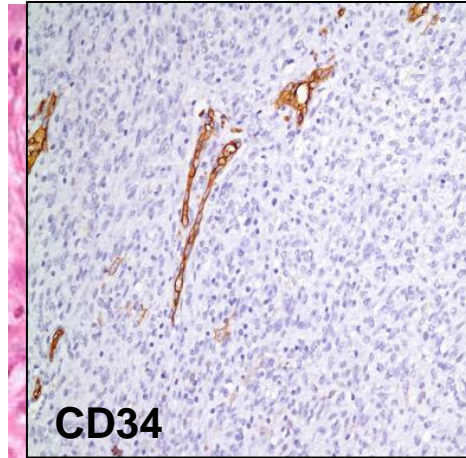
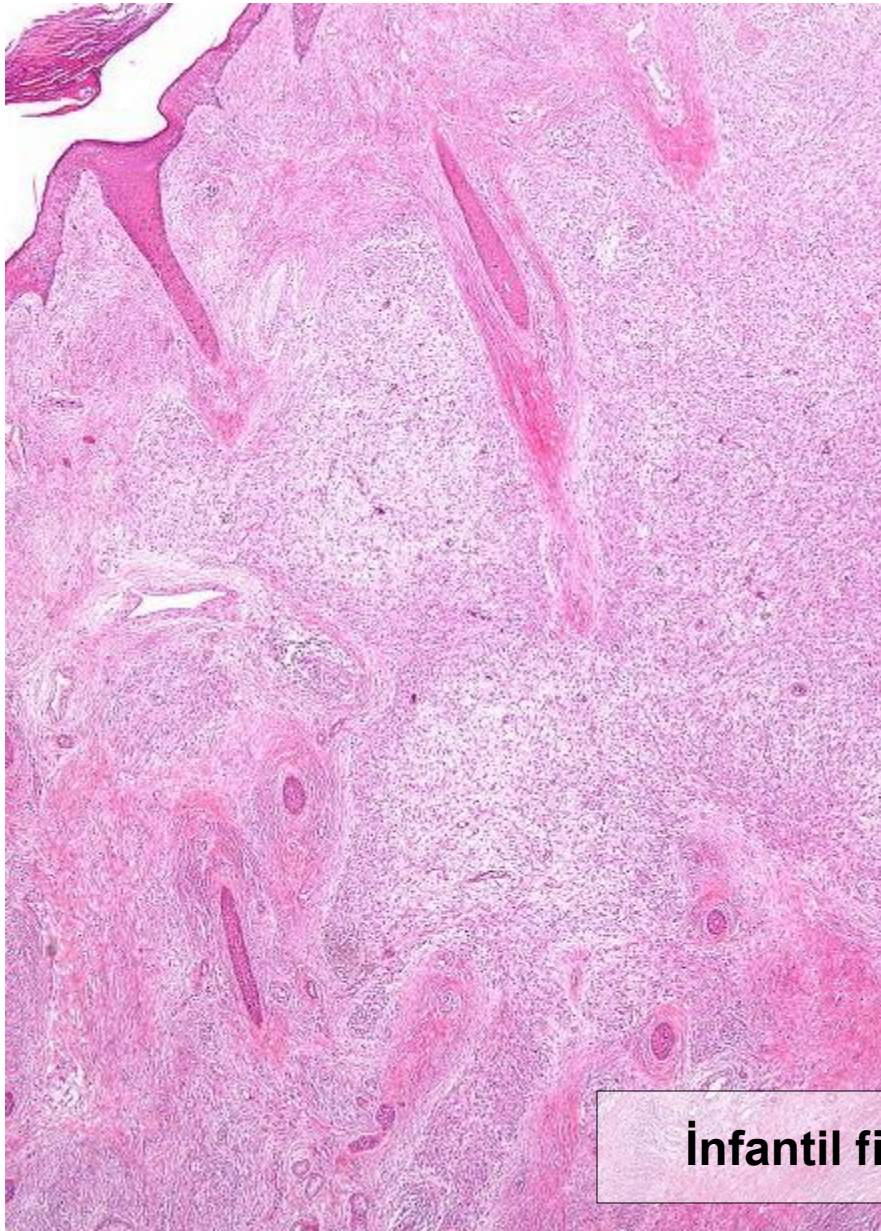
Armita Bahrami, MD and Andrew L. Folpe, MD

Tumor	Criteria	No. (%)
Fibrosarcoma	(1) Hyperchromatic spindled cells showing no more than moderate pleomorphism, (2) a fascicular, "herringbone" growth pattern, (3) a variable degree of interstitial collagen, (4) the absence of any morphologic features of myxofibrosarcoma, low-grade fibromyxoid sarcoma, sclerosing epithelioid fibrosarcoma or fibrosarcoma arising in dermatofibrosarcoma protuberans, and (5) absent expression of any markers other than vimentin or very minimal smooth muscle actin	26 (16)
Undifferentiated pleomorphic sarcoma	(1) Markedly pleomorphic spindled cells, (2) negative for all lineage-specific markers	32 (20)
Synovial sarcoma	(1) Hyperchromatic spindled cells, alternating hypercellular and hypocellular zones, intervening wiry collagen, hemangiopericytic vascular pattern, (2) focal expression of cytokeratins or EMA, CD34-negative, TLE-1 uniformly positive, (3) <i>SYT</i> FISH positive if cytokeratin-negative	21 (13)
Solitary fibrous tumor	(1) Bland oval spindled cells arranged in a "patternless" pattern, abundant hyalinized stromal collagen, "staghorn" blood vessels, (2) CD34-positive	14 (9)
Malignant peripheral nerve sheath tumor	(1) Relatively monomorphic spindled cells with elongated wavy/buckled nuclei, growing in a fascicular or whorled pattern, alternating zones of hypocellularity and hypercellularity, accentuated perivascular cellularity, herniation of neoplastic cells into the vessel lumen, (2) focal S100 expression, variable CD34 expression, patchy TLE1 expression, cytokeratin-negative	8 (5)
Myxofibrosarcoma	(1) Abundant myxoid matrix, thick-walled arborizing blood vessels, spectrum of cytologic atypia, (2) negative for all lineage-specific markers	11 (7)
Low-grade fibromyxoid sarcoma	(1) Hypocellular bland fibroblastic cells, heavily collagenized stroma alternating with more cellular areas, (2) negative for all lineage-specific markers	3 (2)
Sclerosing fibrosarcoma	(1) Epithelioid fibroblastic cells arranged in single file arrays, cords, and nests, densely hyalinized stroma, (2) negative for all lineage specific markers	2 (1)
Fibrosarcoma with myxoid areas	(1) Superficial location, (2) component of typical DFSP, (3) abrupt transition to fibrosarcomatous zones, (3) variably CD34-positive	4 (3)
Malignant myxoid fibrosarcoma	(1) Infiltrative, (2) mild-to-moderate atypic spindled cells with tapered nuclei and lightly eosinophilic cytoplasm, (3) focal desmin expression, (4) focal smooth muscle actin expression in "tram track" pattern, desmin-negative or only limited desmin expression	3 (2)
Malignant cellular fibrous histiocytoma	(1) Intersecting fascicles of distinctly eosinophilic cells with perinuclear vacuoles and "cigar shaped" nuclei, (2) smooth muscle actin and desmin positive	2 (1)
Angiosarcoma	(1) Vasotormative growth, (2) expression of CD31, FLI1 protein	1 (0.5)
Kaposi sarcoma	(1) Formation of slit-like vascular channels, chronic inflammatory cell infiltrate, (2) expression of CD31, CD34, FLI-1 protein, HHV8 LANA	1 (0.5)
Sarcomatoid carcinoma	(1) Superficial location, (2) expression of wide spectrum and high molecular weight cytokeratins, CD34-negative, INI-1 positive	3 (2)
Spindle cell melanoma	(1) Superficial location, (2) packets of hyperchromatic spindled cells, desmoplasia, chronic inflammation, (2) expression of S100 protein ± gp100 protein/Melan A	4 (3)
Clear cell sarcoma	(1) Deep location, (2) nests of epithelioid to spindled cells with prominent nucleoli, (3) S100 protein, gp100, Melan-A expression, (4) <i>EWS</i> rearrangement by FISH (data not shown)	1 (0.5)
Fibroma-like epithelioid sarcoma	(1) Hyperchromatic spindled cells with focal epithelioid features, (2) cytokeratin and CD34-positive, INI-1 negative	2 (1)
Rhabdomyosarcoma	(1) Variably pleomorphic spindled cells, (2) desmin, myogenin, MyoD1-positive	3 (2)
Ewing sarcoma with spindle cell feature	(1) Round cell tumor with spindling, (2) positive for Ewing sarcoma-associated fusion genes by RT-PCR (data not shown)	1 (0.5)
Dedifferentiated or spindle cell liposarcoma	(1) Well-differentiated adipocytic component ± lipoblasts, (2) <i>CPM</i> FISH positive (data not shown)	3 (2)
Ossifying fibromyxoid tumor	(1) Focal peripheral ossification, (2) uniform round cells with even cell-cell spacing in a fibromyxoid matrix, (3) S100 protein-positive	1 (0.5)
Desmoid-type fibromatosis	(1) Long fascicles of uniformly bland myofibroblastic cells, thin-walled blood vessels	3 (2)
Cellular fibrous histiocytoma	(1) Superficial location, (2) epidermal hyperplasia, peripheral collagen trapping, short fascicles of lightly eosinophilic spindled cells	2 (1)
Cellular schwannoma	(1) Encapsulated, (2) fascicular proliferation of bland, schwannian-looking spindled cells, (3) diffuse S100 protein expression	1 (0.5)

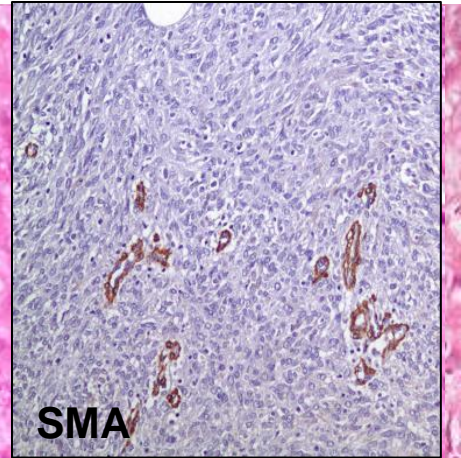


Erişkin fibrosarkom çok nadirdir (<1%)

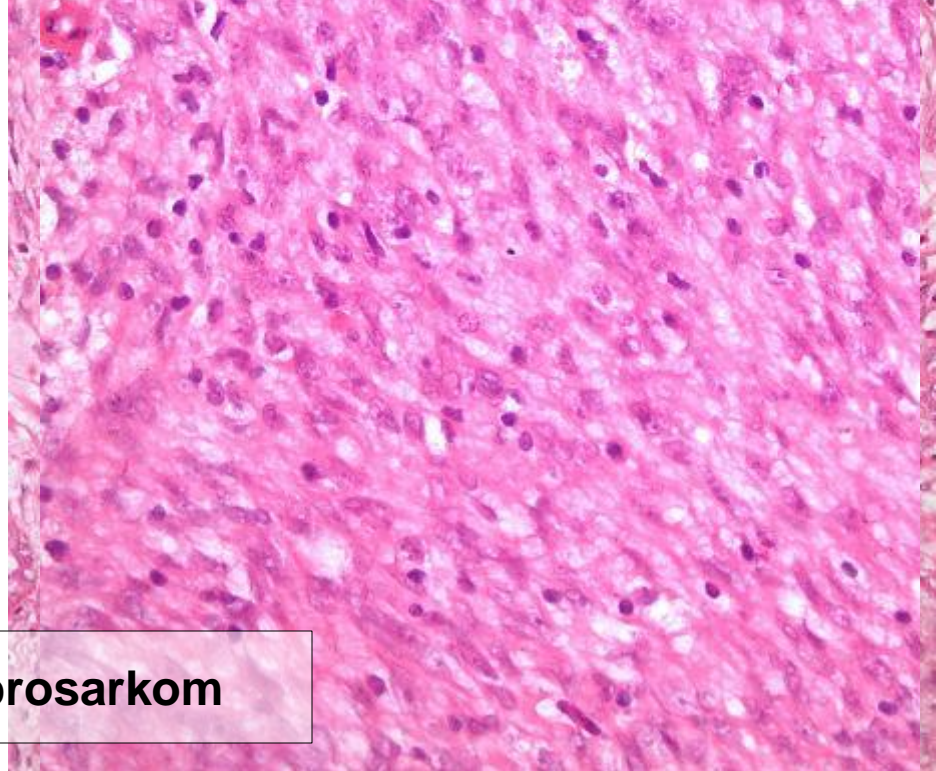
Taniyı iki kez düşünün!



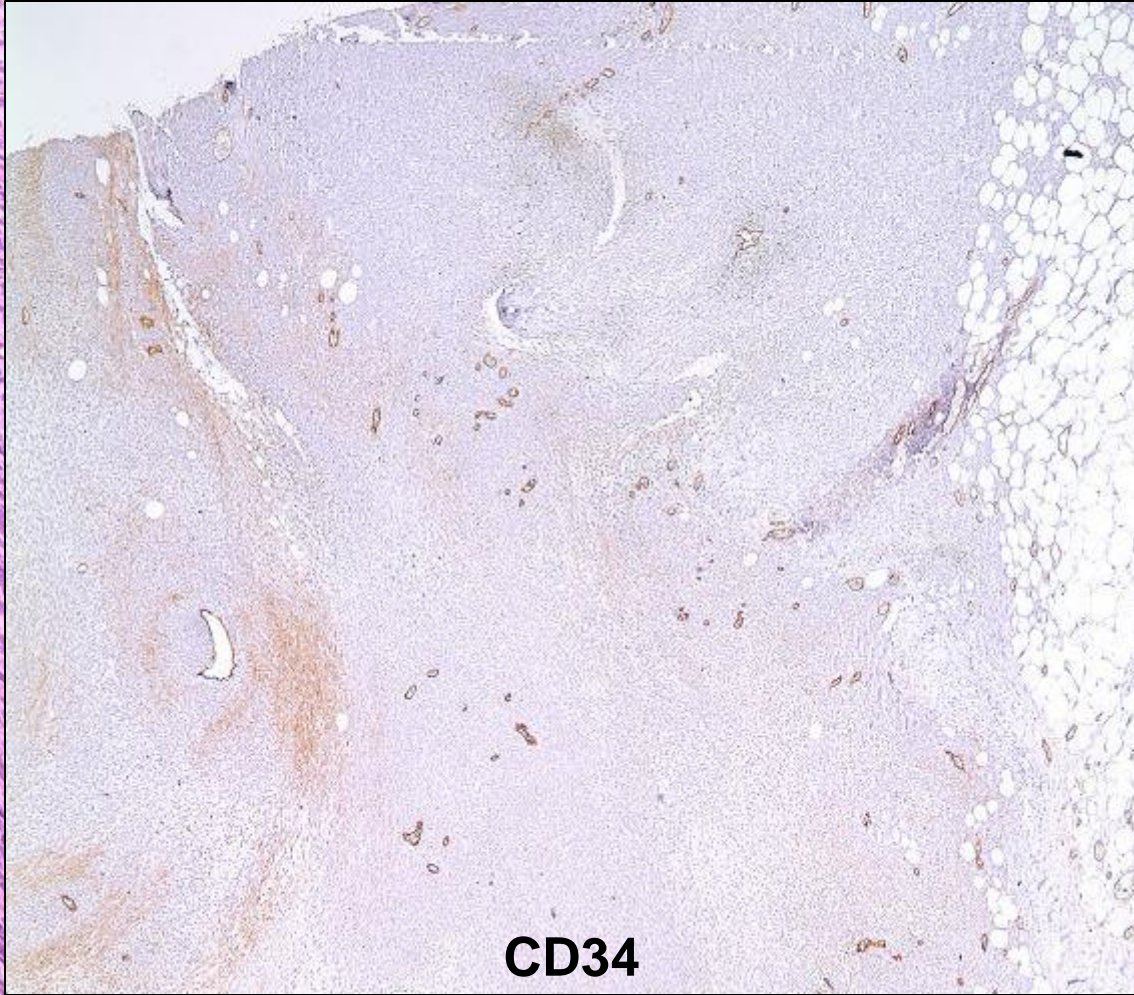
CD34



SMA

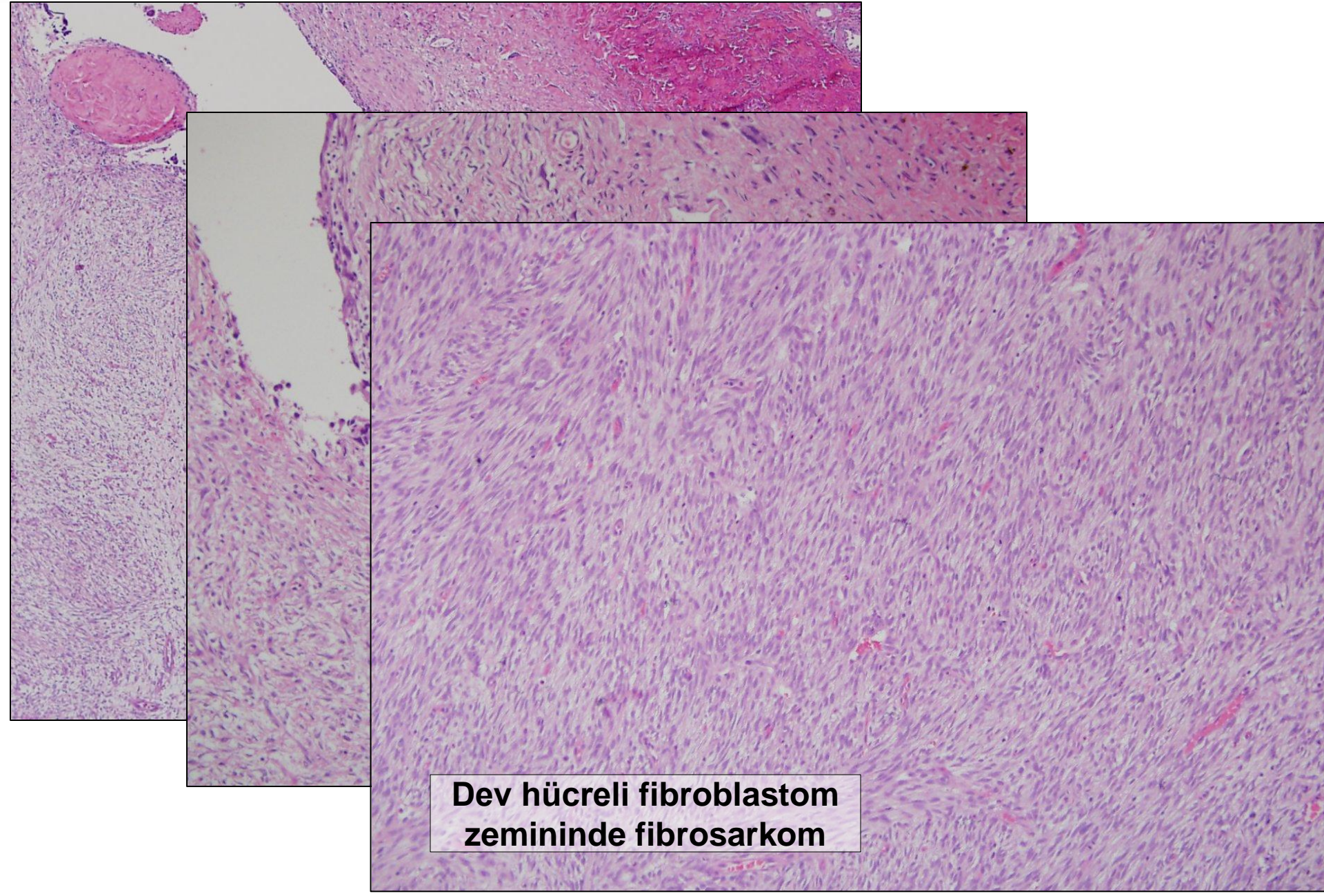


İnfanıl fibrosarkom



CD34

**DFSP zemininde
fibrosarkom**

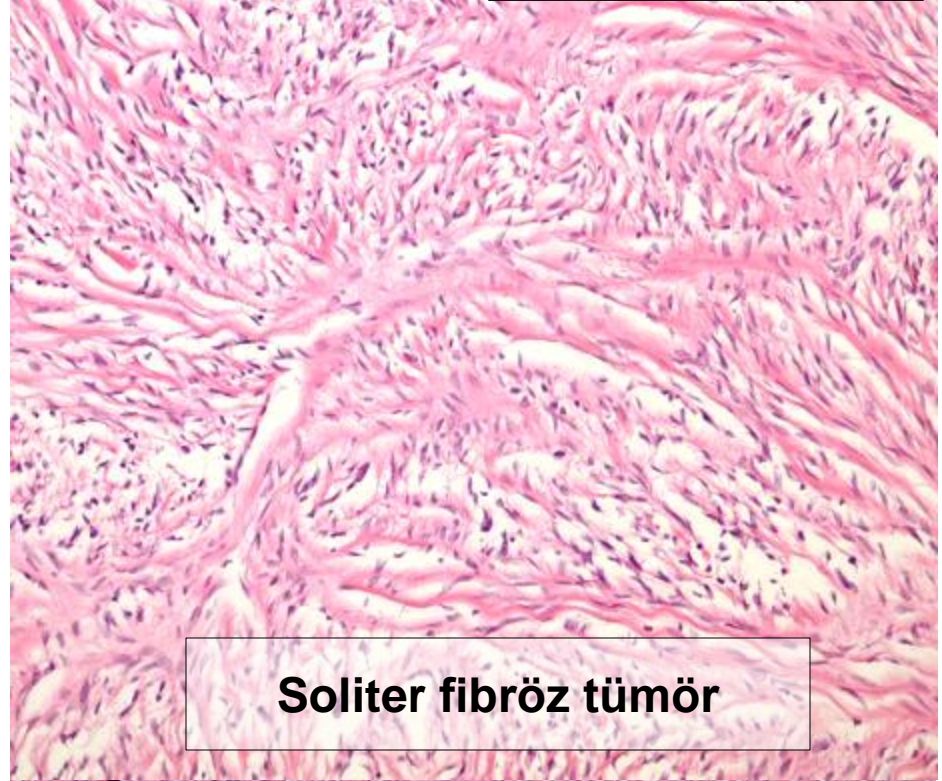
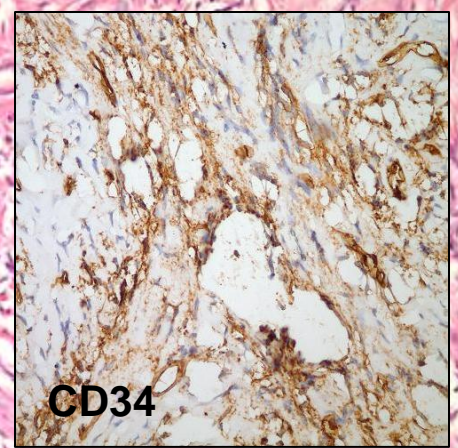
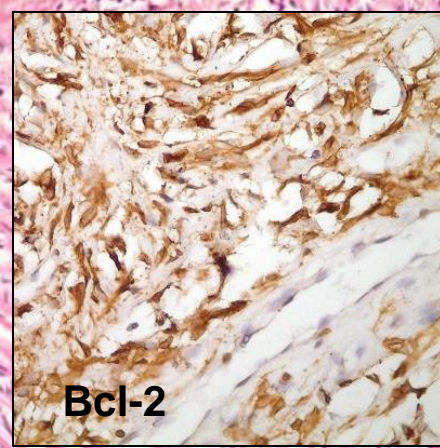
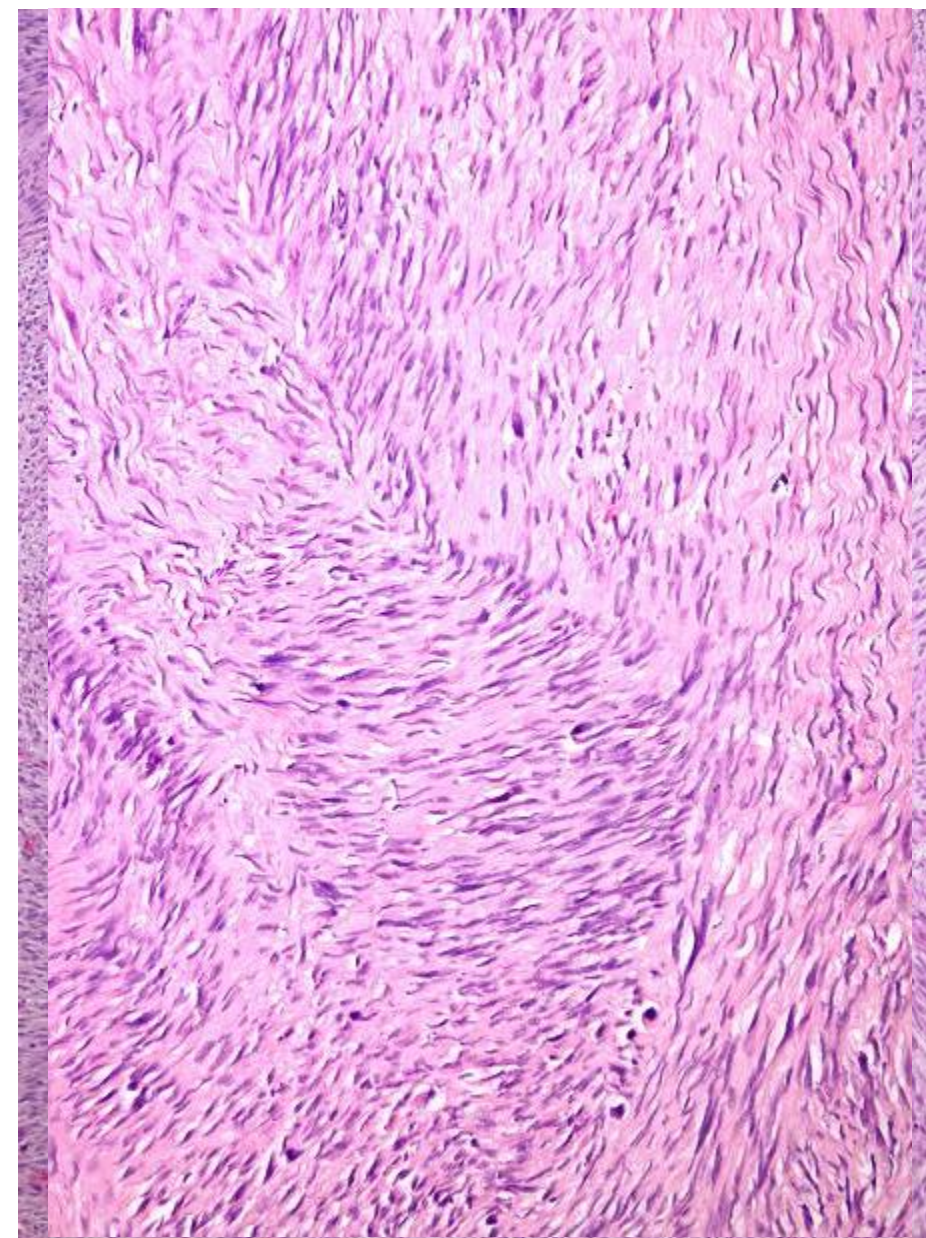


**Dev hücreli fibroblastom
zemininde fibrosarkom**

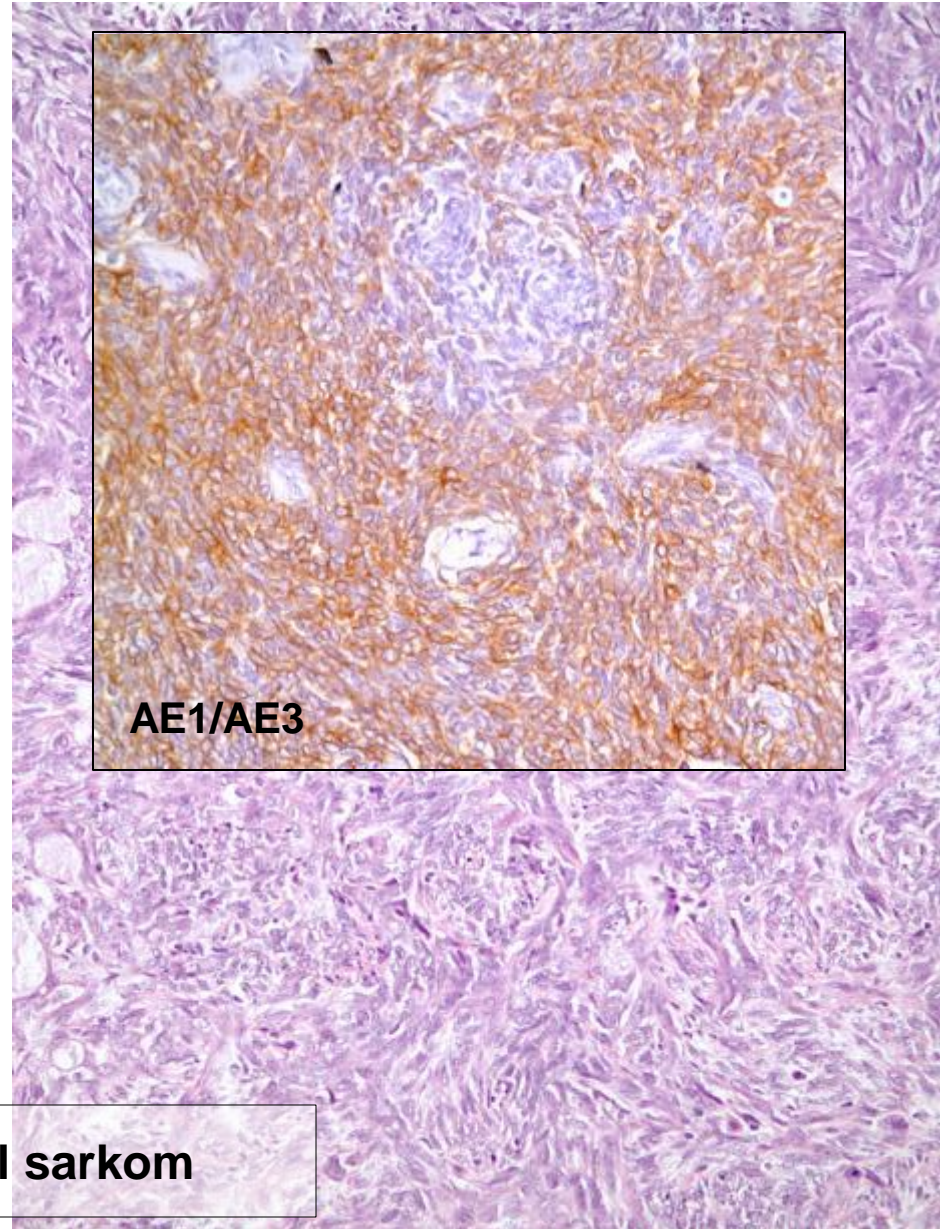
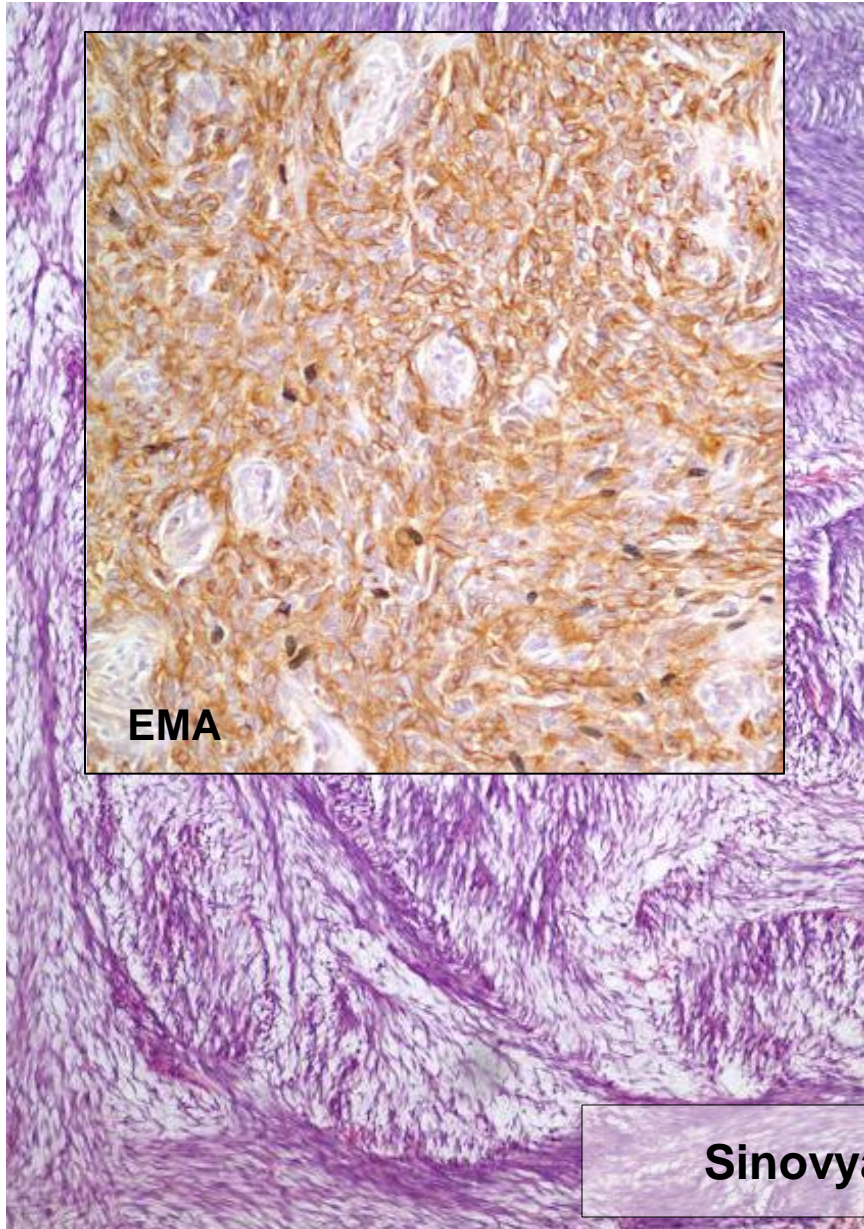
Fibrosarkom

DDx

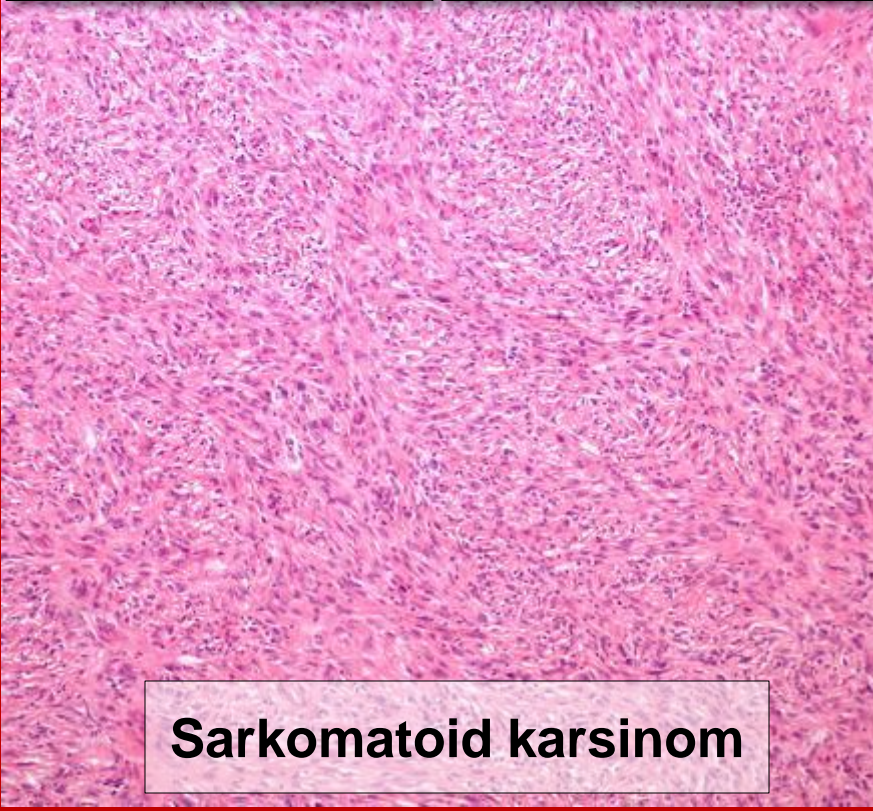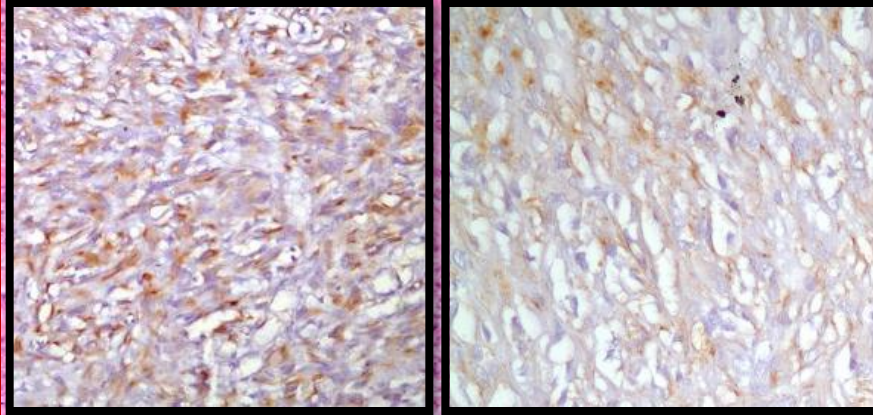
- **Fibromatozis**
- **Nodüler fasiit**
- **Sellüler fibröz histiyositom**
- **İğsi hücreli sarkomlar**
 - **MPNST**
 - **Soliter fibröz tümör**
 - **Sinovyal sarkom**
- **İğsi hücreli karsinom**
- **İğsi hücreli melanom**



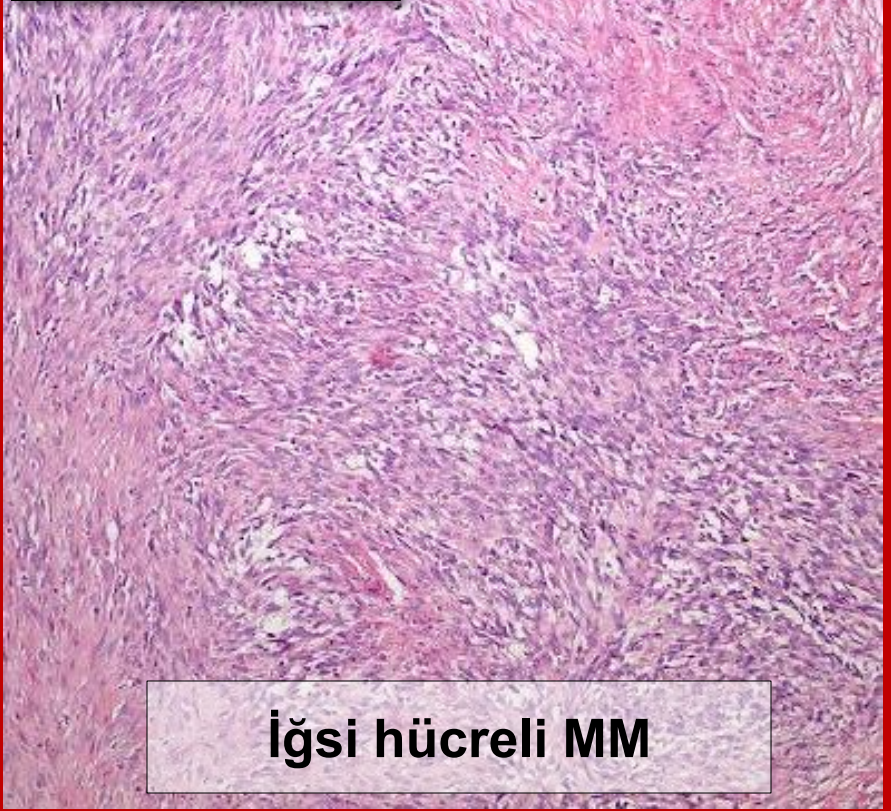
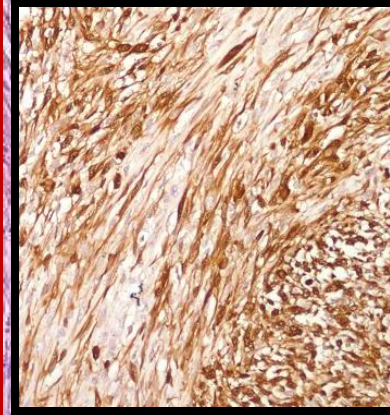
Soliter fibröz tümör



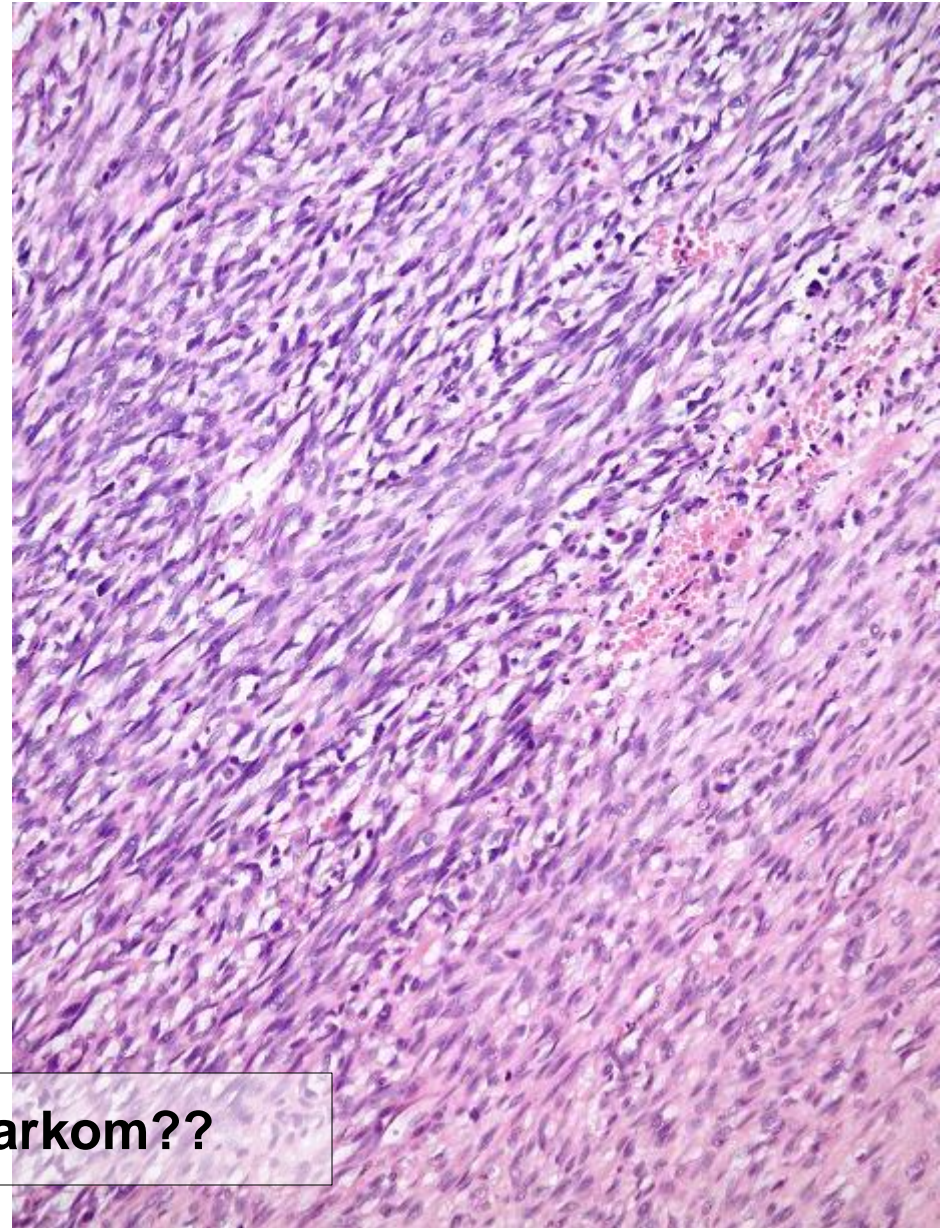
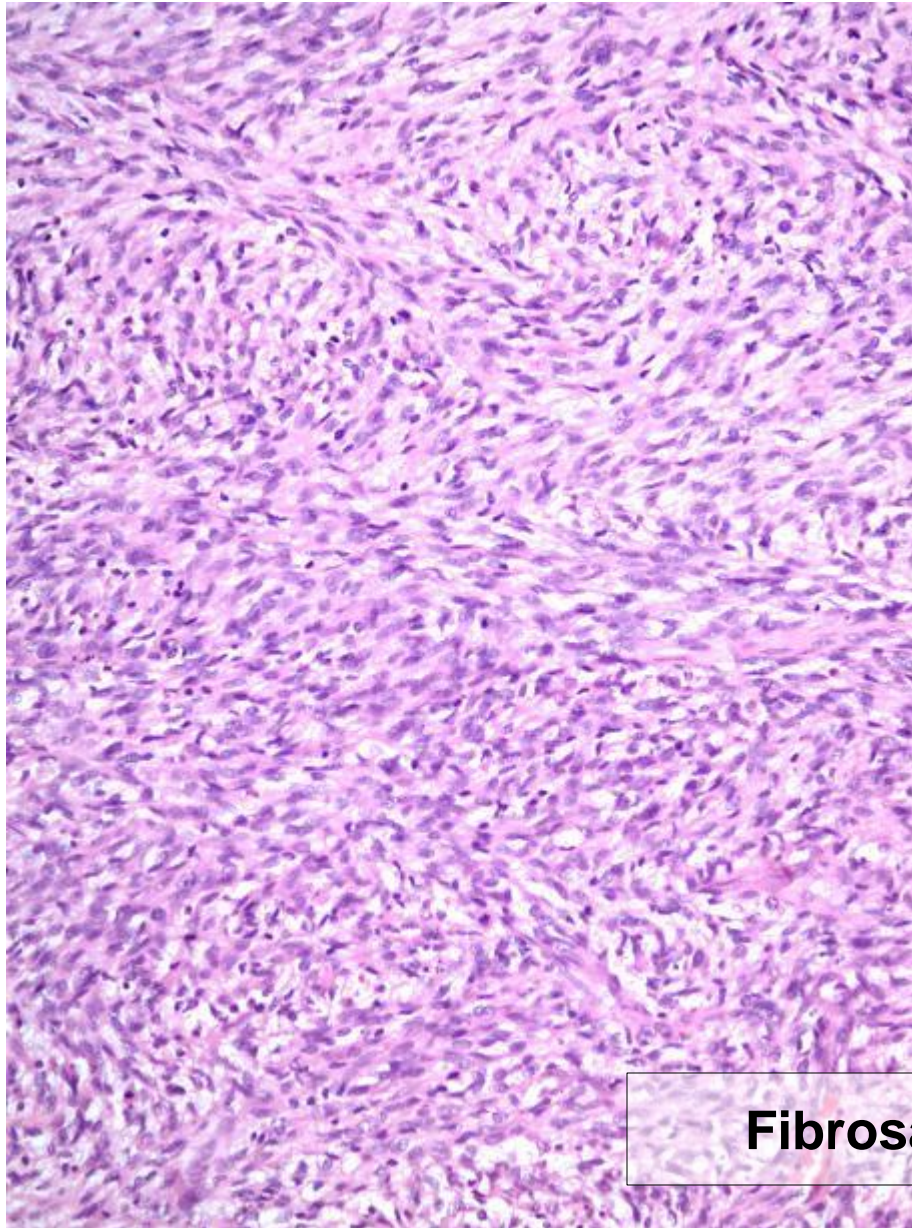
Sinovyal sarkom



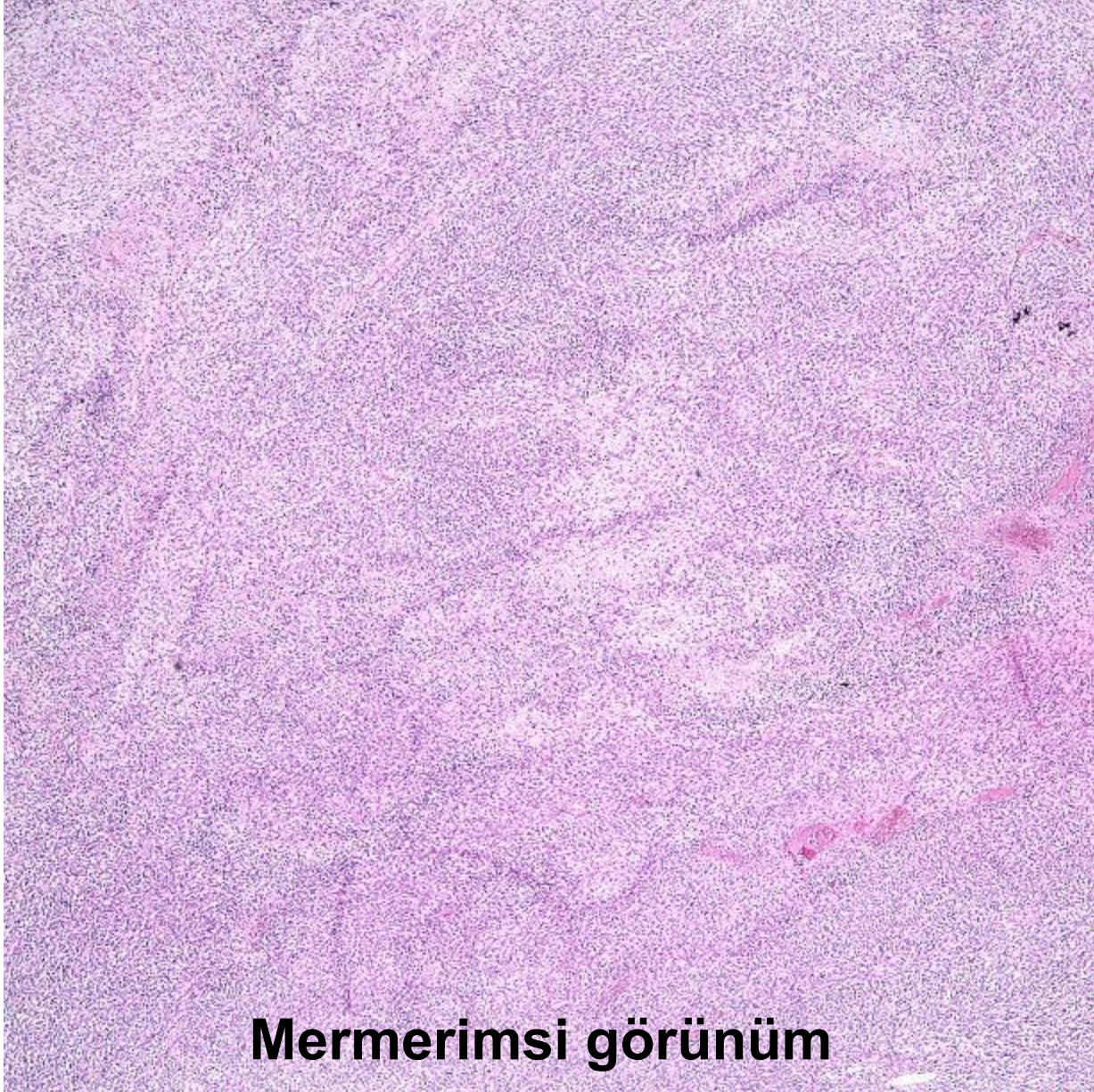Sarkomatoid karsinom



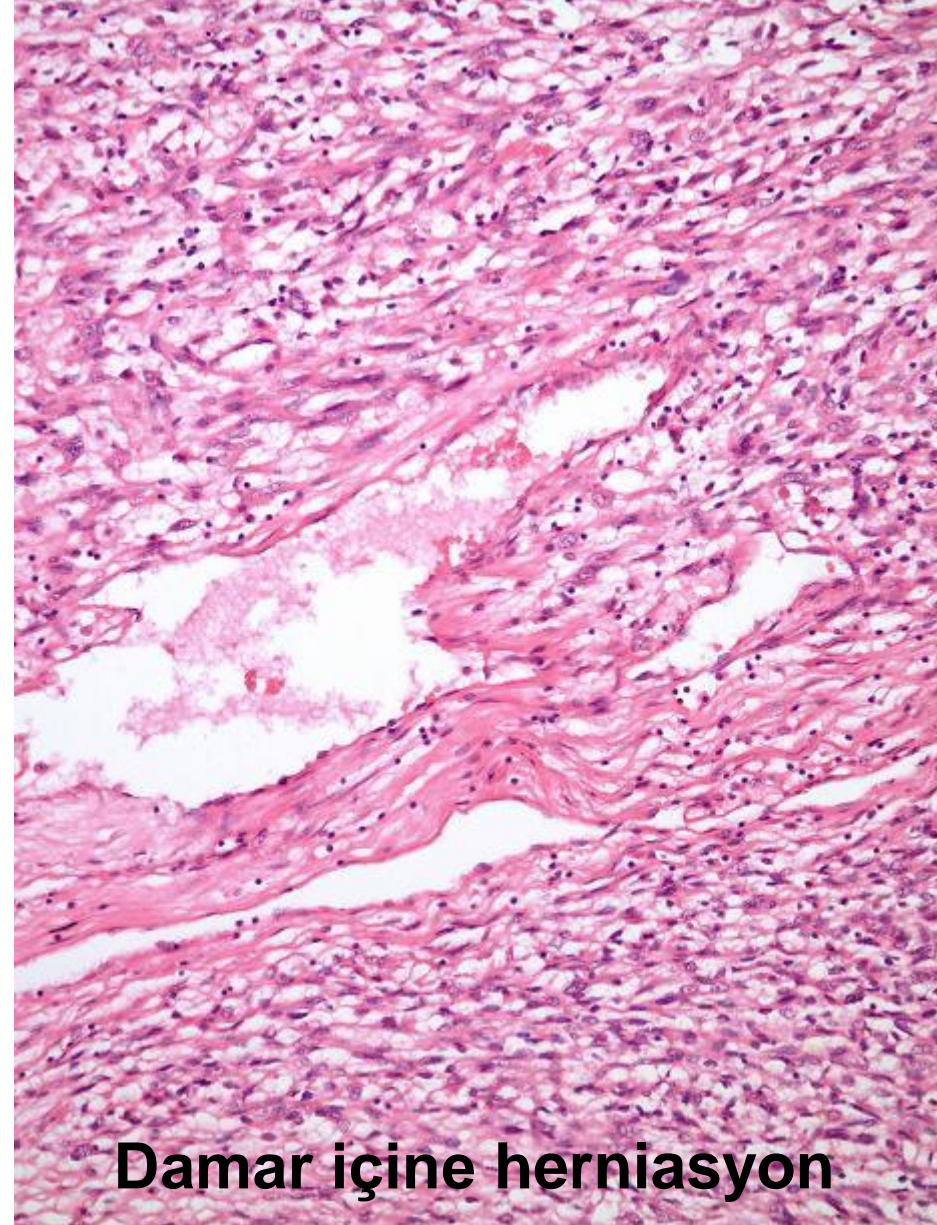
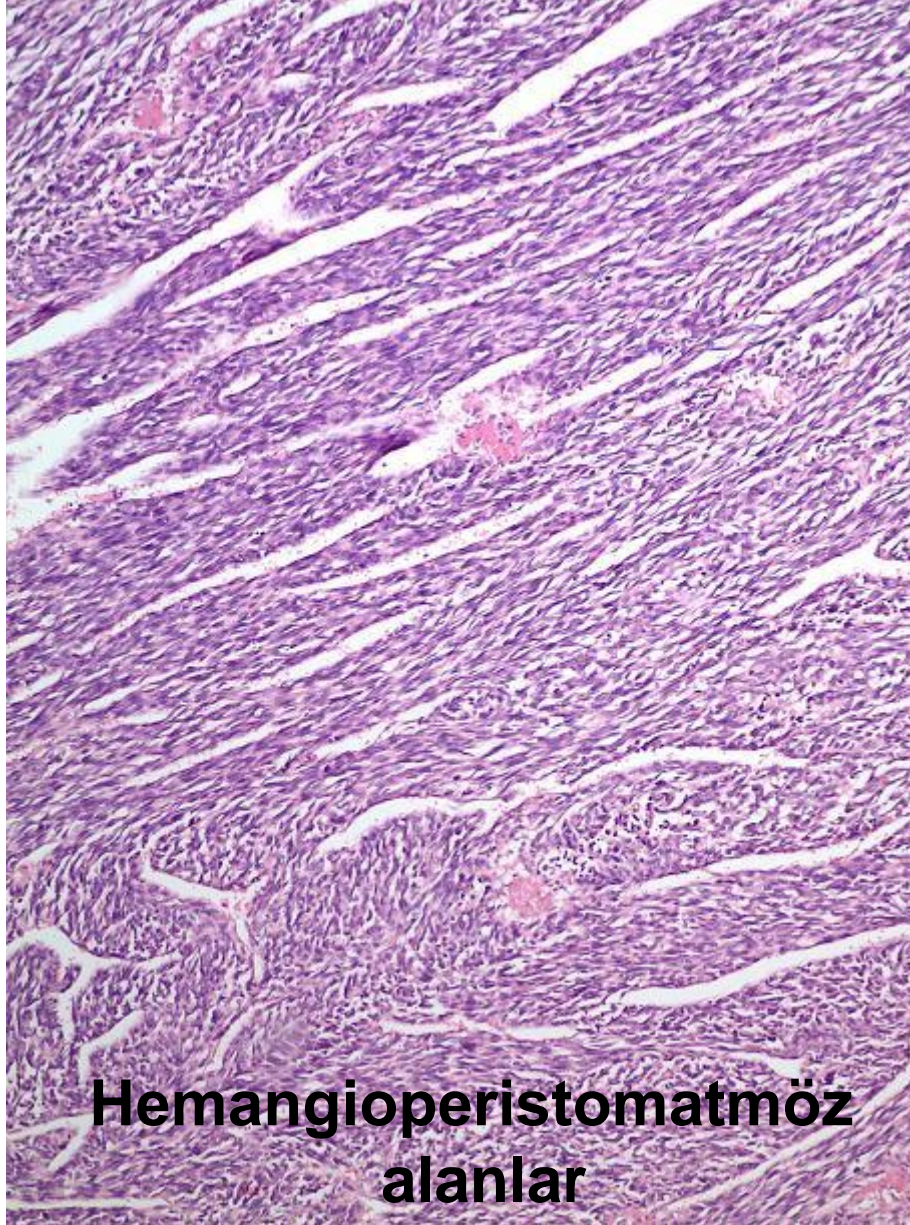
İğsi hücreli MM

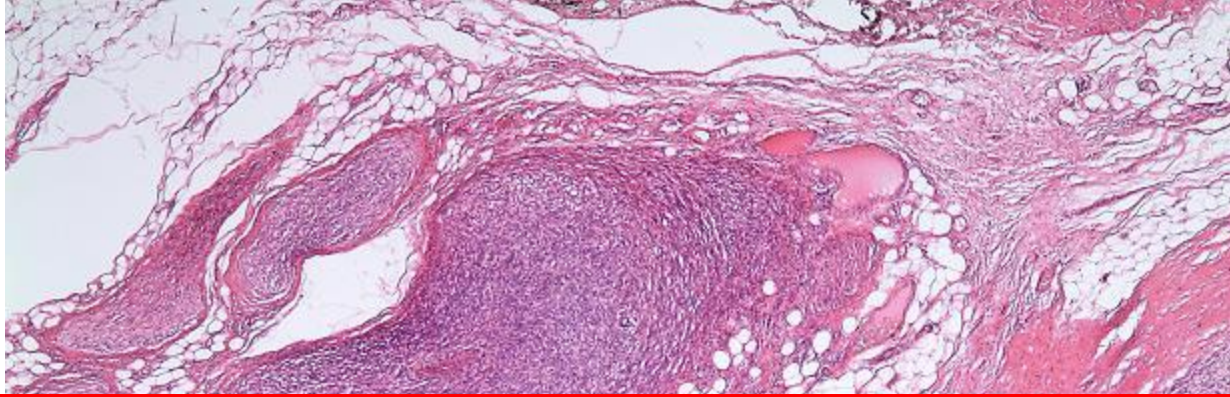


Fibrosarkom??

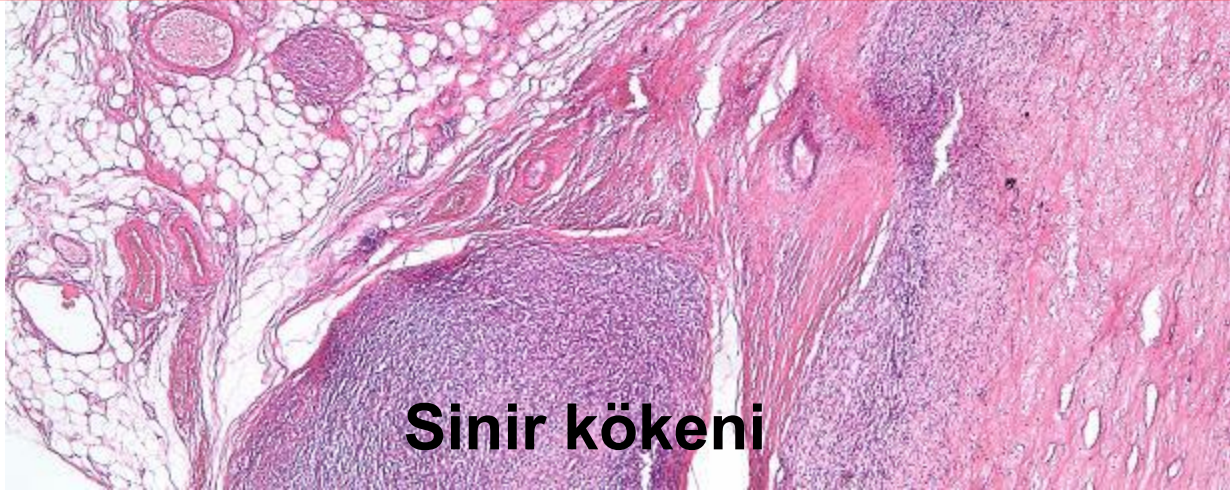

Mermerimsi görünüm

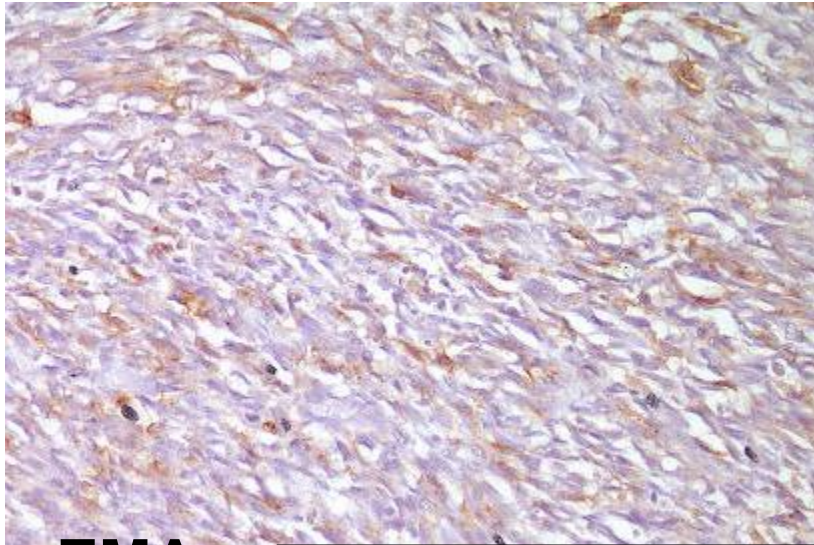




Makroskopik inceleme önemli!

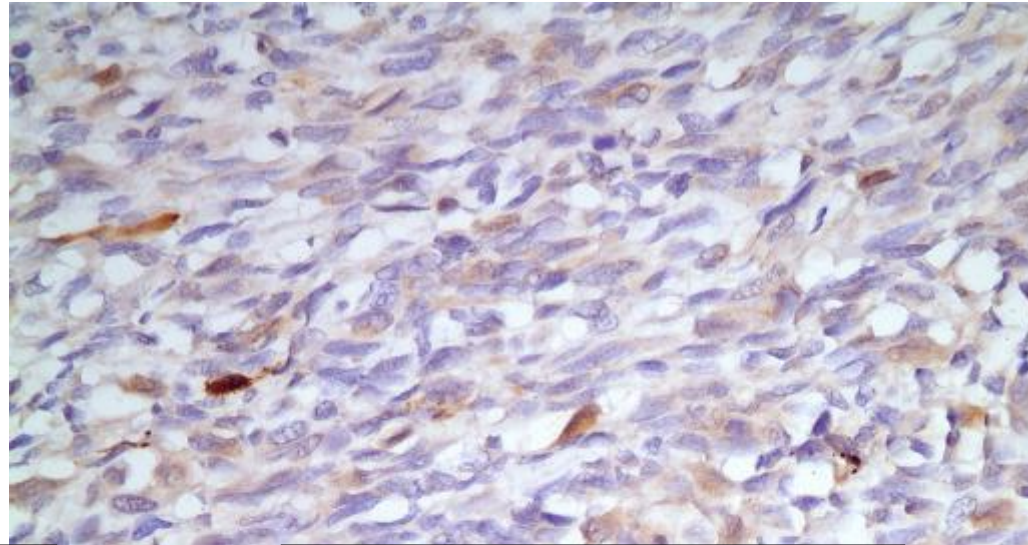


Sinir kökeni

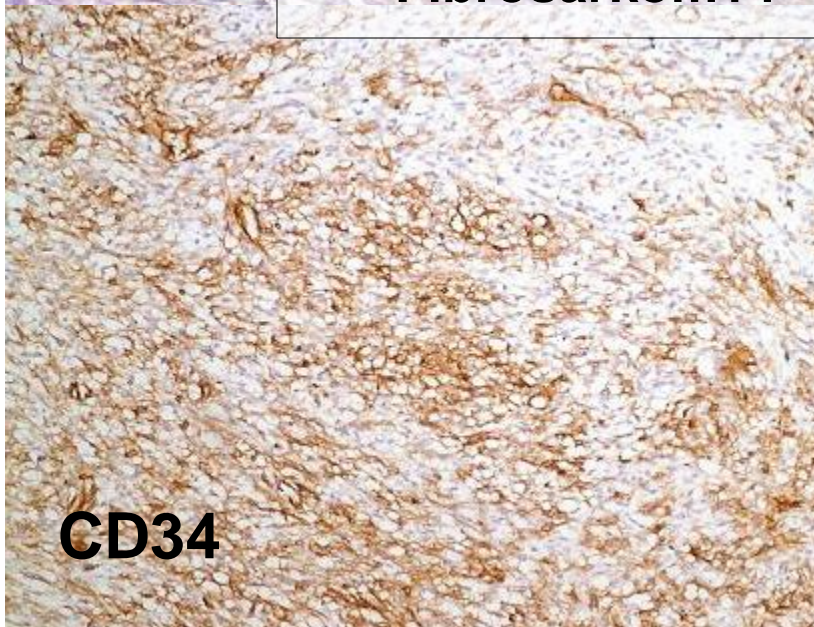



EMA

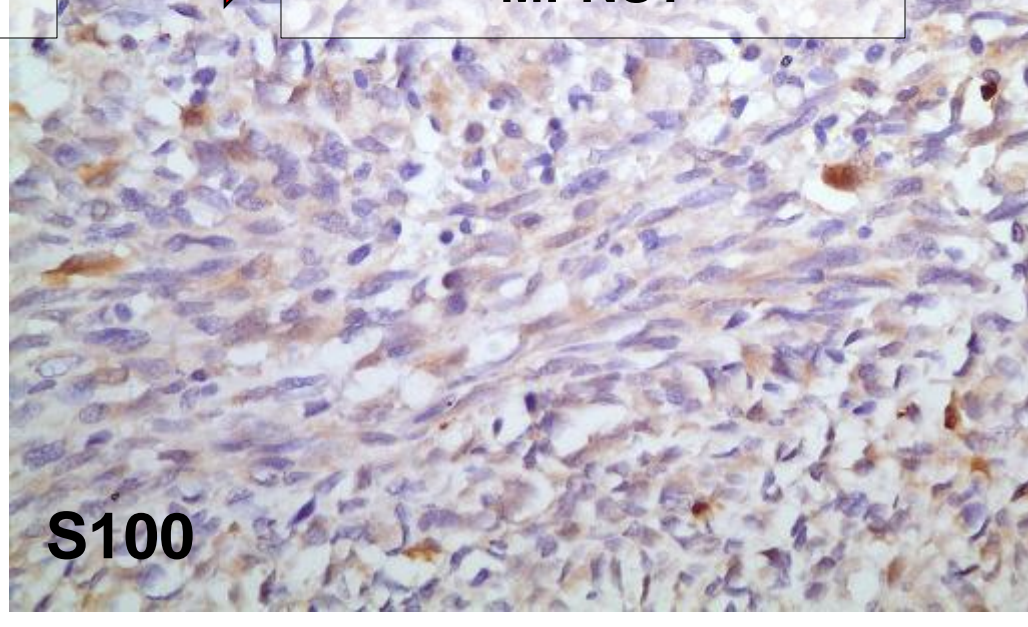
Fibrosarkom??



MPNST



CD34



S100

Fibrosarkom

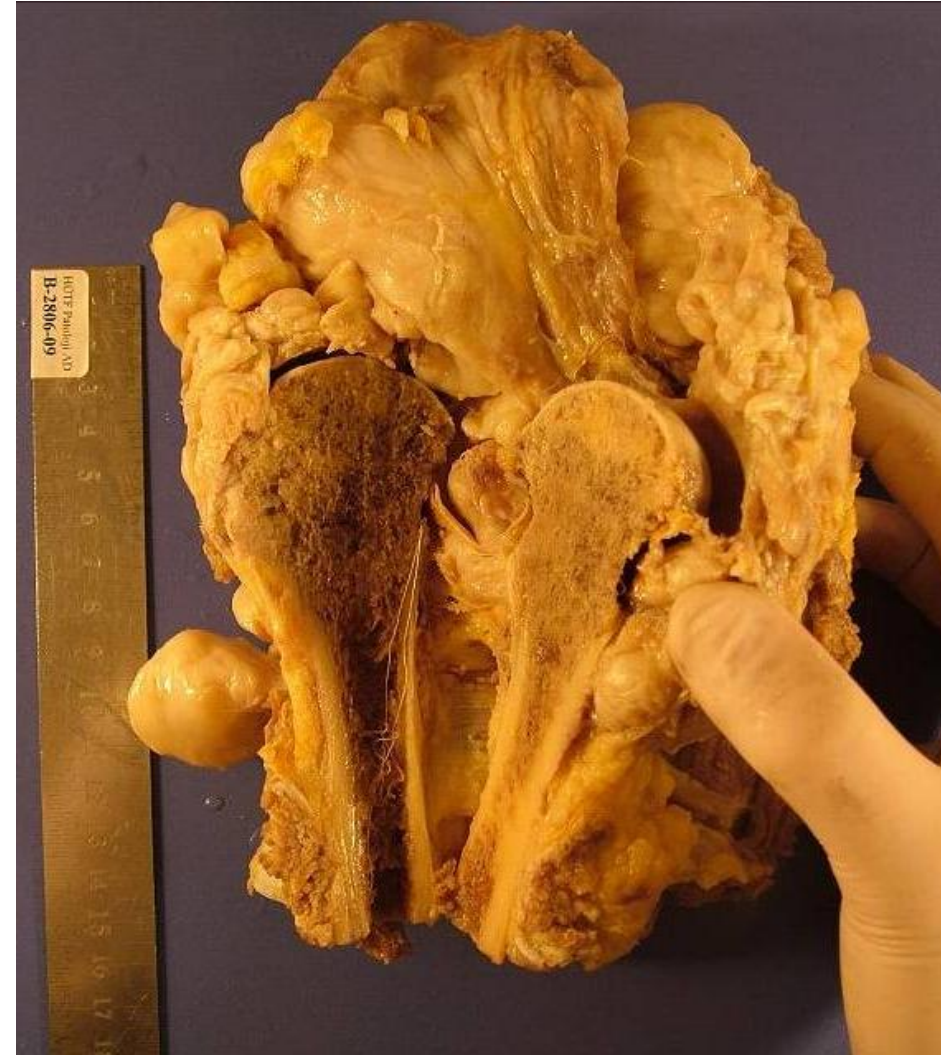
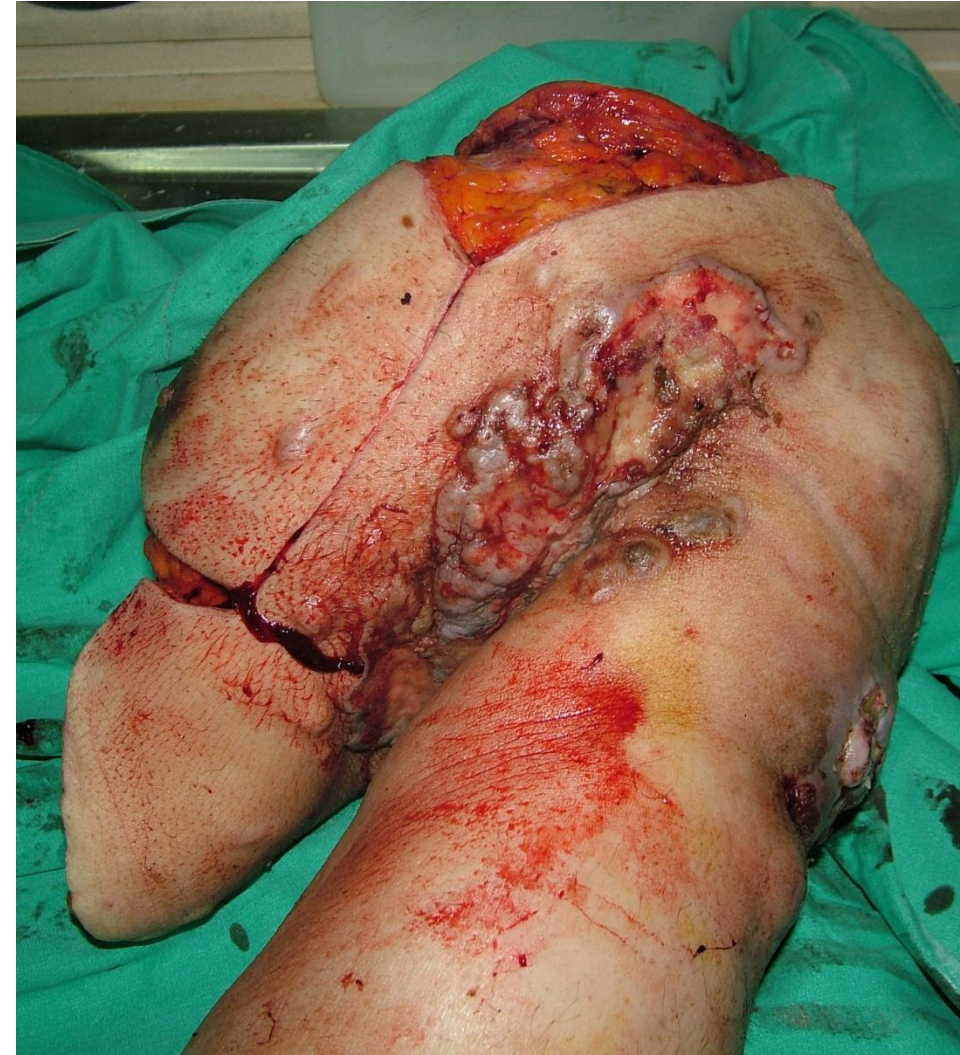Alt Tipleri

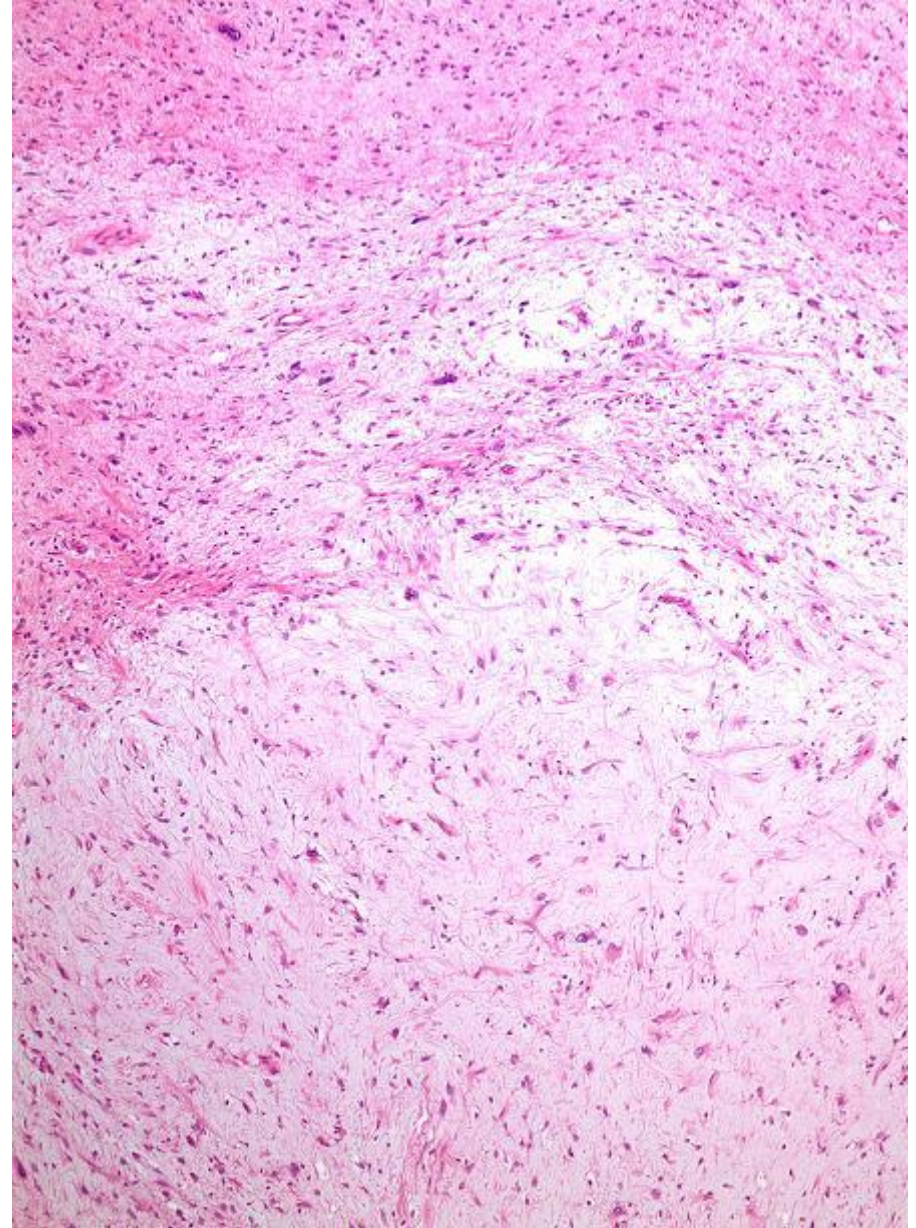
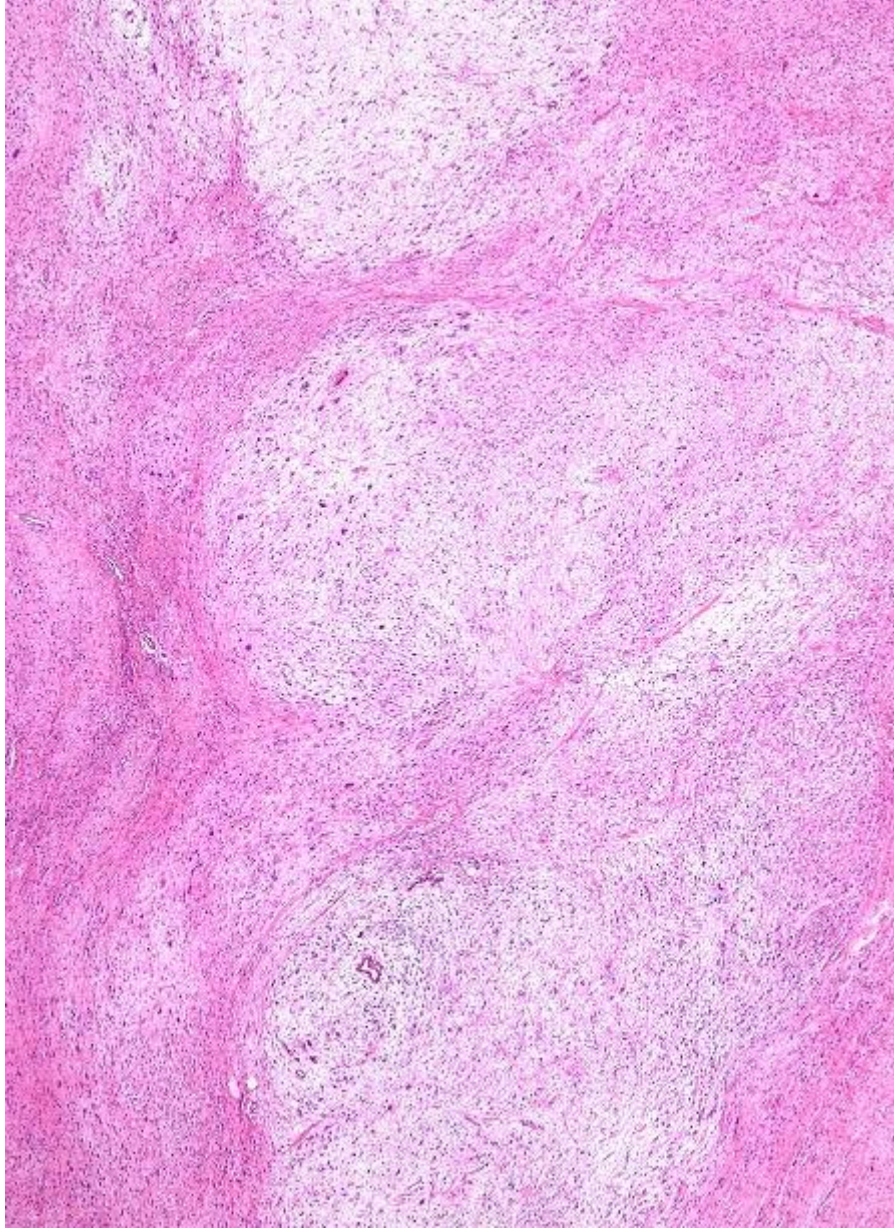
- Mikzofibrosarkom
- Düşük dereceli fibromikzoid sarkom
- Sklerozan epitelioid fibrosarkom

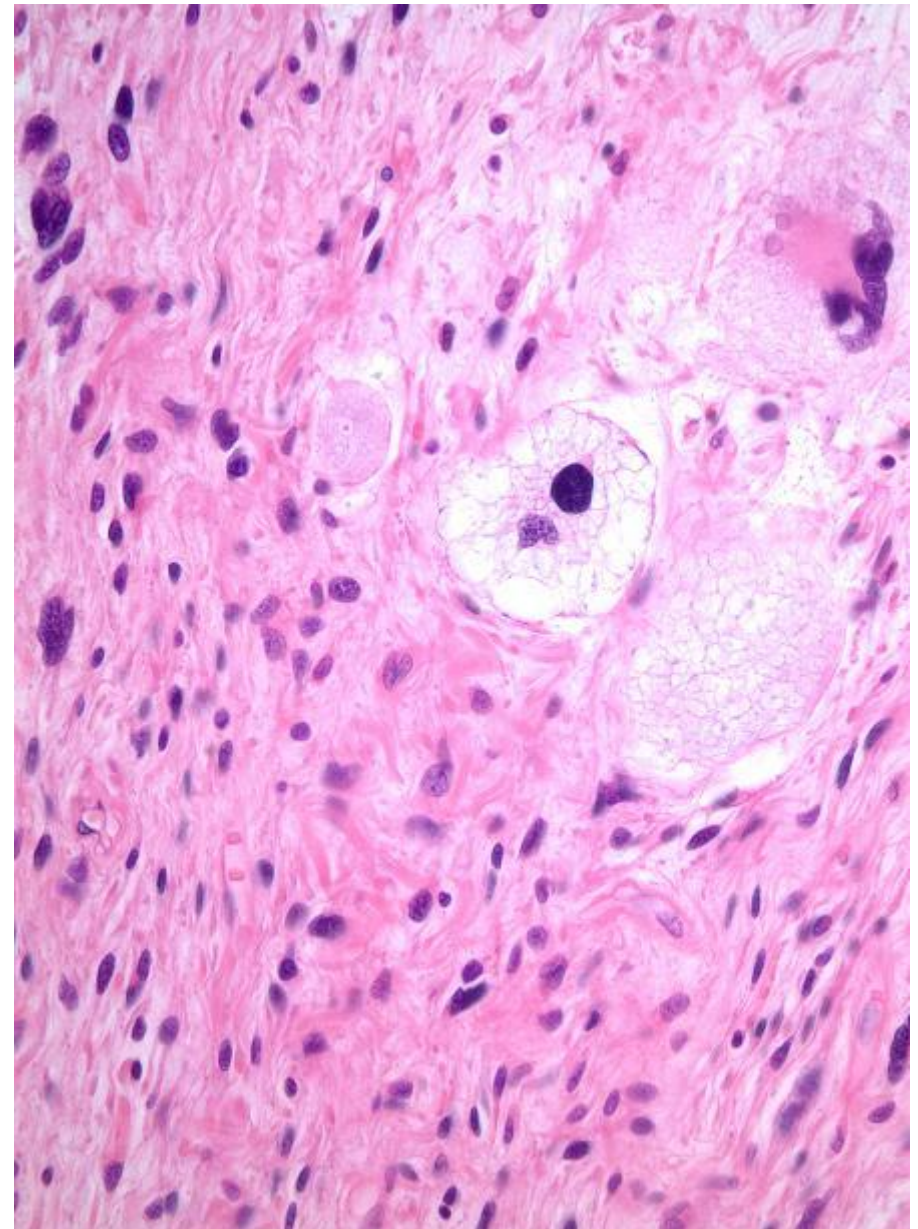
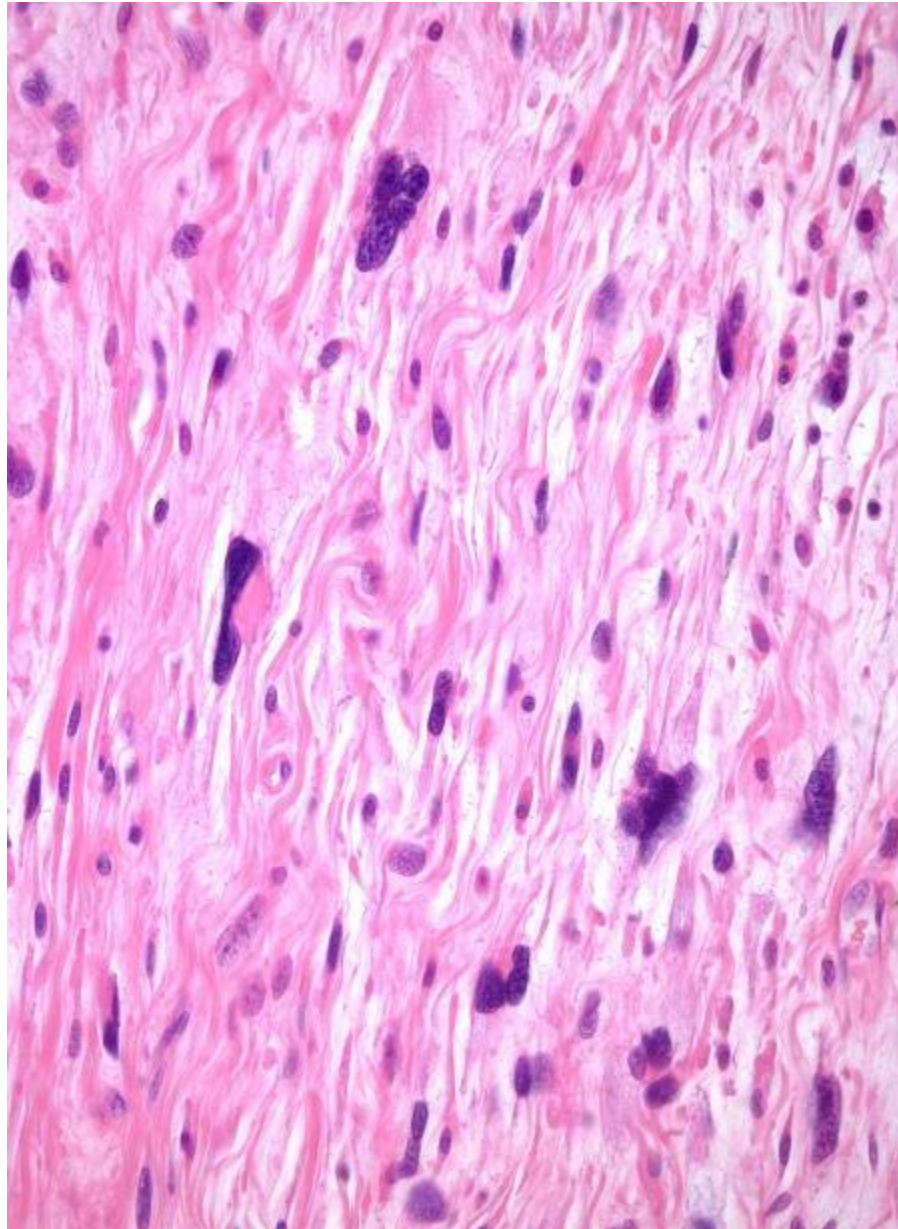
Case 6

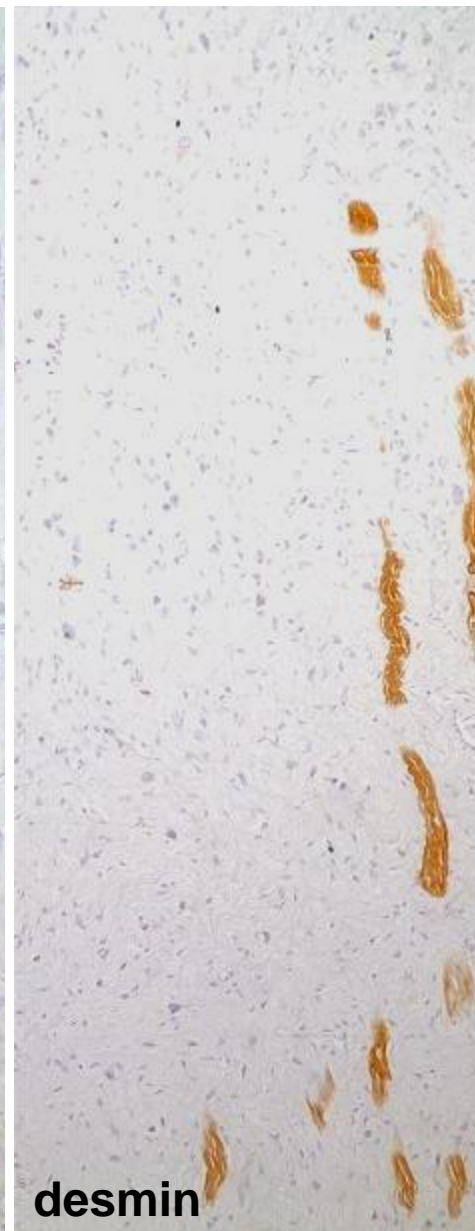
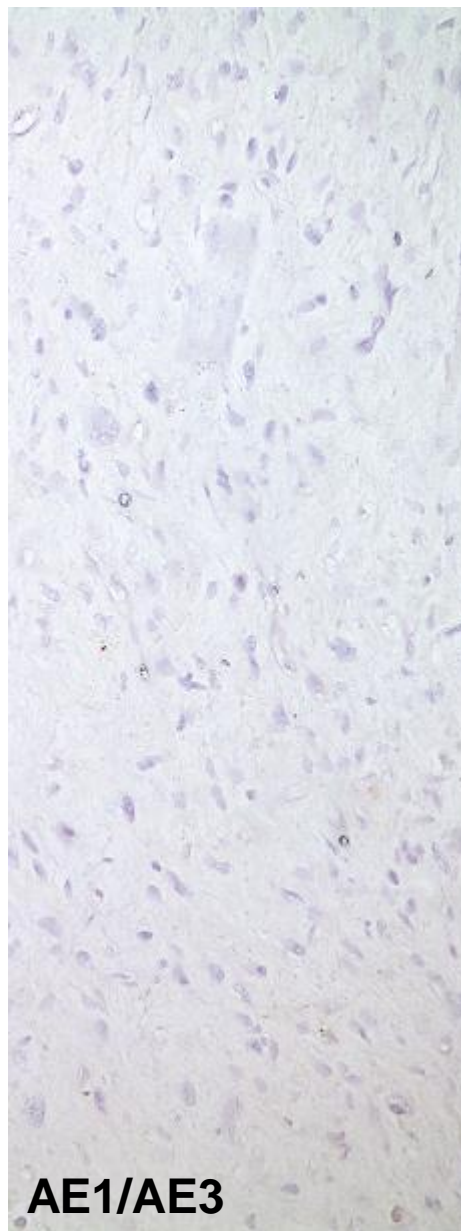
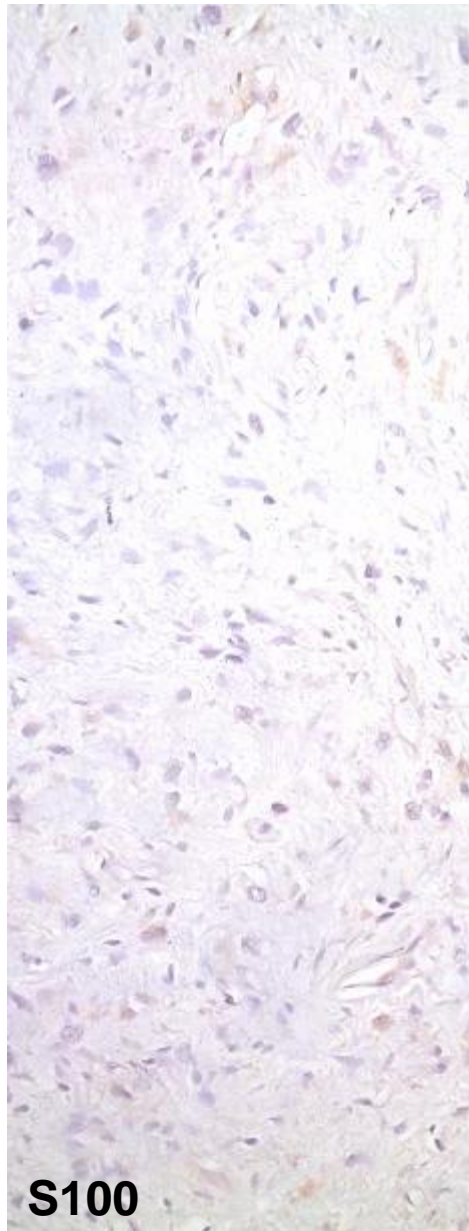
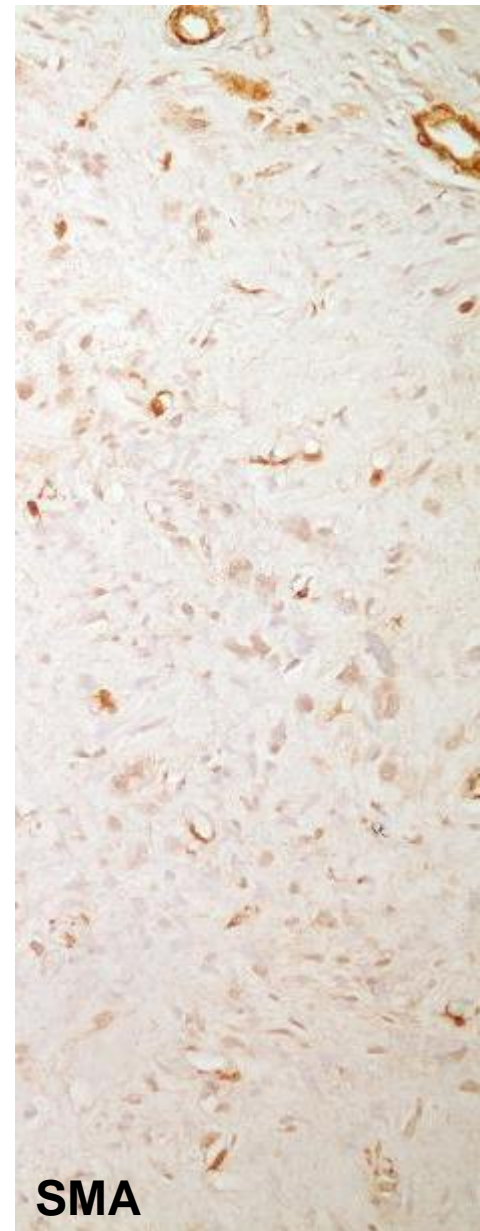
65 y ♂

Sol omuzda kitle





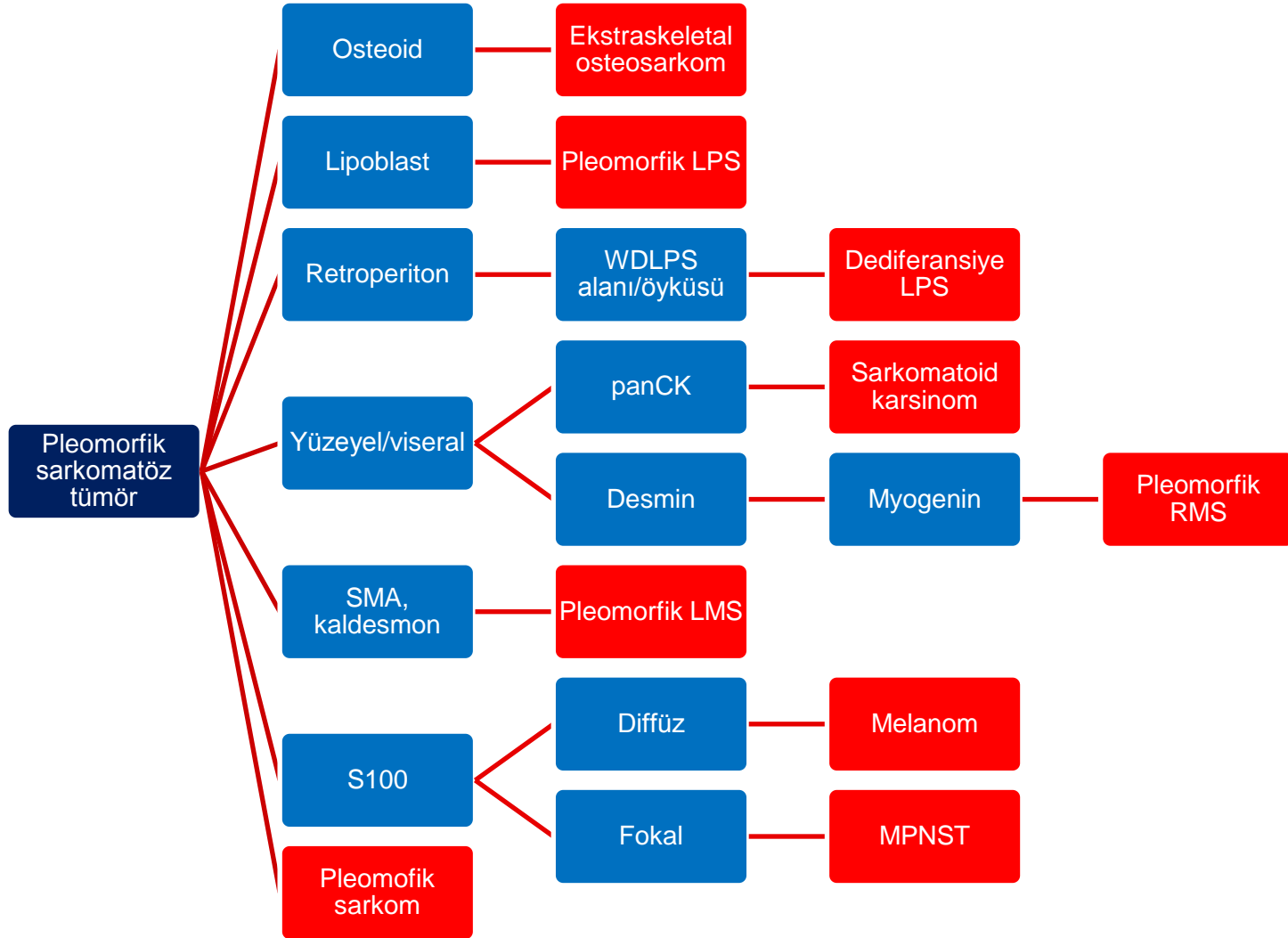




TANI:

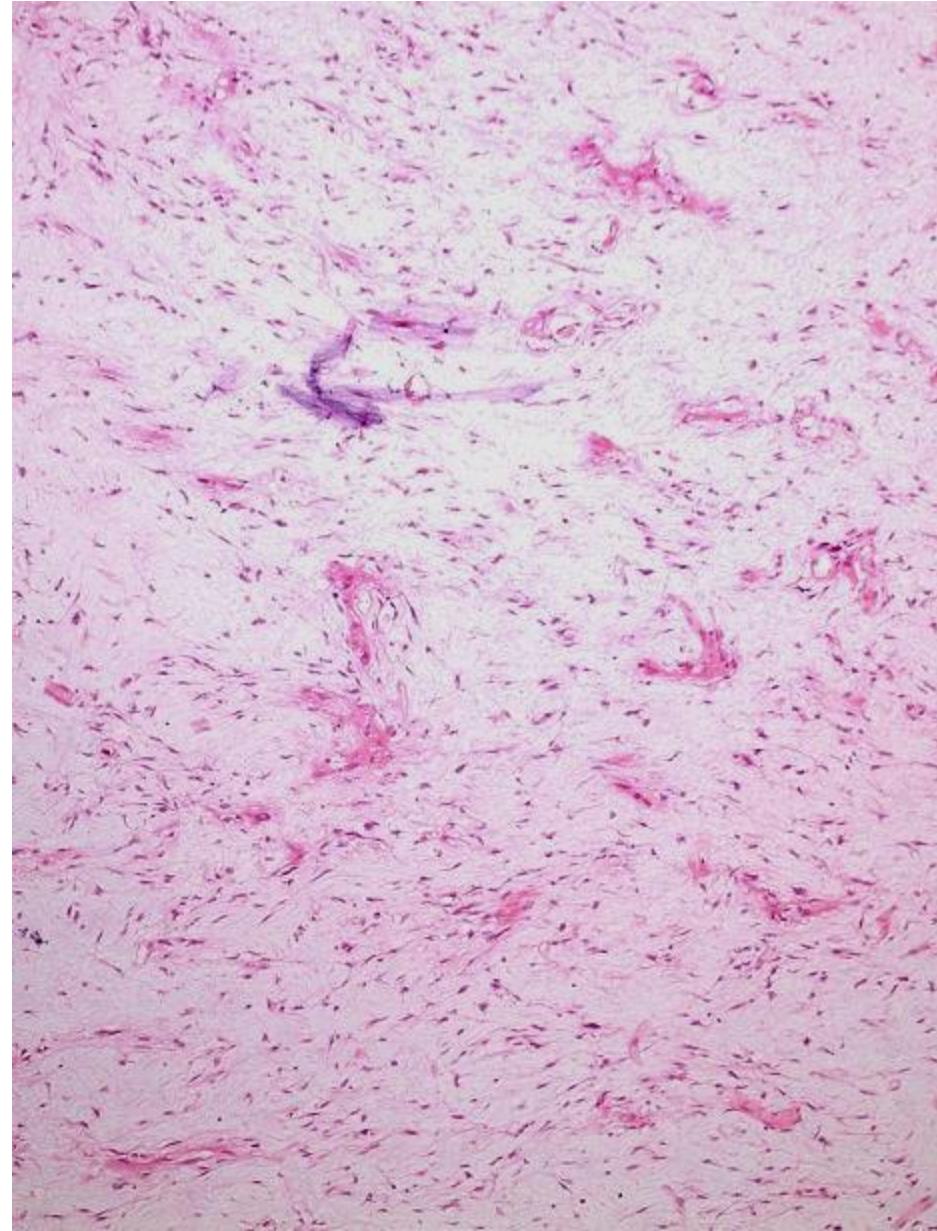
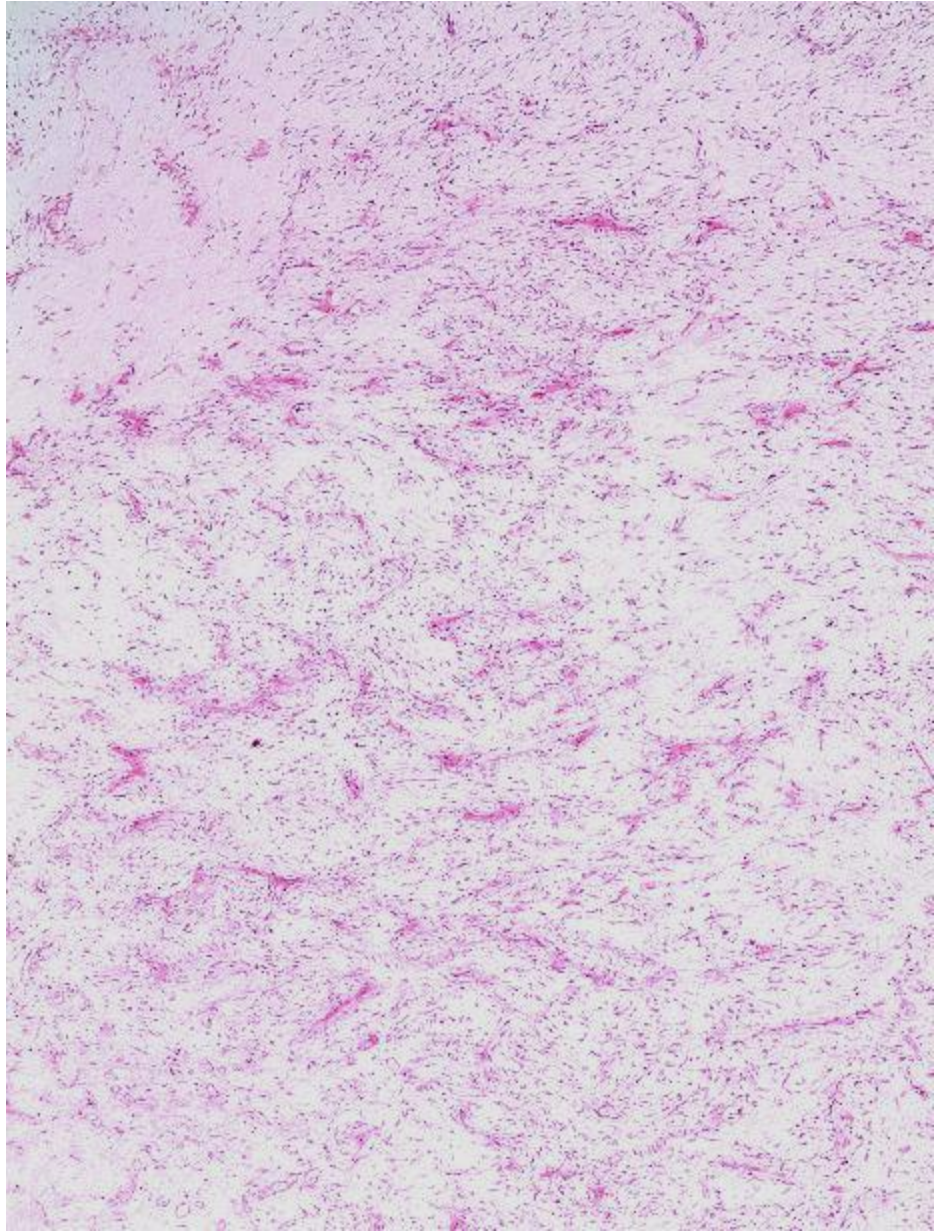
**Yüksek dereceli mikzofibrosarkom
(İndiferansiye pleomorfik sarkom)**

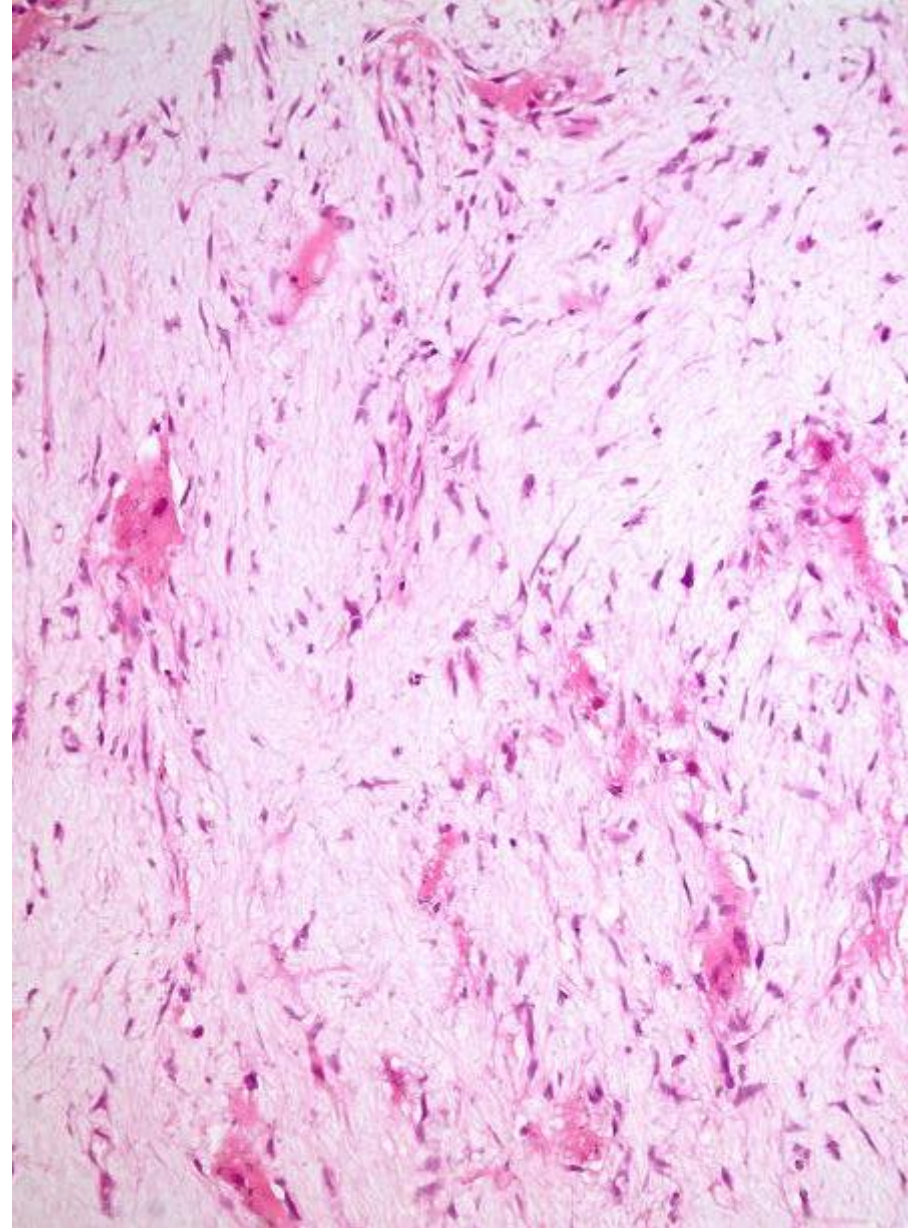
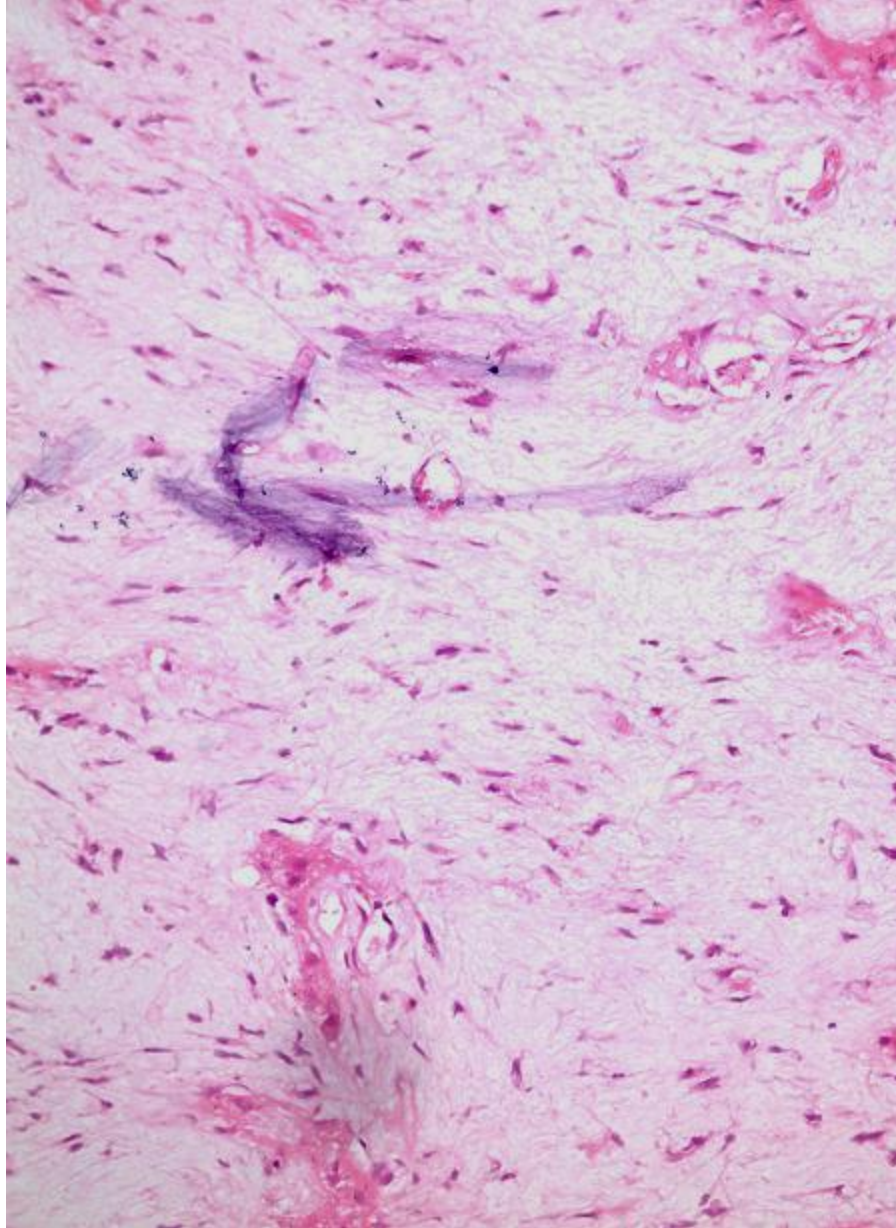
Pleomorfik sarkomlar

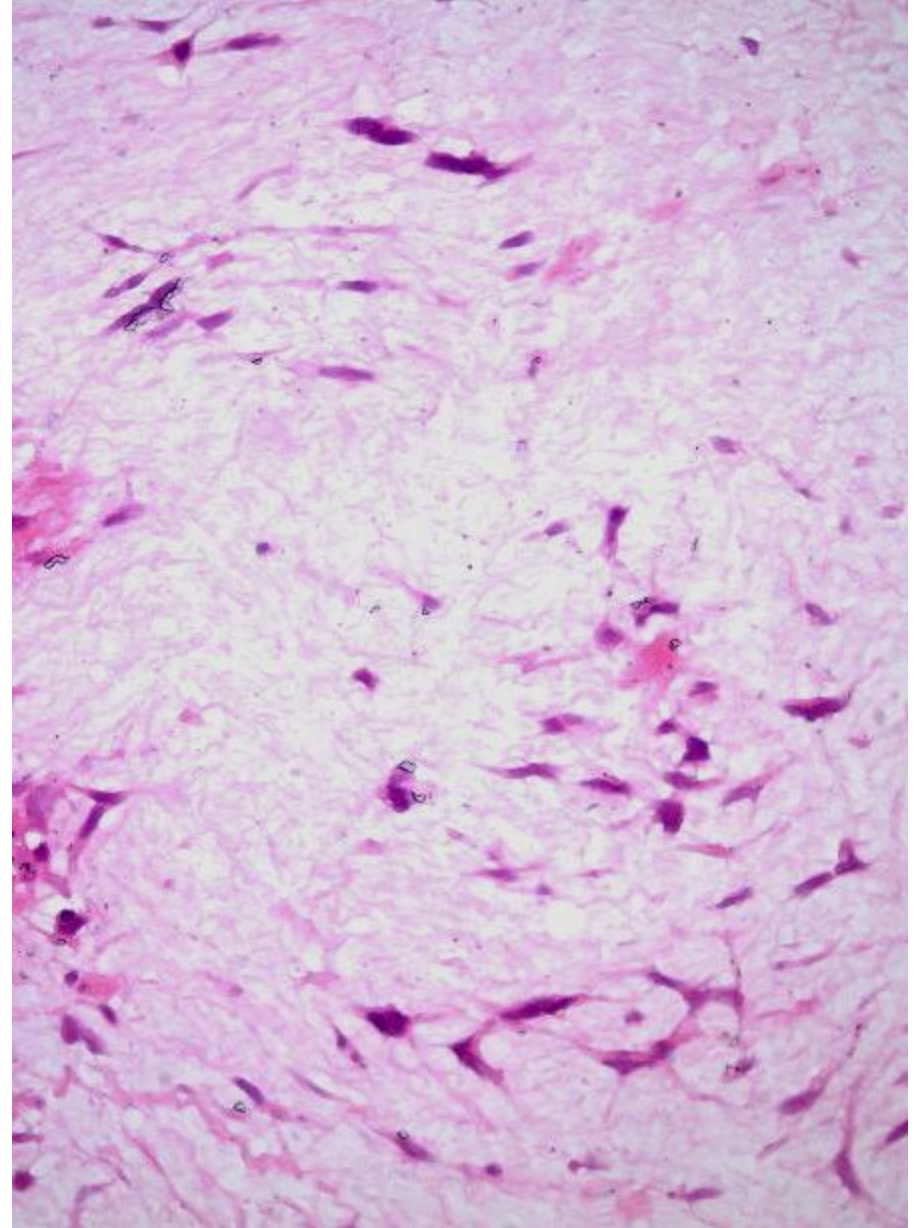
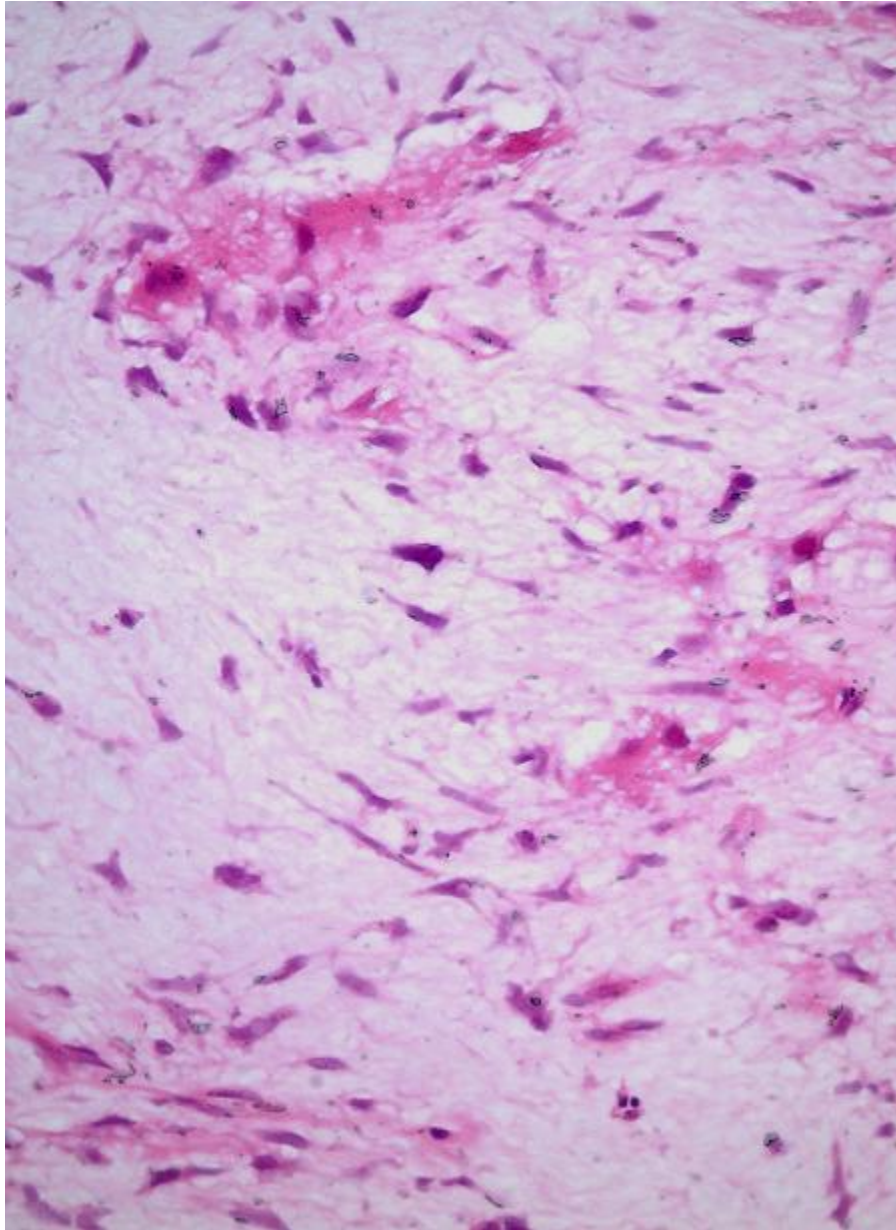


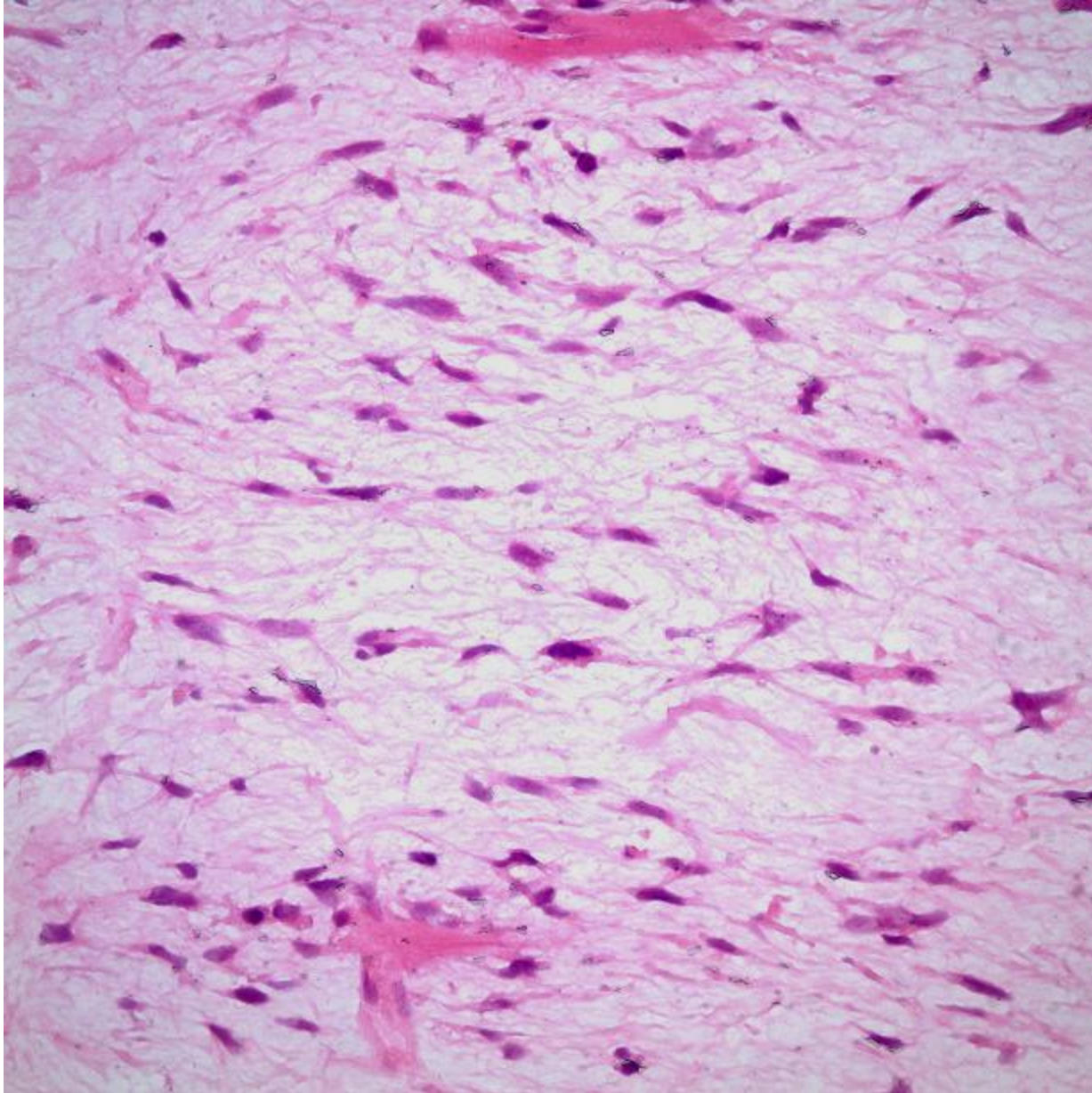


Case 7









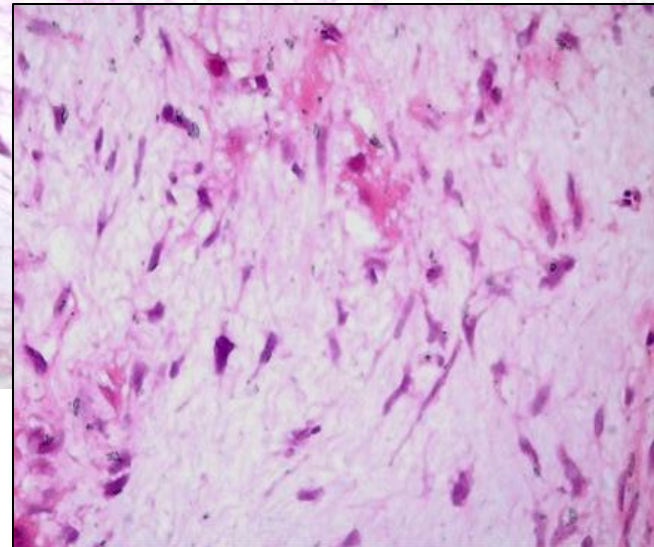
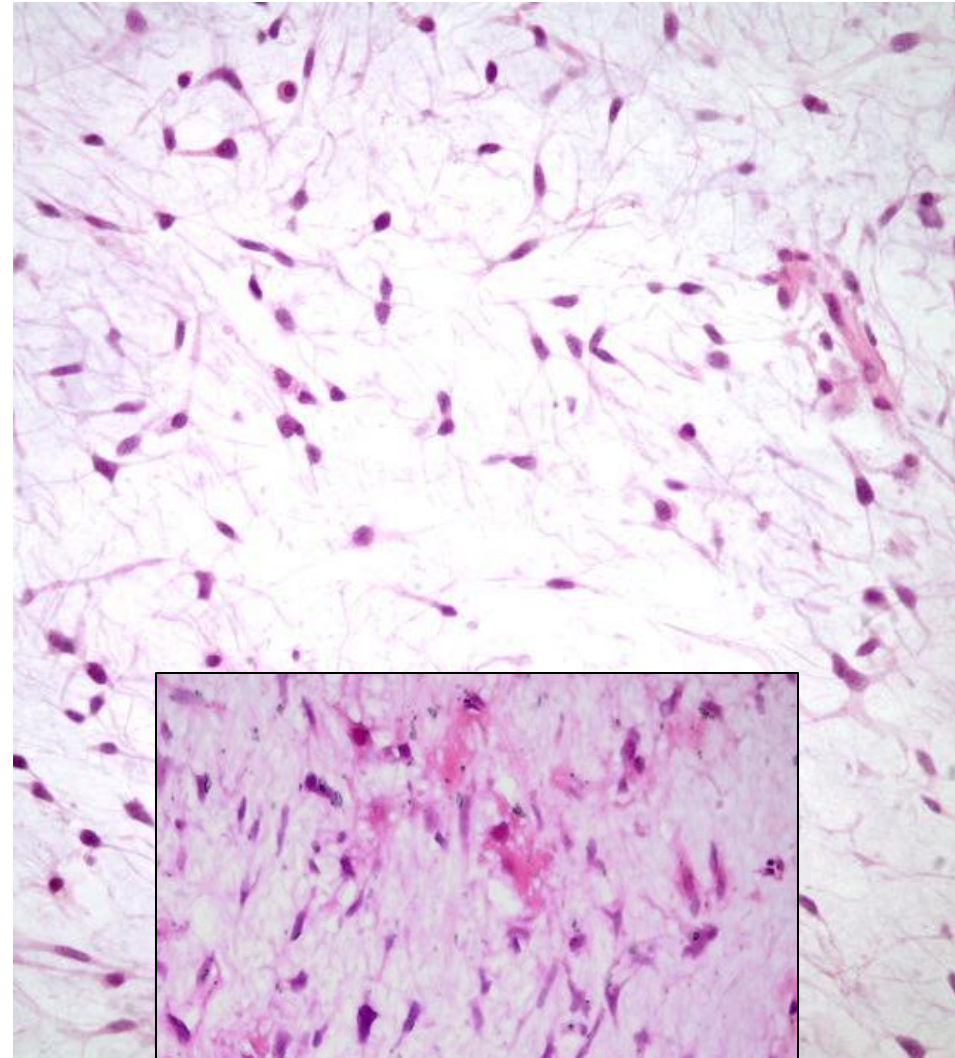
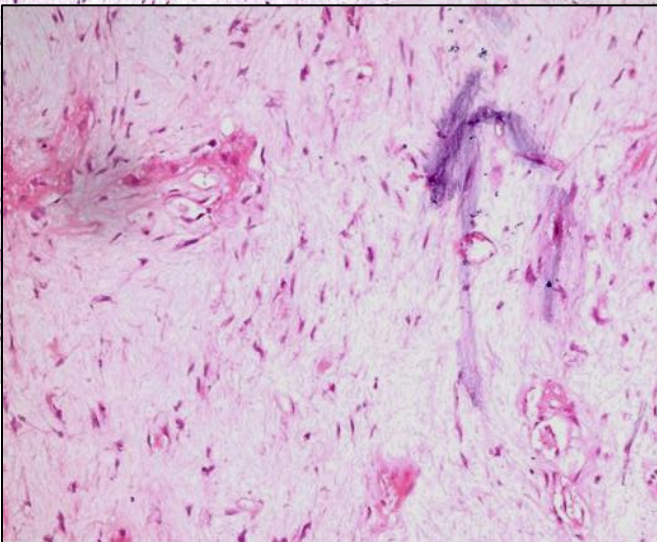
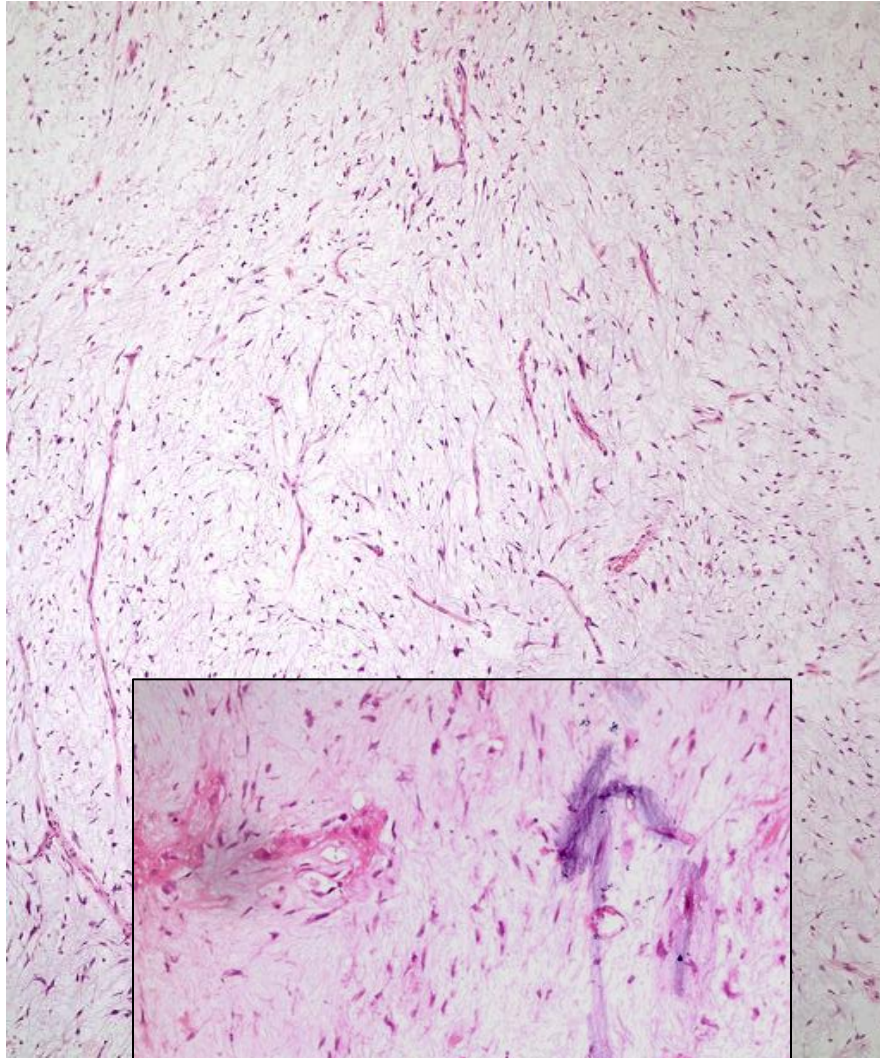
TANI:
Düşük dereceli
mikzofibrosarkom

Mikzofibrosarkom

DDx

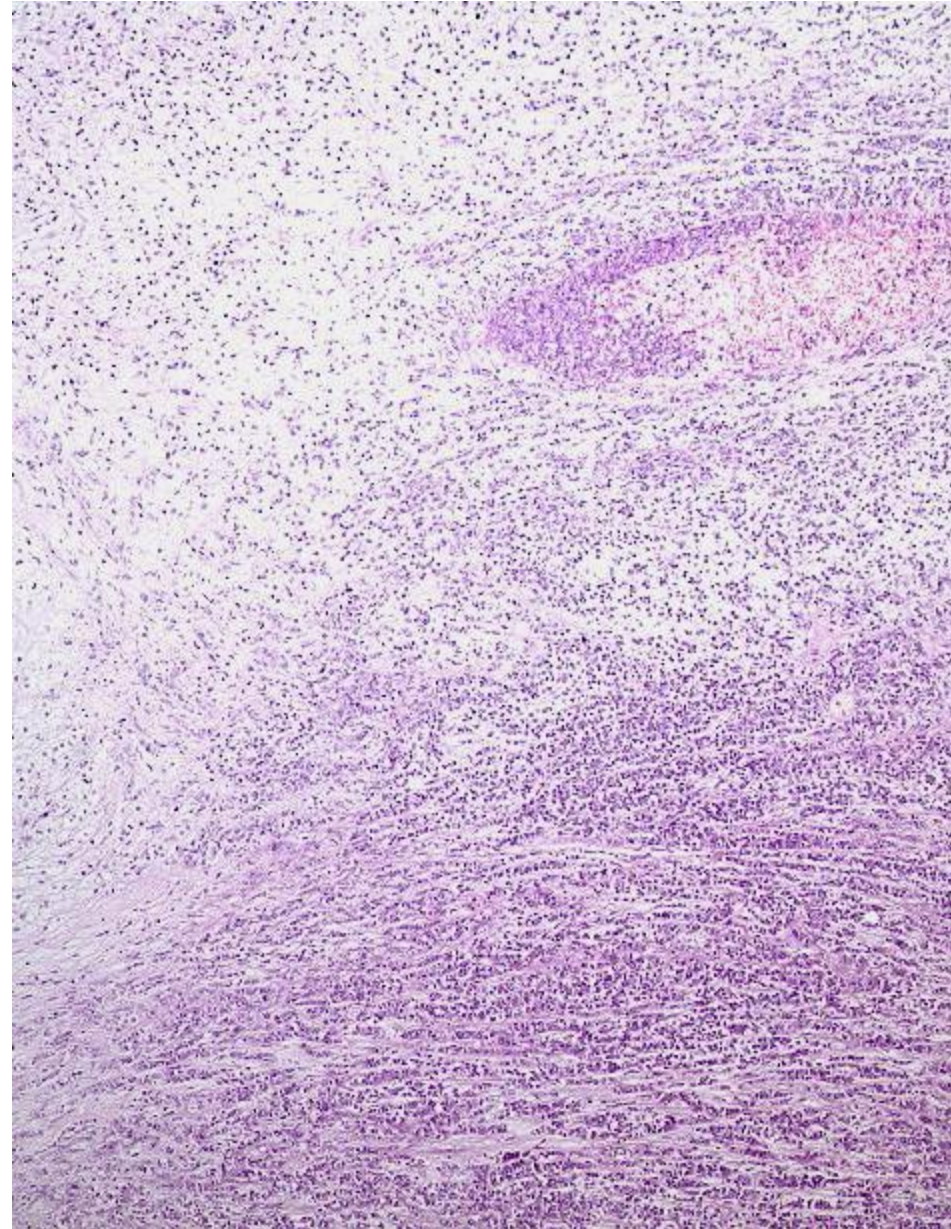
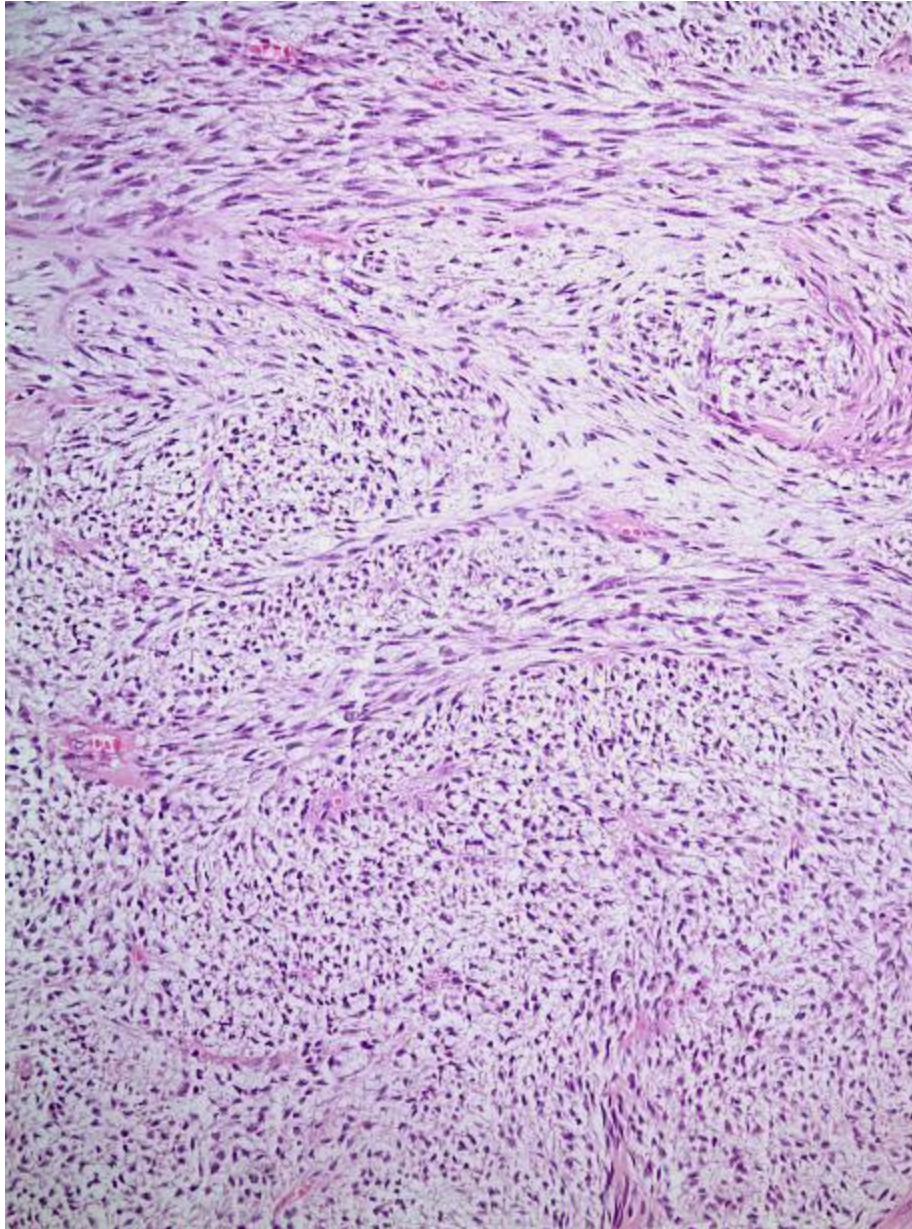
- Mikzoma
- Nodüler fasiit
- Mikzoid liposarkom

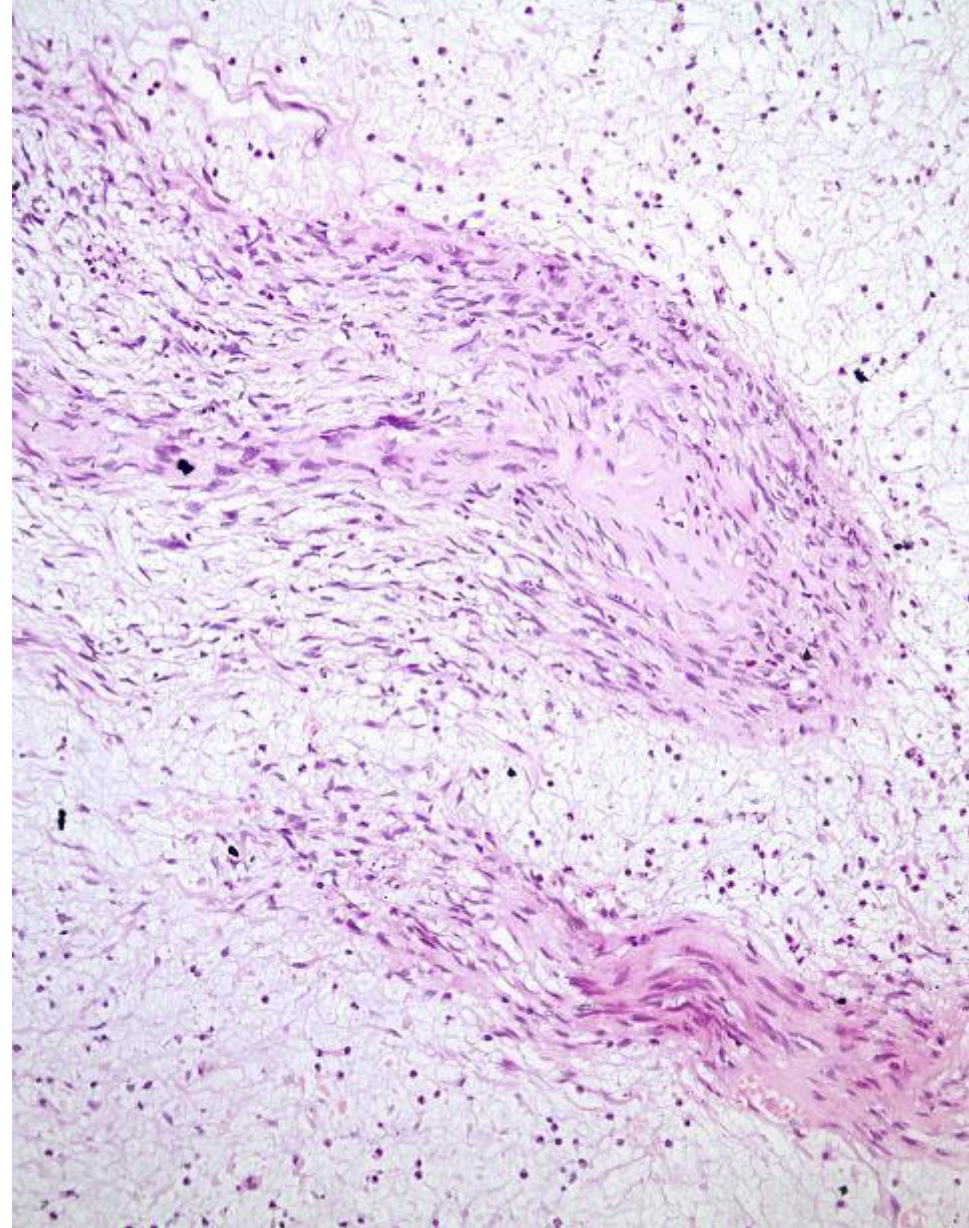
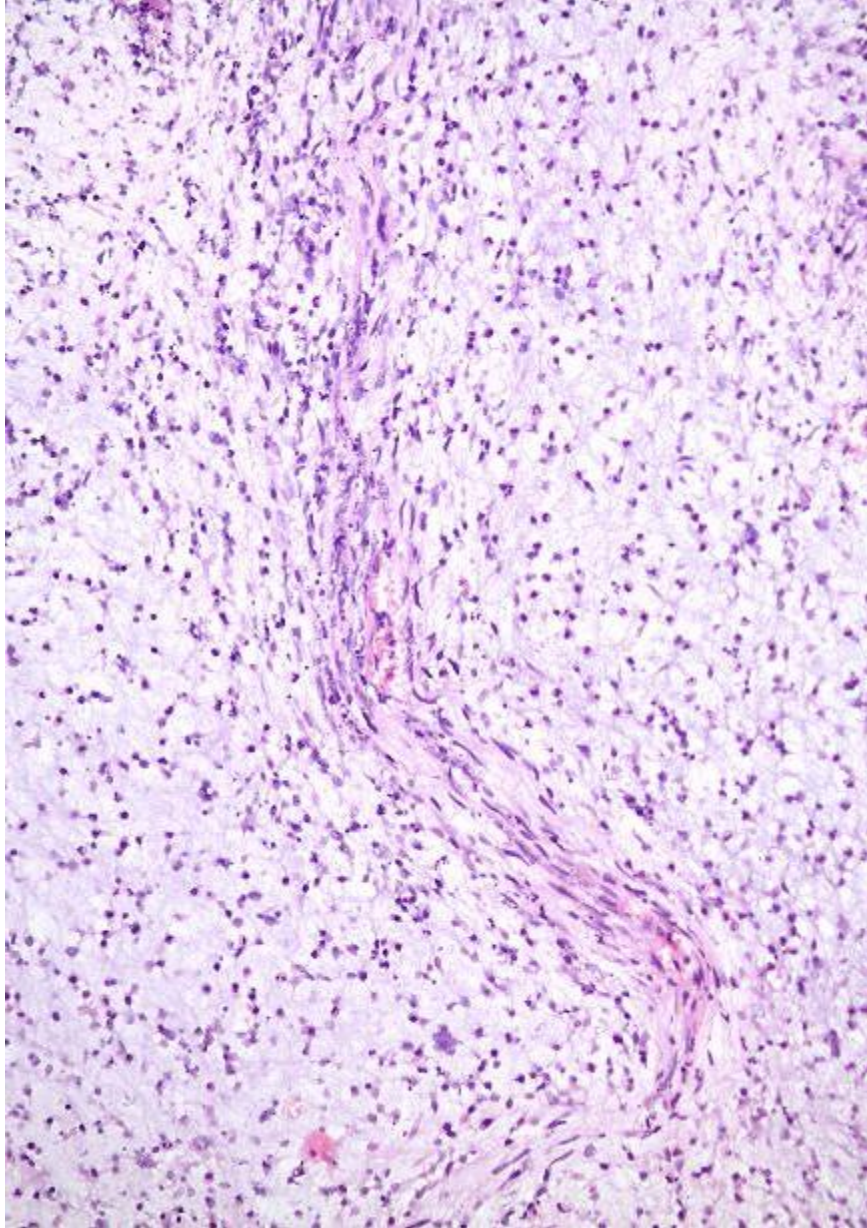
Mikzoid liposarkom

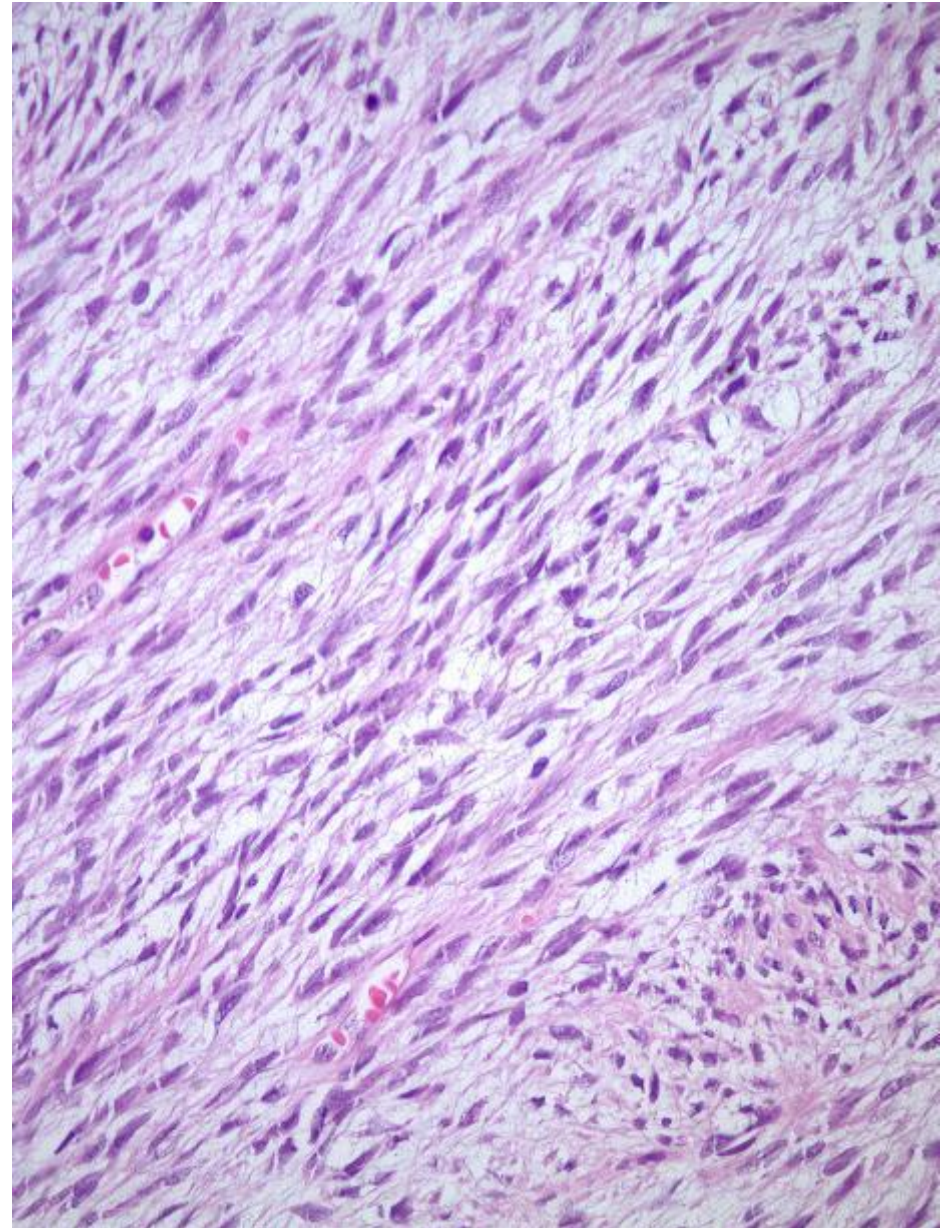
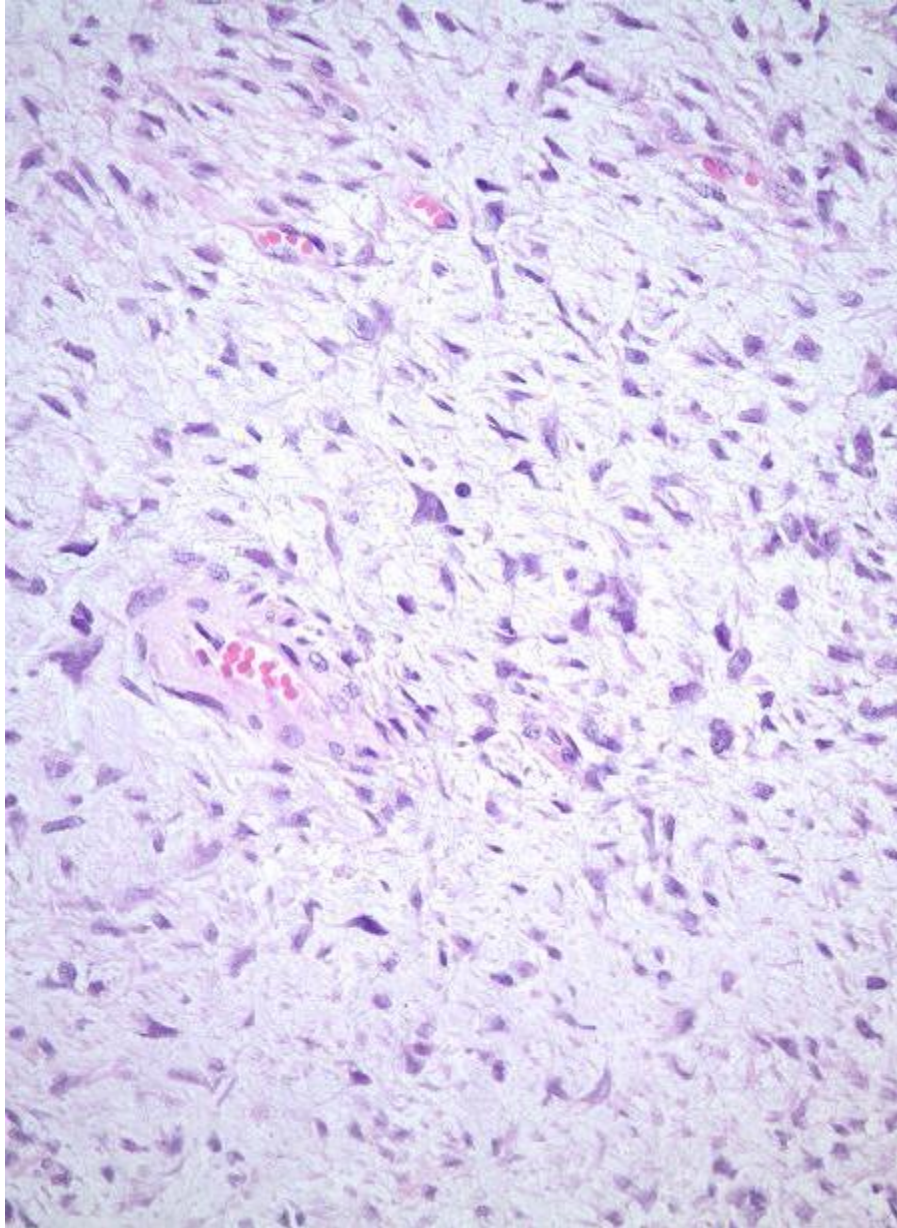


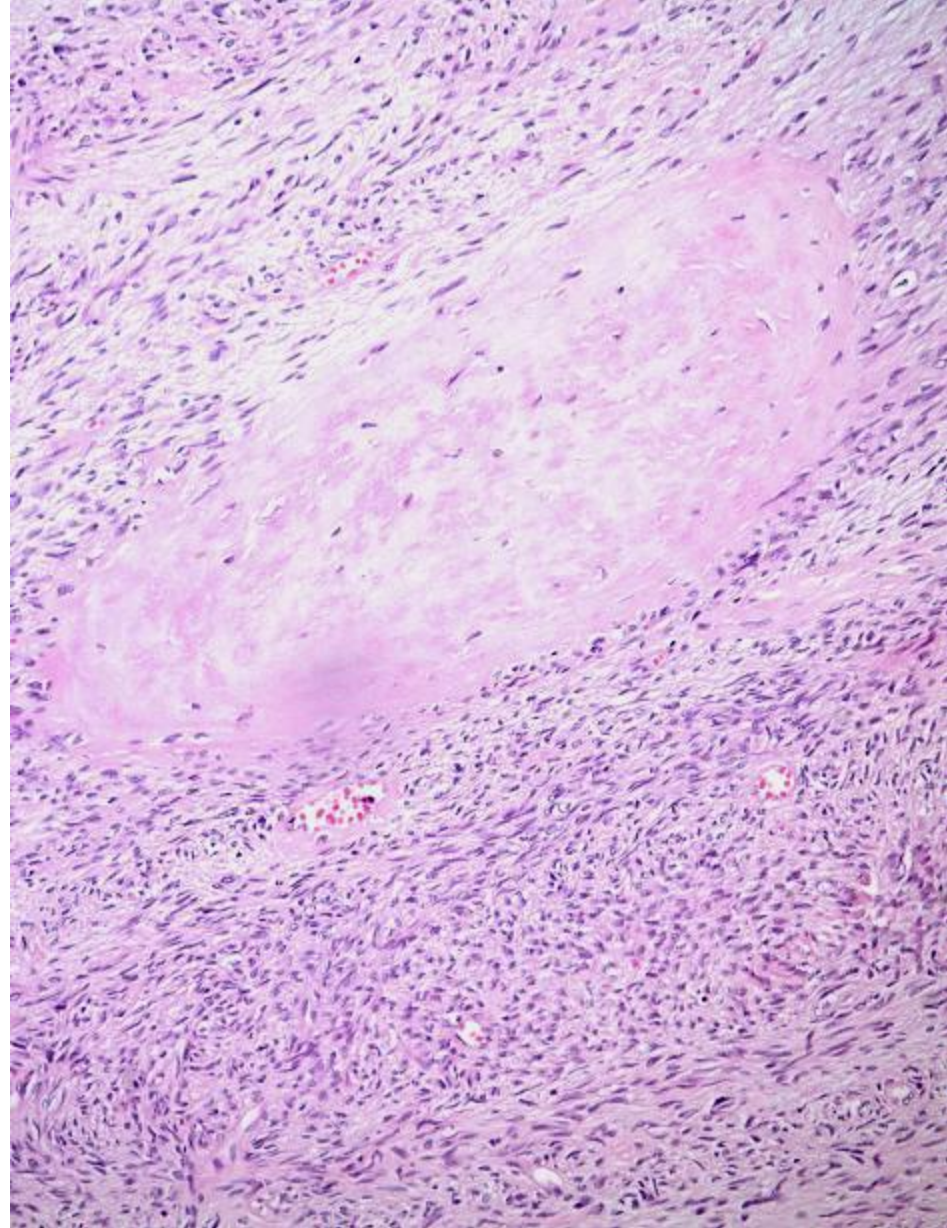
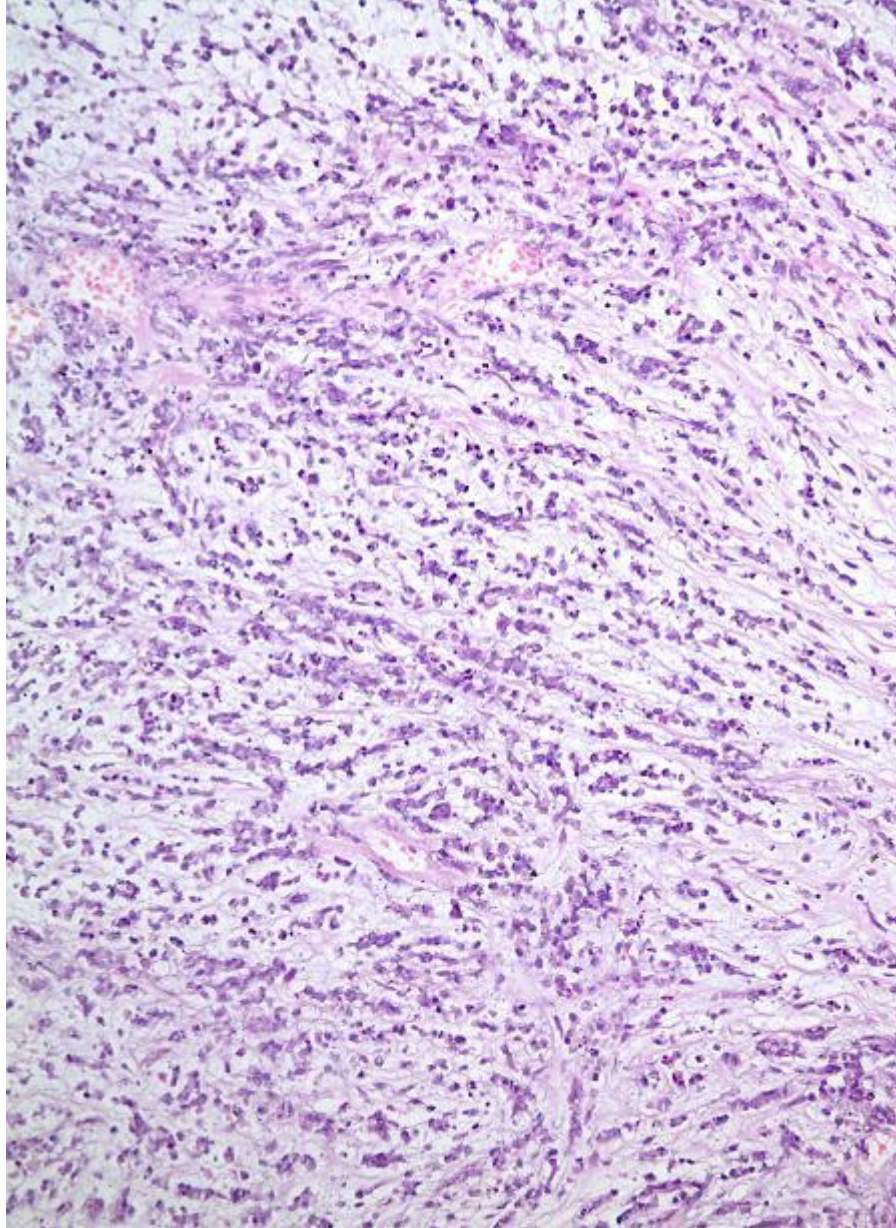


Olgu 8









TANI:
Düşük dereceli
fibromikzoid sarkom

Düşük Dereceli Fibromikzoid Sarkom

İnciler

Klinik

- Genç erişkin
- Uyluk, omuz (Barsak ve mesane gibi bölgelerde de olabilir *)

Morfoloji

- Alterne fibröz ve mikzoid zeminde girdaplaşan ve dalgalanan fasiküller
- Mitoz veya nekroz Ø
- Dev hyalinize rozetler ⇒ Dev Rozetli Hyalinize İğsi Hücreli Tümör
- Epitelioid alanlar ⇒ Sklerozan Epitelioid Fibrosarkom
- MUC4+ **
- FUS-CREB3L2 ve FUS-CREB3L1 translokasyonları

*Laurini JA et al Am J Surg Pathol. 2011;35:1069-73.

** Doyle LA et al Am J Surg Pathol. 2011; 35(5):733-41

Düşük Dereceli Fibromikzoid Sarkom

DDx

- **Nörofibrom**
- **Perinörom**
- **Desmoid fibromatozis**
- **MPNST**
- **Mikzofibrosarkom**
- **Mikzoid DFSP**

